

Mitral Valve Prolapse

Grzegorz Rozmus, MD

Jaroslav J. Fedorowski, MD, PhD, FACP

Mitral valve prolapse (MVP), first described nearly 50 years ago,¹⁻³ consists of the displacement of an abnormally thickened, redundant mitral leaflet into the left atrium during systole.⁴ Initially named *Barlow's syndrome*, it also been called *billowing mitral cusp syndrome*, *floppy valve syndrome*, *systolic click-murmur syndrome*, and *myxomatous mitral valve*. Since the first description was published in 1963, much has been learned about its underlying pathology, natural history, and possible complications, such as bacterial endocarditis, severe mitral regurgitation, and sudden cardiac death.⁵ Development of echocardiography has provided an ideal tool for studying this valvular abnormality and understanding its 3-dimensional structure.^{6,7} Results of randomized studies have provided evidence for appropriate medical and surgical interventions.

This article discusses the most common manifestations of MVP, provides a condensed review of current pathophysiologic concepts, and reviews guidelines for diagnostic evaluation and further management.

DEFINITION

MVP is defined as abnormal systolic displacement of the mitral valve leaflets superiorly and posteriorly from the left ventricle into the left atrium. This may occur because of various pathogenic mechanisms causing abnormal or relative enlargement of 1 or more portions of the mitral valve apparatus, including the mitral leaflets, chordae tendineae, papillary muscle, and valvular annulus (**Figure 1**). MVP is divided into classic and nonclassic forms based on leaflet thickness. Prolapsing valves with leaflets more than 5 mm thick are considered to the classic form, whereas those with leaflets less than 5 mm thick are considered to be the nonclassic form.⁸

PREVALENCE

MVP is the most common valvular heart disorder in industrialized countries, with prevalence estimates generally ranging from 3% to 5%.⁹⁻¹¹ The latest analyses done on the offspring cohort of the Framingham Heart Study showed the prevalence of MVP to be 2.4% (1.3% for classic MVP and 1.1% for nonclassic),⁹ which is lower than previously reported. There was no signifi-

cant difference in the percentage of women with MVP compared with men.

ETIOLOGY

The majority cases of MVP occur as a primary condition.⁵ Primary MVP is transferred from affected parents to children of either gender, indicating autosomal dominant inheritance. MVP may appear secondary to either other heritable connective tissue diseases that increase size of the mitral leaflets and apparatus, including Marfan's syndrome,¹² Ehlers-Danlos syndrome,¹³ osteogenesis imperfecta, pseudoxanthoma elasticum,¹⁴ and periarteritis nodosa, or hyperthyroidism¹⁵ and congenital malformations such as ostium secundum and Ebstein's anomaly. Asthenic body habitus predisposes to MVP, probably because the left ventricle is small in relation to the mitral valve apparatus.

Microscopic analysis of the leaflets of mitral valves with prolapse shows myxomatous proliferation of the spongiosa—the middle layer composed of loose myxomatous material. Histologic examination usually reveals enlarged myxoid stroma, redundancy of leaflets with regions of epithelial disruption,¹⁶ possible foci for thrombus formation, or endocarditis.

CLINICAL MANIFESTATIONS

Comparison of patients with MVP with unaffected relatives in family studies has documented the association of MVP with several extracardiac features (**Table 1**).¹⁷ The majority of patients with MVP are asymptomatic.¹⁸ Some may experience palpitations or atypical chest pain. In patients with severe mitral regurgitation, dyspnea or other symptoms of diminished cardiac reserve may occur.

The notion of a distinct MVP syndrome consisting of chest pain, dyspnea, and panic attacks was not confirmed by controlled studies.^{19,20} In controlled studies, palpitations were the only symptom definitely linked to MVP.¹¹

Dr. Rozmus is a Cardiology Fellow, Advocate Illinois Masonic Medical Center, Chicago, IL. Dr. Fedorowski is an Assistant Professor of Medicine, University of Vermont, and Chairman, Department of Medicine, CVPH Medical Center, Plattsburgh, NY.

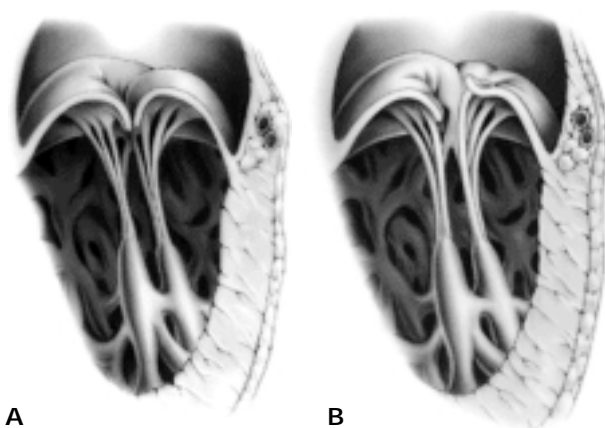


Figure 1. Anatomy of mitral valve prolapse. (A) Normal closed mitral valve; both leaflets closed. (B) Prolapsed mitral valve; one leaflet does not close properly. Reprinted with permission from Your mitral valve prolapse. Copyright © 2001 the American Heart Association.

Another symptom weakly associated with MVP is syncope or presyncope caused by orthostatic hypotension.²¹

DIAGNOSTIC EVALUATION

Cardiac Auscultation

Auscultation should be performed with the diaphragm of the stethoscope in the supine, left decubitus, and sitting positions. The classical auscultatory features of MVP are a midsystolic click followed by a mid to late systolic murmur. The click results from the sudden tensing of the mitral valve apparatus as the leaflets prolapse into the left atrium during systole. A medium to high-pitched murmur that is loudest at the apex represents turbulence of regurgitant flow. These findings (the murmur and click) are very sensitive to physiologic and pharmacologic interventions. Maneuvers that reduce left ventricle size (eg, the straining phase of the Valsalva maneuver, sudden standing, inhalation of amyl nitrite) result in the earlier occurrence of prolapse and, therefore, the earlier appearance of the click and murmur. In contrast, increased left ventricle volume (eg, caused by a sudden change from a standing to a supine position, leg raising, squatting, or isometric exercise) delays onset of the click and murmur. When the onset of murmur is delayed, its duration and intensity are diminished, reflecting a lesser degree of mitral regurgitation.²²

Echocardiography

Echocardiography is the gold standard test for diagnosing MVP. Generally, only patients with physical findings or a positive family history for MVP should under-

Table 1. Extracardiac Features Associated with Mitral Valve Prolapse

Feature	Incidence Among Patients with Mitral Valve Prolapse
Thoracic bony abnormalities (pectus excavatum, mild scoliosis, straight thoracic spine)	41%
Body weight below 10th percentile	32%
Systolic blood pressure < 120 mm Hg	53%

Data from Devereux.¹⁷

go echocardiography.²³ **Table 2** summarizes current indications for echocardiographic evaluation in patients with suspected MVP.

There is no consensus regarding echocardiographic criteria for diagnosing MVP. No single view should be considered diagnostic. **Table 3** summarizes the echocardiographic features of MVP. The likelihood of MVP increases as more of these features are present in a patient.

On M-mode echocardiography, MVP is typically marked by a 2-mm or greater posterior displacement of one or both leaflets. On 2-dimensional echocardiography, systolic displacement of one or both mitral leaflets in the parasternal long axis view, especially when they coapt on the atrial side of the annular plane, indicates a high likelihood of MVP.

The reliability of diagnosis of MVP when seen only on the apical 4-chamber view is questionable. Also, the diagnosis of MVP is stronger when leaflet thickness is greater than 5 mm. Leaflet redundancy is often associated with an enlarged mitral annulus and elongated chordae tendineae. The presence or absence of mitral regurgitation is an important factor, and MVP is more likely when mitral regurgitation is detected (on Doppler echocardiography) as a high-velocity eccentric jet during late systole.²⁴

Electrocardiography

The electrocardiogram is usually normal in asymptomatic patients with MVP. Some may have inverted or biphasic T waves and nonspecific ST-T changes in leads II, III, and aVF.²⁵

COMPLICATIONS

The prognosis of children with MVP is excellent; the majority remain asymptomatic for years.¹⁷ However, a minority of patients with MVP develop severe mitral

Table 2. Indications for Echocardiography in Patients with Mitral Valve Prolapse

Assessment of hemodynamic severity of mitral regurgitation, leaflet morphology, and ventricular compensation in patients with physical signs of MVP

To exclude MVP in patients who have been given the diagnosis when the clinical evidence to support the diagnosis is questionable

To exclude MVP in patients with first-degree relatives with known myxomatous valve disease

Risk stratification in patients with known MVP or with physical findings of MVP

MVP = mitral valve prolapse.

Data from Cheitlin et al.²³

regurgitation, infective endocarditis, cerebral ischemia, or sudden death. Overall, the risk for morbid or mortal complications in patients with MVP is 1% per year.²⁶ In some patients, after a prolonged asymptomatic period, the entire disease process enters an accelerated phase because of left atrial and left ventricular enlargement, atrial fibrillation, or rupture of the chordae tendineae. MVP contributes to approximately 4000 mitral valve surgeries and 1200 cases of infective endocarditis in the United States annually.⁵

Mitral Regurgitation

Progressive mitral regurgitation is the most common serious complication of MVP.^{26,27} Severe regurgitation should be suspected in the presence of a holosystolic murmur associated with a third heart sound and dynamic left ventricular impulse; in 75% of cases, it is caused by chordal rupture.²⁸ Echocardiography with color Doppler usually shows a large regurgitant jet, left ventricular and left aortic enlargement, and a varying spectrum of valvular apparatus abnormalities.

The cumulative risk for mitral valve surgery is age and gender dependent. Men and women younger than 50 years are at minimal risk. However, after age 50 years, risk rises sharply and is highest in elderly men. By age 75 years, approximately 1.5% to 2% of women and 5.5% of men with MVP develop mitral regurgitation requiring surgical repair.^{27,29}

Bacterial Endocarditis

The overall incidence of endocarditis in patients with MVP is low and reported to be 0.1/100 subject-years.²⁷ The incidence increases in patients with systolic murmur. In patients older than 45 years, the incidence is 3 times higher in men than in women.³⁰

Table 3. Echocardiographic Features Characteristic of Mitral Valve Prolapse

M-mode echocardiography

2-mm posterior displacement of 1 or both leaflets

2-Dimensional echocardiography

Systolic displacement of 1 or both mitral leaflets, especially when they coapt on the atrial side of the annular plane

Leaflet thickness > 5 mm with an enlarged mitral annulus and elongated chordae tendineae

Doppler echocardiography

Presence of mitral regurgitation (indicated by high-velocity eccentric jet during late systole)

NOTE: The presence of more of these features indicates a greater likelihood of mitral valve prolapse.

The risk of bacterial endocarditis in patients with MVP is increased not because of the abnormal valve motion but because of the jet caused by leakage resulting from the mitral insufficiency, which creates shear forces, flow abnormalities, and endothelial damage. Therefore, antibiotic prophylaxis against bacterial endocarditis is not necessary when mitral valve prolapse occurs without valve regurgitation.

Approximately one third of cases of bacterial endocarditis in patients with MVP are preceded by dental procedures.³⁰ **Table 4** outlines American Heart Association recommendations for antibiotic prophylaxis in patients with MVP.³¹ Recommended prophylactic regimens are summarized in **Table 5**.³¹

Cerebral Ischemia

It is speculated that loss of endothelial continuity and tearing of the endocardium overlying the myxomatous valve may trigger platelet adhesion/aggregation process and the formation of mural thrombi, which later may become emboli. The overall risk for cerebral ischemia in patients with MVP is low and is estimated to be 0.3/100 subject-years.²⁷ Other authors reported a 2-fold increased risk of stroke in patients with MVP in comparison to a reference population. In this report, the increase was related to sequelae of MVP, including congestive heart failure, atrial fibrillation, and mitral valve replacement.³²

Antiplatelet and anticoagulation therapy are recommended for stroke prevention in patients with atrial fibrillation or a history of previous ischemic events and in patients with high-risk (ie, classic) MVP in normal sinus rhythm (**Table 6**). Daily aspirin therapy (80–325 mg/d) is recommended for patients with MVP

Table 4. American Heart Association Recommendations for Antibiotic Endocarditis Prophylaxis for Patients with Mitral Valve Prolapse Undergoing Procedures with Risk of Bacteremia

Presence of characteristic systolic click-murmur complex
 Presence of isolated click and echocardiographic evidence of MVP and mitral regurgitation
 Presence of isolated click and evidence of high-risk MVP (ie, myxomatous degeneration, left atrial enlargement, left ventricular dilatation)

MVP = mitral valve prolapse.

Data from Dajani et al.³¹

Table 5. Endocarditis Prophylactic Regimens for Dental, Oral, Respiratory Tract, and Esophageal Procedures

Standard prophylaxis:

Amoxicillin 2.0 g orally 1 h before procedure

For patients on NPO status:

Ampicillin 2.0 gm g IM or IV 30 min before procedure

For patients allergic to penicillin: any one of the following:

Clindamycin 600 mg orally 1 h before procedure

Cefadroxil 2.0 g orally 1 h before procedure

Cefalexin 2.0 g orally 1 h before procedure

Azithromycin 500 mg orally 1 h before procedure

Clarithromycin 500 mg orally 1 h before procedure

For patients on NPO status and allergic to penicillin: either of the following:

Clindamycin 600 mg IV 30 min before procedure

Cefazolin 1 g IM or IV 30 min before procedure

IM = intramuscularly; IV = intravenously; NPO = nothing by mouth.

Data from Dajani et al.³¹

and documented focal neurologic events who are in normal sinus rhythm with no atrial thrombi.³³ These patients should avoid smoking and taking oral contraceptives. Warfarin is indicated in patients with MVP and a history of stroke or recurrent transient ischemic attack not responding to aspirin and in those older than 65 years with atrial fibrillation. The international normalized ratio goal for warfarin therapy is 2.0 to 3.0.

Sudden Cardiac Death

Patients with MVP have an increased risk for ventricular and supraventricular arrhythmias. More than 50%

Table 6. American College of Cardiology/American Heart Association Recommendations for Antiplatelet and Oral Anticoagulation Therapy in Patients with Mitral Valve Prolapse

Aspirin therapy is indicated for:

Patients with a history of recurrent cerebral transient ischemic attack

Patients younger than 65 years with atrial fibrillation and no history of hypertension, mitral regurgitation, or congestive heart failure

Poststroke patients with contraindications to warfarin

Patients in normal sinus rhythm with echocardiographic evidence of high-risk mitral valve prolapse

Warfarin therapy is indicated for:

Patients older than 65 years with atrial fibrillation and with hypertension, mitral regurgitation, or congestive heart failure

Poststroke patients

Patients with recurrent cerebral transient ischemic attack despite aspirin therapy

Data from Bonow et al.³³

of patients with MVP have premature ventricular complexes associated with complex ventricular arrhythmias.³⁴ Sudden cardiac death is a rare condition, with an estimated occurrence of 0.2% to 1.4% of patients with MVP.^{27,35} The exact mechanism of ventricular arrhythmias in patients with MVP is not clearly understood. One theory blames voluminous prolapsing leaflets producing tension to papillary muscles and stimulating ectopy.^{32,35} Another suggests that thickened chordae mechanically irritate the endocardium, causing repolarization changes.³⁶ Prolongation of QT interval, QT dispersion, and repolarization abnormalities also have been proposed as possible mechanisms of ventricular fibrillation.³⁴

A family history of sudden cardiac death is a significant risk factor because of inherited diseases such as prolonged QT syndrome.³⁵ In addition, myocardial ischemia caused by dysplasia of the small arteries (more prevalent in patients with MVP) can contribute to sudden cardiac death mediated by ventricular fibrosis.³⁷

MANAGEMENT

Most patients with MVP need reassurance based on the low overall incidence of complications (approximately 1% per year).²⁷ Increased severity of mitral regurgitation is associated with an increased risk for serious sequelae, including progressive valve dysfunction

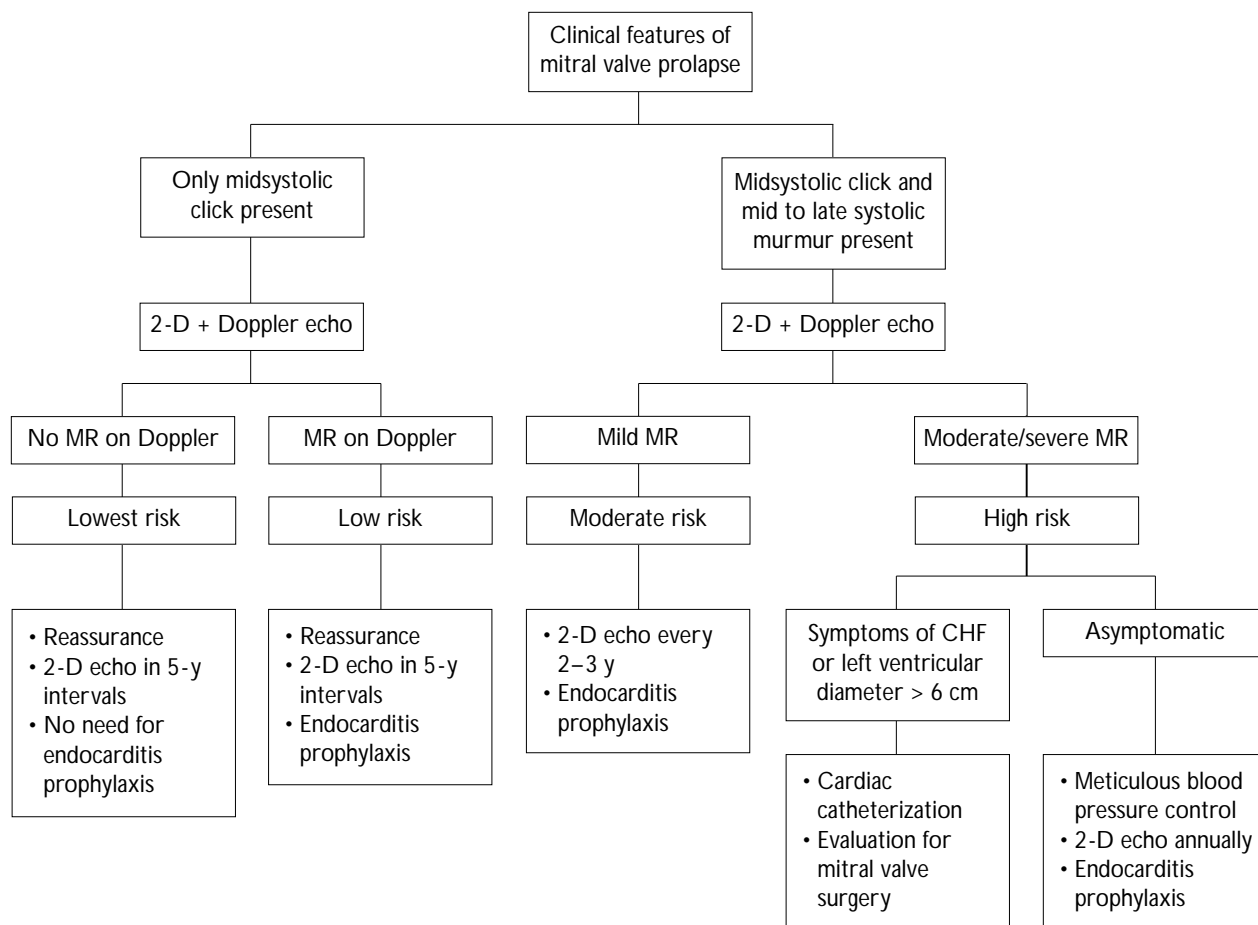


Figure 2. Algorithm for the evaluation and surveillance of mitral valve prolapse. CHF = congestive heart failure; 2-D = 2-dimensional; echo = echocardiography; MR = mitral regurgitation. Data from Devereux.¹⁷

requiring replacement, infective endocarditis, and sudden death.³⁸ Therefore, the degree of mitral regurgitation provides the most reliable guide to the need for active treatment and more frequent follow-up (Figure 2).¹⁷ Recommendations for preventive treatment for bacterial endocarditis and stroke are summarized in Tables 5 and 6.

Patients with MVP and palpitations (caused by arrhythmias or increased adrenergic tone) frequently benefit from cessation of such stimulants as smoking, alcohol, or caffeine. In addition, treatment with β -blockers is effective in reducing chest pain and palpitations. In patients with recurrent palpitations, unexplained syncope, or episodes of nonsustained ventricular tachycardia, further investigations should be performed, including an exercise stress test, 24-hour Holter monitoring, or event monitoring. Indications for electrophysiologic testing are the same as for the general population.

Surgical correction should be considered in cases of severe mitral regurgitation, particularly for those who develop flail leaflet because of chordae rupture or significant elongation. Valve replacement has excellent long-term results but is associated with life-long anticoagulation with warfarin. Myxomatous degeneration of mitral valve apparatus often can be repaired by performing annuloplasty and flexible ring placement, with low operative mortality. Long-term follow-up of patients undergoing mitral repair showed 88% patients free from recurrent mitral insufficiency 10 years after surgery.³⁹

CONCLUSION

Applying current criteria, a community-based sample of patients showed the prevalence of MVP to be approximately 2.4%.⁹ Echocardiography is the gold standard for diagnosing MVP, but only patients with abnormal findings on auscultation or a family history of myxomatous valve degeneration should be referred

for echocardiography. Mitral regurgitation, bacterial endocarditis, cerebral ischemia, and sudden cardiac death are potential complications of this syndrome, with an overall prevalence of 1%. The most important role of the primary physician in the management of patients with MVP is to reassure those with low-risk MVP and identify those who may suffer from complications and initiate actions to prevent them. **HP**

REFERENCES

1. Barlow JB, Pocock WA, Marchand P, Denny M. The significance of late systolic murmurs. *Am Heart J* 1963;66:443–52.
2. Criley JM, Lewis KB, Humphries JO, Ross RS. Prolapse of the mitral valve: clinical and cine-angiocardigraphic findings. *Br Heart J* 1966;28:488–96.
3. Kerber AE, Isaef DM, Hancock EW. Echocardiographic patterns in patients with the syndrome of systolic click and late systolic murmur. *N Engl J Med* 1971;284:691–3.
4. Devereux RB, Kramer-Fox R, Shear MK, et al. Diagnosis and classification of severity of mitral valve prolapse: methodologic, biologic, and prognostic considerations. *Am Heart J* 1987;113:1265–80.
5. Devereux RB, Kramer-Fox R, Kligfield P. Mitral valve prolapse: causes, clinical manifestations and management. *Ann Intern Med* 1989;111:305–17.
6. Levine RA, Triulzi MO, Harrigan P, Weyman AE, et al. The relationship of mitral annular shape to the diagnosis of mitral valve prolapse. *Circulation* 1987;75:756–67.
7. Levine RA, Stathogiannis E, Newell JB, et al. Reconsideration of echocardiographic standards for mitral valve prolapse: lack of association between leaflet displacement isolated to the apical four chamber view and independent echocardiographic evidence of abnormality. *J Am Coll Cardiol* 1988;11:1010–9.
8. Marks AR, Choong CY, Sanfilippo AJ, et al. Identification of high-risk and low-risk subgroups of patients with mitral valve prolapse. *N Engl J Med* 1989;320:1031–6.
9. Freed LA, Levy D, Levine RA, et al. Prevalence and clinical outcome of mitral-valve prolapse. *N Engl J Med* 1999;341:1–7.
10. Levy D, Savage D. Prevalence and clinical features of mitral valve prolapse. *Am Heart J* 1987;113:1281–90.
11. Savage DD, Levy D, Garrison RJ, et al. Mitral valve prolapse in the general population. 3. Dysrhythmias: the Framingham Study. *Am Heart J* 1983;106:577–6.
12. Pini R, Roman MJ, Kramer-Fox R, Devereux RB, et al. Mitral valve dimensions and motions in Marfan patients with and without mitral valve prolapse. Comparison to primary mitral valve prolapse and normal subjects. *Circulation* 1989;80:915–24.
13. Leier CV, Call TD, Fulkerson PK, Wooley CF, et al. The spectrum of cardiac defects in the Ehlers-Danlos syndrome and III. *Ann Intern Med* 1980;92:171–8.
14. Lebowitz MG, Distefano D, Prioleau PG, et al. Pseudo-xanthoma elasticum and mitral-valve prolapse. *N Engl J Med* 1982;307:228–31.
15. Noah MS, Sulimani RA, Famuyiwa FO, et al. Prolapse of the mitral valve in hyperthyroid patients in Saudi Arabia. *Int J Cardiol* 1988;19:217–23.
16. Davies MJ, Moore BP, Braimbridge MV, et al. The floppy mitral valve. Study of incidence, pathology, and complications in surgical, necropsy, and forensic material. *Br Heart J* 1978;40:468–81.
17. Devereux RB. Recent developments in the diagnosis and management of mitral valve prolapse. *Curr Opin Cardiol* 1995;10:107–16.
18. Bodoulas H, Kolibash AJ Jr, Baker P, et al. Mitral valve prolapse and the mitral valve prolapse syndrome: a diagnostic classification and pathogenesis of symptoms. *Am Heart J* 1989;118:796–818.
19. Uretsky BF. Does mitral valve prolapse cause nonspecific symptoms? *Int J Cardiol* 1982;1:435–42.
20. Rueda B, Arvan S. The relationship between clinical and echocardiographic findings in mitral valve prolapse. *Herz* 1988;13:277–83.
21. Gaffney FA, Bastian BC, Lane LB, et al. Abnormal cardiovascular regulation in the mitral valve prolapse syndrome. *Am J Cardiol* 1983;52:316–20.
22. Devereux RB, Perloff JK, Reichek N, et al. Mitral valve prolapse. *Circulation* 1976;54:3–14.
23. Chaitlin MD, Alpert JS, Armstrong WF, et al. ACC/AHA Guidelines for the Clinical Application of Echocardiography. A report of the American College of Cardiology/American Heart Association Task Force on Practice Guidelines (Committee on Clinical Application of Echocardiography). Developed in collaboration with the American Society of Echocardiography. *Circulation* 1997;95:1686–744.
24. Bonow RO, Carabello B, de Leon AC, et al. Guidelines for the management of patients with valvular heart disease: executive summary. A report of the American College of Cardiology/American Heart Association Task Force on Practice Guidelines (Committee on Management of Patients with Valvular Heart Disease). *Circulation* 1998;98:1949–84.
25. Gaash WH, Aurigemma GP. Is corrective surgery ever indicated in asymptomatic patients with mitral regurgitation? *Cardiol Rev* 1994;2:138.
26. Zuppiroli A, Rinaldi M, Kramer-Fox R, et al. Natural history of mitral valve prolapse. *Am J Cardiol* 1995;75:1028–32.
27. Singh RG, Capucci R. Mitral valve prolapse and risk factors for severe mitral regurgitation. *J Am Coll Cardiol* 1993;1:242A.
28. Naggar CZ, Pearson WN, Seljan MP. Frequency of complications of mitral valve prolapse in subjects aged 60 years or older. *Am J Cardiol* 1986;58:1209–12.
29. Wilcken DE, Hickey AJ. Lifetime risk for patients with mitral valve prolapse of developing severe valve regurgitation requiring surgery. *Circulation* 1988;78:10–4.
30. MacMahon SW, Roberts JK, Kramer-Fox R, et al. Mitral valve prolapse and infective endocarditis. *Am Heart J* 1987;113:1291–8.

(continued on page 68)

(from page 60)

31. Dajani AS, Taubert KA, Wilson W, et al. Prevention of bacterial endocarditis. Recommendations by the American Heart Association. *Circulation* 1997;96:358–66.
32. Orenca AJ, Petty GW, Khanderia BK, et al. Risk of stroke with mitral valve prolapse in population-based cohort study. *Stroke* 1995;26:7–13.
33. Bonow RO, Carabello B, de Leon AC, et al. ACC/AHA Guidelines for the Management of Patients With Valvular Heart Disease. Executive summary. A report of the American College of Cardiology/American Heart Association Task Force on Practice Guidelines (Committee on Management of Patients With Valvular Heart Disease). *J Heart Valve Dis* 1998;7:672–707.
34. Kulan K, Komsuoglu B, Tuncer C, Kulan C. Significance of QT dispersion on ventricular arrhythmias in mitral valve prolapse. *Int J Cardiol* 1996;54:251–7.
35. Levy S. Arrhythmias in mitral valve prolapse syndrome: clinical significance and management. *Pacing Clin Electrophysiol* 1992;15:1080–8.
36. Chesler E, King RA, Edwards JE. The myxomatous mitral valve and sudden death. *Circulation* 1983;67:632–9.
37. Burke AP, Farb A, Tang A, et al. Fibromuscular dysplasia of small coronary arteries and fibrosis in the basilar ventricular septum in mitral valve prolapse. *Am Heart J* 1997;134:282–91.
38. Duren DR, Becker AE, Dunning AJ. Long term follow-up of idiopathic mitral valve prolapse in 300 patients; a prospective study. *J Am Coll Cardiol* 1988;11:42–7.
39. Spencer FC, Galloway AC, Grossi EA, et al. Recent developments and evolving techniques of mitral valve reconstruction. *Ann Thorac Surg* 1998;65:307–13.

Copyright 2002 by Turner White Communications Inc., Wayne, PA. All rights reserved.