

Letters to the Editor

UPDATED CANCER STAGING SYSTEM

To the Editor:

As chief residents in urology, we were especially interested in the article, "Small Cell Carcinoma of the Bladder" (Kayler LK, Caruso DM, Matthews MR, deGuzman J: *Hospital Physician* 1999;35:[7]:60–63,66). We wanted to point out that the bladder cancer staging

system has changed as of 1997. T3a cancer is now grouped with T2, T3bi is now T3a, and T3bii is now T3b. The current staging system is shown in **Table 1** and **Figure 1**.

Michael A. Sanford, MD
Stanley Zaslau, MD
The Mount Sinai Medical Center
New York, NY

Table 1. UICC/TNM Classification for Bladder Cancer

Rules for classification: The classification applies only to carcinomas. Papilloma is excluded. There should be histological or cytological confirmation of the disease. The following are the procedures for assessing T, N, and M categories: T categories—physical examination, imaging, and endoscopy; N categories—physical examination and imaging; and M categories—physical examination and imaging.

Regional lymph nodes: The regional lymph nodes are the nodes of the true pelvis, which essentially are the pelvic nodes below the bifurcation of the common iliac arteries. Laterality does not affect the N classification.

TNM Clinical Classification

Primary tumor (T)

The suffix (m) should be added to the appropriate T category to indicate multiple tumors. The suffix(s) may be added to any T to indicate presence of associated carcinoma in situ.

TX	Primary tumor cannot be assessed
T0	No evidence of primary tumor
Ta	Noninvasive papillary carcinoma
Tis	Carcinoma in situ; "flat tumor"
T1	Tumor invades subepithelial connective tissue
T2	Tumor invades muscle
T2a	Tumor invades superficial muscle (inner half)
T2b	Tumor invades deep muscle (outer half)
T3	Tumor invades perivesical tissue
T3a	Tumor invades perivesical tissue microscopically
T3b	Tumor invades perivesical tissue macroscopically (extravesical mass)
T4	Tumor invades any of the following: prostate, uterus, vagina, pelvic wall, abdominal wall
T4a	Tumor invades prostate or uterus or vagina
T4b	Tumor invades pelvic wall or abdominal wall

Regional lymph nodes (N)

NX	Regional lymph nodes cannot be assessed
N0	No regional lymph node metastasis
N1	Metastasis in a single lymph node 2 cm or less in greatest dimension
N2	Metastasis in a single lymph node more than 2 cm but not more than 5 cm in greatest dimension, or multiple lymph nodes, none more than 5 cm in greatest dimension
N3	Metastasis in a lymph node more than 5 cm in greatest dimension

Distant metastasis (M)

MX	Presence of distant metastasis cannot be assessed
M0	No distant metastasis
M1	Distant metastasis

Adapted with permission from Sobin LH, Wittekind C: *TNM Classification of Malignant Tumours*, 5th ed. New York: John Wiley & Sons, 1997.

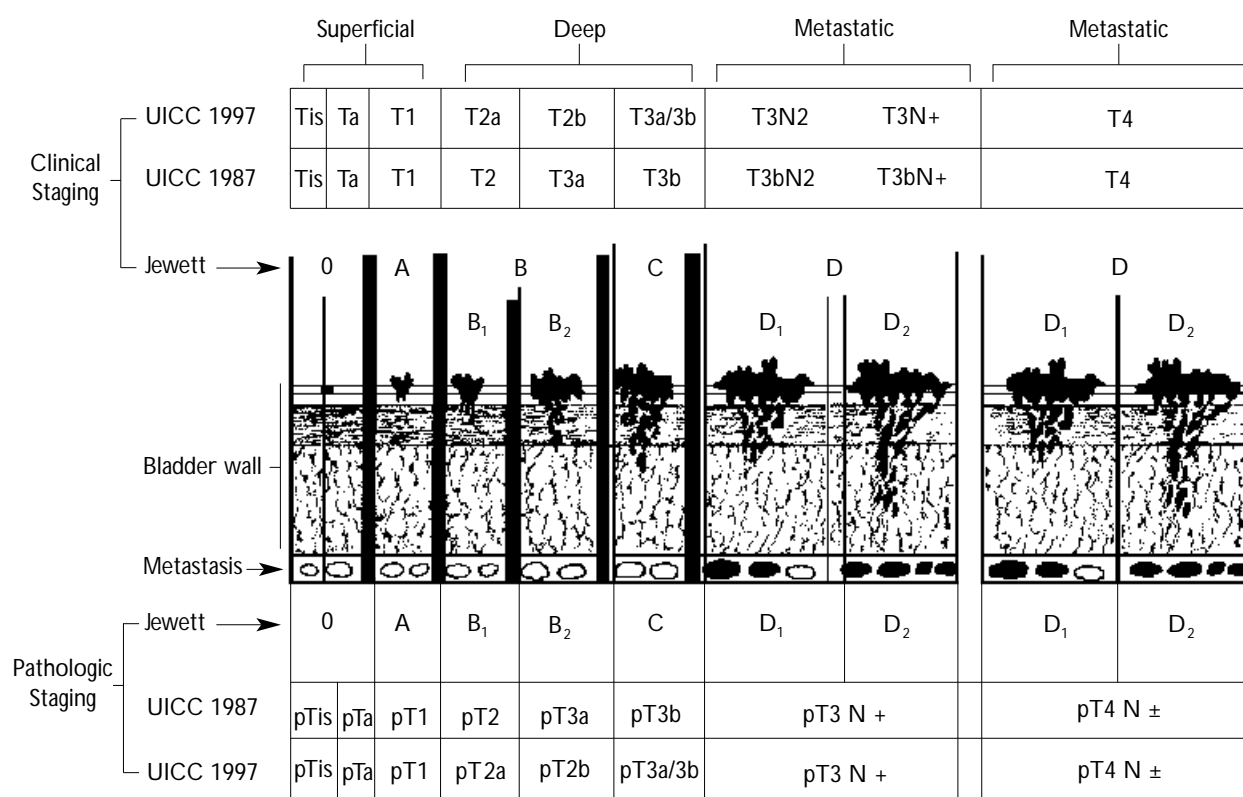


Figure 1. Staging systems for bladder cancer are based on correlations between the layer to which a particular cancer has penetrated the bladder wall and the prognosis of that type of cancer. The original staging system (developed by Jewett in 1946) suggested distinctions between superficial and muscle-invasive disease. The superficial classification was subsequently divided into tumors confined to the mucosa (stage Ta) and tumors that penetrate the lamina propria (stage T1). Carcinoma in situ (stage Tis) is a superficial disease composed of neoplastic cells that replace the normal urothelium or undermine the normal urothelium and extend along the plane of the urothelium. Deep bladder tumors penetrate the muscularis propria either superficially (stage T2a) or deeply (stage T2b) or penetrate through the muscularis propria into the perivesical soft tissue either microscopically (stage T3a) or extensively (stage T3b). These distinctions are a recent change in the World Health Organization classification system, which now combines all muscle-invasive tumors into one category (stage 2) rather than maintaining the separation that formerly had characterized the staging system (stage T2 for superficial invasion and stage T3a for deep muscle invasion). The involvement of lymph nodes is designated by the N category, and involvement of adjacent structures is categorized as stage T4. This format implies a simple pattern of sequential development according to which early cancers appear as lower stages, then progress to higher stages in sequence. However, this progression is not necessarily what characterizes the different forms of bladder cancer seen clinically. Rather, a variety of pathways that do not necessarily occur in sequence but that are possibly interrelated may more accurately reflect the biology of the different forms of bladder cancer. Figure 1 is adapted with permission from Koss LG: Tumors of the urinary bladder. In *Atlas of Tumor Pathology*, 2nd series, fascicle 11. Washington, DC: Armed Forces Institute of Pathology, 1974. Figure 1 legend is adapted with permission from Droller MJ: Bladder cancer: state-of-the-art care. *CA Cancer J Clin* 1998;48:269-284.

Copyright 1999 by Turner White Communications Inc., Wayne, PA. All rights reserved.