

Cryptogenic Stroke in Patients with Patent Foramen Ovale

Carlos E. Sanchez, MD, Joo A. Lee, MD, Geoffrey Eubank, MD, and Steven J. Yakubov, MD

Abstract

- **Objective:** To discuss what is known regarding patent foramen ovale (PFO) and cryptogenic stroke and options for secondary stroke prevention.
- **Methods:** Review of the literature.
- **Results:** Observational studies have suggested a strong association between PFO and cryptogenic stroke. Optimal therapy for prevention of recurrent stroke in patients with cryptogenic stroke and PFO has not been defined. Treatment options include medical therapy with antiplatelet agents or warfarin, percutaneous device closure, or open surgical repair. Current guidelines recommend antiplatelet therapy for patients with ischemic stroke or transient ischemic attack and PFO. Percutaneous closure has largely replaced surgical repair. Case series of percutaneous PFO closure have shown risk reduction of stroke recurrence. Randomized clinical trials comparing percutaneous PFO closure and medical management are underway.
- **Conclusion:** Cryptogenic stroke is a subset of ischemic stroke and a diagnosis of exclusion. There is a high prevalence of PFOs in patients with cryptogenic strokes. Current guidelines recommend medical treatment; ongoing trials of percutaneous PFO closure versus medical therapy may provide the answers for determining the best treatment strategy.

Case Presentation

A 30-year-old man with no past medical history is brought to the emergency department after being found unresponsive at home. On examination, his vital signs are stable but he is lethargic without any purposeful movements. There is no facial asymmetry or focal neurologic deficit. The patient demonstrates minimal but symmetrical withdrawal to deep painful stimuli. Deep tendon reflexes are 1 out of 4 throughout. A blood glucose level, urine toxicology screen, and results from lumbar puncture are normal. Computed tomography (CT) of the head is normal; however, magnetic resonance

imaging (MRI) of the brain demonstrates bilateral thalamic ischemic infarcts as well as an ischemic infarct in the left cerebellar hemisphere. Further studies are ordered since the etiology of the stroke is unclear. Magnetic resonance angiography of the brain and neck shows no abnormalities. A transesophageal echocardiogram (TEE) shows no source of cardiac emboli; however, a patent foramen ovale with bidirectional shunting and an atrial septal aneurysm are visualized.

Stroke is the third leading cause of death in the United States, with 795,000 people experiencing a new or recurrent stroke each year. Eighty-seven percent of strokes are ischemic [1]. The majority of ischemic strokes occur in persons older than 65 years of age following the development of atherosclerosis, particularly in the neck and brain vasculature. A minority of ischemic strokes occur in younger adults (< 55 years old), and the etiology is undetermined, or cryptogenic, in 30% to 40% of these cases despite an extensive evaluation [2,3].

A strong association exists between the finding of a patent foramen ovale (PFO) and cryptogenic strokes in young adults, with a PFO being demonstrated in more than 50% of the cases [4]. Between 50,000 to 100,000 patients in the United States present each year with PFO and cryptogenic stroke [5]. This paper will review current data about PFO and cryptogenic stroke and the options for secondary stroke prevention.

Anatomy And Pathophysiology

Patent Foramen Ovale

A PFO is a flap valve formed from the incomplete closure of the septa primum and secundum (Figure 1) and may remain present for the first year of life. A foramen ovale in utero operates as a one-way, interatrial valve allowing right-to-left shunting of maternally oxygenated blood to bypass the pulmonary circulation and to pass directly into the

From the Riverside Methodist Hospital, Columbus, OH.

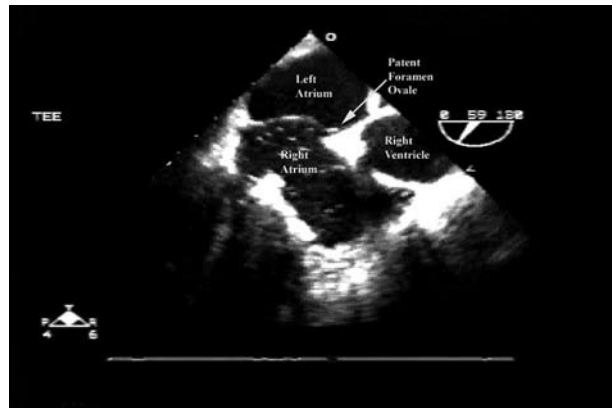
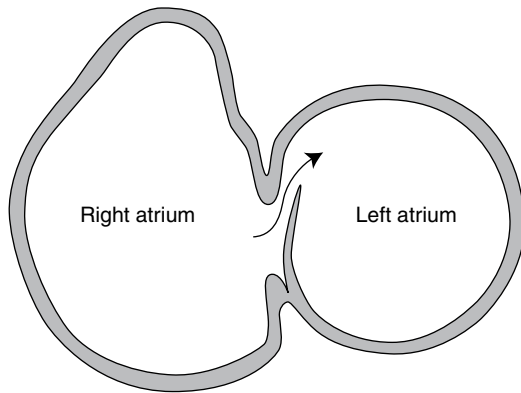


Figure 1. Schematic representation of a patent foramen ovale (*left*). Transesophageal echocardiogram (*right*) shows separation of septum primum from septum secundum that constitutes a patent foramen ovale (*arrow*).

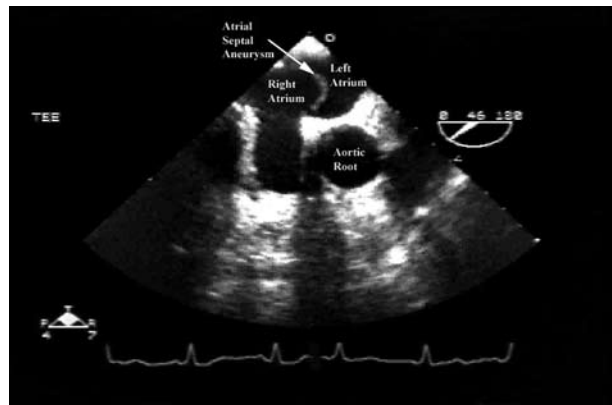
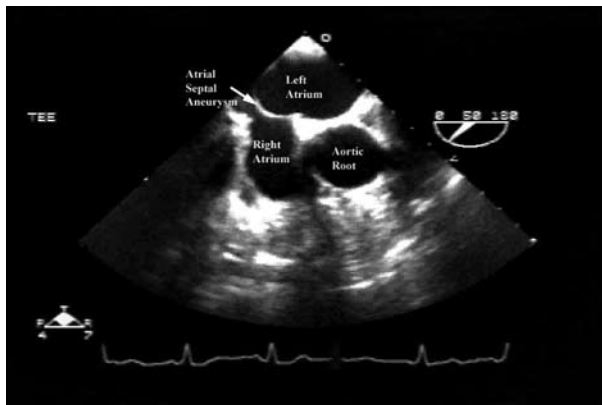


Figure 2. Transesophageal echocardiogram shows an atrial septal aneurysm (*arrow*) contracted into the right atrium (*left*) and expanded into the left atrium (*right*) during a cardiac cycle.

systemic circulation [6]. Left atrial pressure increases after birth while pulmonary pressures decrease, and usually within 3 months, the foramen ovale seals permanently. This fetal remnant fails to close in an estimated 25% to 27% of the general population, and right-to-left blood flow can occur when right atrial pressure exceeds left atrial pressure [7].

The yearly risk of first cryptogenic stroke with a PFO is estimated to be 0.1% in an otherwise healthy individual. Given the low pathogenicity of a PFO in healthy individuals, other risk factors may increase the risk of thromboembolic strokes [8]. A PFO with a concomitant hypermobile atrial septum or atrial septal aneurysm (ASA) is the strongest potentiator of stroke risk related to an atrial defect [9]. A meta-analysis showed that an ASA increased the risk of recurrent stroke in patients younger than 55 years with a PFO [10] and the combination of both was found to be a predictor of increased risk for recurrent stroke [11]. A PFO ≥ 4 mm (measured as the separation between the septa primum and secundum

[12]) increases stroke risk due to increased septal mobility and right-to-left shunting at rest [8] (Figure 1). The existence of hypercoagulable states in patients with additional risks for venous thrombosis, such as prolonged immobility and recent surgery, carries additional risk for patients with a PFO [13].

Atrial Septal Aneurysm

An ASA is defined on echocardiogram by > 10 mm excursion [7] of a hypermobile septum primum into the atrial chambers during each cardiac cycle (Figure 2). The prevalence in healthy individuals is estimated to be 0.3% to 7.9% [14]. An association between ASA and stroke has been documented, but without a clear understanding of the underlying mechanism. The association, however, may be explained in part by the high concordance (50%–90%) of existing ASA and PFO or other interatrial shunts in the setting of paradoxical embolism (PDE) [78]. The combined presence of a PFO and ASA increases the risk of ischemic stroke more

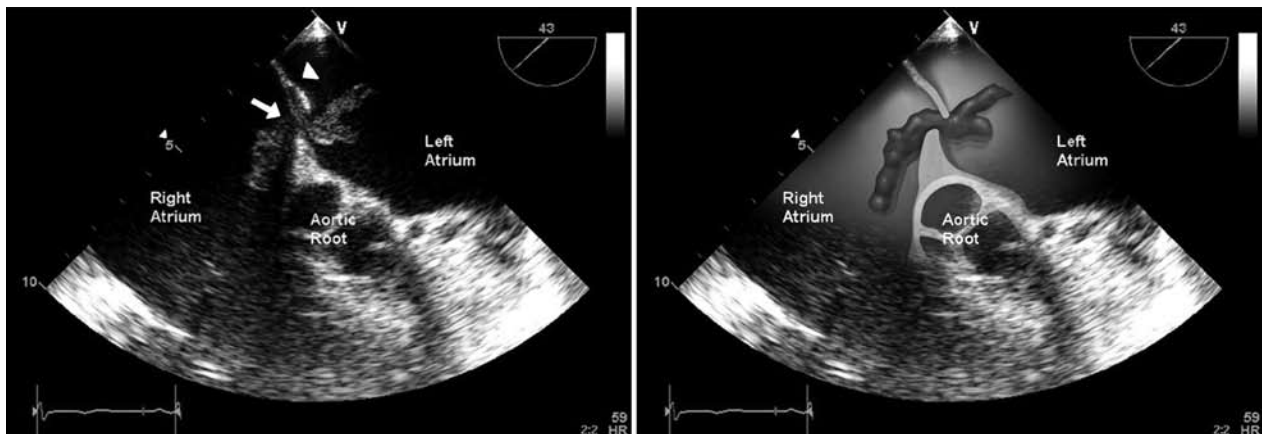


Figure 3. Transesophageal echocardiogram shows the septum primum (*arrowhead*) and a venous thrombi caught in transit across a patent foramen ovale (*arrow*). (Reprinted from reference 3 with permission from Elsevier.)

than either factor alone [10,15]. The same is true for patients with recurrent strokes on medical therapy for secondary prevention, where the risk of stroke with a PFO and ASA is higher than with either atrial septal anomaly alone [11].

Paradoxical Embolism

A PDE can occur in cryptogenic strokes when a PFO allows a venous thrombus to cross into the arterial circulation. This theory is supported by case reports of venous thrombi caught “in transit” across a PFO (**Figure 3**) in patients with stroke or systemic embolization [3]. Such thrombus-in-transit is rarely seen in patients with stroke and PFO; therefore, the clinical diagnosis of PDE is based on the presence of systemic embolization, venous thrombosis, PFO and right-to-left shunt [16]. A right-to-left shunt can be induced transiently in patients with normal atrial pressures with a Valsalva maneuver. In addition, right atrial pressures can be persistently elevated in chronic conditions such as valvular lesions or pulmonary hypertension [7].

Diagnosis

Cryptogenic Stroke

Ischemic strokes are subdivided into large-artery atherosclerosis, cardioembolism, small-artery occlusion, stroke of other determined etiology, and stroke of undetermined etiology, otherwise known as cryptogenic stroke [17]. Diagnosis of cryptogenic stroke requires excluding the other etiologies. Neuroimaging is focused on the identification of an acute thrombus or stenotic lesions within the cerebral or carotid vasculature by using appropriate combinations of CT, MRI, CT or MR angiography, and carotid or transcranial ultrasonography. Cardiac evaluation is performed with either transthoracic echocardiography (TTE) or TEE. TEE is

the preferred test for better detection of left atrial thrombus, aortic atheroma, valvular strands, PFO, and ASA [3]. Less common etiologies for stroke include vasculopathies, hypercoagulable states, or hematologic disorders. The workup for these requires a complete blood count, lipid levels, and a hypercoagulable panel (protein C and protein S, antithrombin III deficiency, factor V Leiden mutation, prothrombin G20210A mutation, antiphospholipid and anticardiolipin antibodies, and lupus anticoagulant) [17,18].

Deep vein thrombosis (DVT) of the lower extremities or pelvis has rarely been identified in patients with cryptogenic stroke and PFO. Detection of a DVT makes the diagnosis of PDE more likely. The low rates of DVT detection in the past may have been due to delays in performing imaging studies, complete thrombus migration, early initiation of anticoagulation therapy, and/or undetectable clot size (1–3 mm) [8,16]. Even in patients with pulmonary embolism (PE), a dedicated evaluation for a DVT did not uncover an underlying clot in 20% to 30% of cases [19]. The Paradoxical Emboli from Large Veins in Ischemic Stroke (PELVIS) study showed that the prevalence of pelvic DVT was significantly higher in younger patients with cryptogenic strokes than in patients with strokes of determined origin (20% vs. 4%; $P = 0.025$) using magnetic resonance venography (MRV) [20]. This finding suggests that a PDE is the cause in a subset of patients diagnosed with cryptogenic stroke and PFO [20]. Although specific guidelines do not exist, MRV of the pelvis and ultrasonography of the legs allow for a more complete evaluation for PDE and should be considered in younger patients with cryptogenic stroke and PFO.

If a thrombotic source is not found in a patient with a PFO, the patient can be diagnosed with cryptogenic stroke if the above workup is negative for all known etiologies.

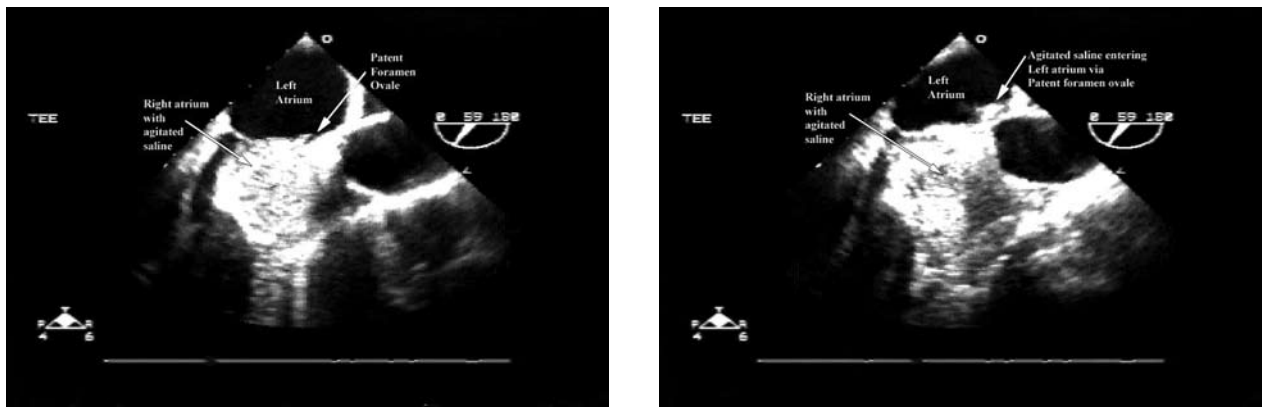


Figure 4. Transesophageal echocardiogram shows agitated saline in right atrium entering the left atrium via a patent foramen ovale (*right*).

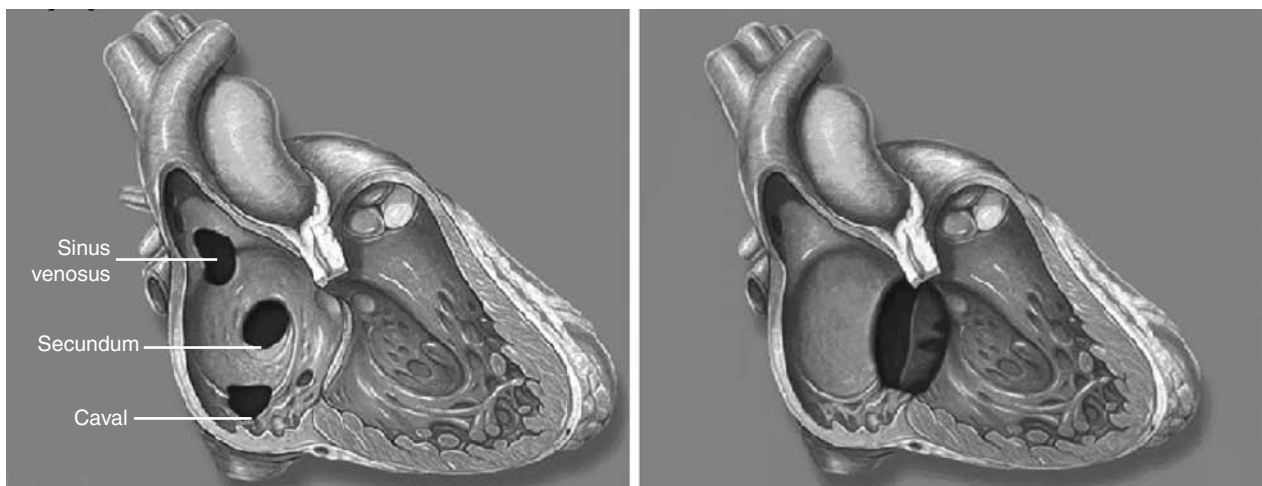


Figure 5. Other types of atrial septal defects. Sinus venosus, septum secundum, and caval defects (*left*), and septum primum defect (*right*).

Patent Foramen Ovale

Cardiac sources for embolism should be sought in addition to excluding intracranial and extracranial vascular lesions as the cause for an infarction. A PFO can be detected by TEE and TTE using saline contrast injection, and a PFO is considered to be present if microbubbles are seen in the left side of the heart within 3 cardiac cycles [7] (**Figure 4**). A Valsalva-type maneuver, particularly coughing, during saline injection may increase the sensitivity for detecting a PFO [21]. TEE has been shown to be superior to TTE for the detection of a potential cardiac source of embolism [8]. TEE has been shown to identify intracardiac thrombus in more than 55% of patients with unexplained stroke, as compared with TTE, which identifies thrombus in 25% of patients with clinically apparent heart disease and in less than 10% of patients without cardiac signs and symptoms [22].

Another diagnostic option is transcranial Doppler (TCD) sonography, which insonates the middle cerebral artery to identify right-to-left shunting of microbubbles. However, any right-to-left shunt (**Figure 5**) (atrial septal defect, ventricular septal defect, intrapulmonary shunt) may result in the detection of microbubbles in the cerebral circulation by TCD without identifying the specific shunt site [7]. Morphologic characteristics of the interatrial septum or other cardiac structures are not directly visualized with this study, making it a good test for screening but not for final diagnosis [7]. The accuracy for detecting right-to-left shunting is similar between TCD and TEE [6,7], and current guidelines do not recommend one test over the other [23]. Nonetheless, the diagnostic test of choice for identifying a PFO is TEE due to its higher sensitivity and specificity as well as increased diagnostic yield [7].

Table 1. Randomized Controlled Trials for Secondary Prevention of Recurrent Ischemic Stroke

Study	Medication	Results
CAPRIE 1996 [25]	Aspirin 325 mg daily vs. clopidogrel 75 mg daily	Clopidogrel reduced the relative risk for the primary end point of death, MI, or stroke by 8.7% In subgroup of stroke patients, relative risk reduction of an estimated 7.3% was not statistically significant
ATC 2002 [26]	Antiplatelet (aspirin, clopidogrel, dipyridamole + aspirin) vs. controls Meta-analysis of 195 RCTs	Antiplatelet therapy reduced the relative risk of nonfatal stroke by 25% Absolute benefit was a reduction of 36 events per 1000 patients Aspirin ≥ 150 mg daily was effective for initial loading Aspirin 75–150 mg daily was effective for long-term use
WARSS 2001 [27]	Warfarin (INR 1.4–2.8) vs. aspirin 325 mg daily	Death or recurrent ischemic stroke: warfarin 17.8% vs. aspirin 16%; hazard ratio, 1.13 (95% CI, 0.92–1.38); <i>P</i> = 0.25 Minor hemorrhage: warfarin 23.7% vs. aspirin 17%; odds ratio, 1.51 (95% CI, 1.22–1.87); <i>P</i> ≤ 0.001
PICSS 2002 [28]	Warfarin (INR 1.4–2.8) vs. aspirin 325 mg daily	Cryptogenic stroke patients with and without PFOs (subpopulation of the WARSS trial) With PFO, recurrent ischemic stroke or death: warfarin 9.5% vs. aspirin 17.9%; hazard ratio, 0.52 (95% CI, 0.16–1.67); <i>P</i> = 0.28 Without PFO, recurrent ischemic stroke or death: warfarin 8.3% vs. aspirin 16.3%; hazard ratio, 0.5 (95% CI, 0.19–1.31); <i>P</i> = 0.16
MATCH 2004 [29]	Clopidogrel 75 mg daily vs. aspirin 75 mg daily plus clopidogrel 75 mg daily	Minor hemorrhage: aspirin + clopidogrel 23.7% vs. aspirin 17%; odds ratio, 1.51 (95% CI, 1.22–1.87); <i>P</i> ≤ 0.001
CHARISMA 2006 [30]	Aspirin 75–162 mg daily vs. aspirin 75–162 mg daily plus clopidogrel 75 mg daily	Recurrent stroke: combination therapy did not reduce risk Hemorrhage: increased risk for moderate bleed (2.1% vs. 1.3%) with combination therapy
ESPRIT 2006 [31]	Aspirin 30–325 mg daily vs. aspirin plus ER-DP twice daily	Significant risk reduction for the primary end point (death, stroke, MI) with aspirin + ER-DP compared with aspirin alone (13% vs. 16%; hazard ratio, 0.8; [95% CI, 0.66–0.98])
PRoFESS 2008 [32]	Aspirin 25 mg plus ER-DP 200 mg twice daily vs. clopidogrel 75 mg daily	Recurrent stroke: no difference in risk reduction with aspirin + ER-DP vs. clopidogrel (9% vs. 8.8%; hazard ratio, 1.01 [95% CI, 0.92–1.11])

CI = confidence interval; ER-DP = extended-release dipyridamole; PFO = patent foramen ovale.

Treatment

Once a cryptogenic stroke is diagnosed and a PFO with/without an ASA is detected, secondary prevention for recurrent ischemic stroke should be instituted. The options for secondary stroke prevention include medication therapy, percutaneous PFO closure, or surgical closure. No consensus is currently available regarding the optimal treatment strategy because large randomized controlled trials (RCTs) with sufficient power have not been done to compare these alternatives.

Medical Management

Medical therapy for prevention of a recurrent ischemic stroke has been aimed at preventing a thromboembolic

event by limiting the formation of the platelet plug via antiplatelet-aggregation agents and by interfering with the formation of the fibrin meshwork via anticoagulants [24].

Except for 1 study, trials for prevention of ischemic strokes [25–32] have not specifically studied patients with cryptogenic strokes and PFOs. Only the Patent Foramen Ovale in Cryptogenic Stroke Study (PICSS) trial [28] studied patients with cryptogenic strokes and PFOs, and although the findings were suggestive they were not statistically significant. Trials with statistically significant results have included many different subtypes of ischemic strokes (including cryptogenic strokes) and have combined ischemic strokes with other cardiovascular events in their endpoint analyses. Consequently, medical treatment recommendations specifically for patients

with cryptogenic strokes and PFOs have had to be extrapolated from these wider-population studies.

Early trials for ischemic stroke prevention were reviewed in a large meta-analysis of 195 RCTs. The Antithrombotic Trialists' Collaboration (ATC) study [26] reviewed these RCTs that compared various antiplatelet agents with controls (Table 1). Aspirin demonstrated a 25% relative risk reduction for preventing recurrent nonfatal strokes in the acute stroke phase. Currently, early aspirin therapy (< 48 hours) is recommended for candidates who do not qualify for thrombolytic therapy; however, other agents have shown better efficacy for long-term prevention of ischemic strokes.

The Warfarin-Aspirin Recurrent Stroke Study (WARSS) [27] was a large RCT comparing anticoagulation with warfarin versus antiplatelet therapy with aspirin (Table 1). Aspirin was the most effective antiplatelet agent at that time but still carried an 8% risk of recurrent ischemic stroke [27]. Warfarin was the most effective agent in preventing ischemic strokes in patients with atrial fibrillation [33,34]. The WARSS study investigated whether anticoagulation could reduce recurrent ischemic strokes based on the theory that some ischemic strokes are due to thromboembolism. Warfarin, however, did not show any benefit over aspirin in this stroke population, but did increase the risk of noncerebral hemorrhages [24,27].

The PICSS trial [28] studied patients with cryptogenic strokes with and without PFOs from a subpopulation of the WARSS trial. In cryptogenic stroke patients with PFOs, warfarin showed a risk reduction of 46.9% ($P = 0.28$) over aspirin for prevention of recurrent stroke or death. In cryptogenic stroke patients without PFOs, warfarin demonstrated a risk reduction of 49% ($P = 0.16\%$) for the same endpoints over aspirin [28]. Although not statistically significant, these findings suggest that warfarin may have a role in preventing ischemic strokes in patients with cryptogenic strokes, whether there is a PFO or not. Other situations in which anticoagulation could be considered are in hypercoagulable states, atrial fibrillation in patients with PFOs, and when a thrombus is visualized.

Other large RCTs have been conducted to compare antiplatelet agents (eg, aspirin, clopidogrel, dipyridamole) used alone or in combination therapy (ie, aspirin plus ER-DP, aspirin plus clopidogrel) [25,29,30,32] for secondary prevention of ischemic strokes (Table 1). The Clopidogrel versus Aspirin in Patients at Risk of Ischaemic Events (CAPRIE) trial showed a statistically significant relative risk reduction for clopidogrel over medium-dose aspirin in the primary endpoint of stroke, myocardial infarction (MI) and peripheral vascular disease [25]. In the subgroup of ischemic stroke, the relative risk reduction of an estimated 7.3% was not statistically significant [30]. The combination of aspirin plus clopidogrel did not show any benefit over aspirin alone

in the Management of Atherothrombosis with Clopidogrel in High-risk patients (MATCH) trial but did increase the risk of a nonmajor bleed [29]. The combination of aspirin plus extended-release dipyridamole (ER-DP) showed no significant difference compared with clopidogrel in the Prevention Regimen for Effectively Avoiding Second Strokes (PRoFESS) trial [32].

The combination of aspirin plus ER-DP did show benefit over aspirin in the European/Australasian Stroke Prevention in Reversible Ischaemia Trial (ESPRIT) trial in reducing recurrent stroke and the composite of death, stroke, and MI [31]. The 2008 guidelines from the American Heart Association/American Stroke Association and the American College of Chest Physicians have either recommended or suggested aspirin plus ER-DP over aspirin [35,36]. Clopidogrel is recommended when aspirin is contraindicated. Aspirin plus clopidogrel is not recommended for stroke prevention, but the combination is recommended in the setting of certain situations with coronary artery disease, such as after stenting [35].

Percutaneous PFO Closure

Endovascular closure of PFOs has largely replaced surgical closure due to the morbidity associated with open thoracotomy needed for the surgical procedure. Moreover, percutaneous closure does not require general anesthesia and allows rapid recovery [37].

In theory, transcatheter closure of PFO eliminates the risk of paradoxical embolism and may avoid the necessity of long-term anticoagulation. Available data addressing the efficacy of endovascular PFO closure versus medical therapy in the management of cryptogenic stroke is limited to case series. In a nonrandomized study, percutaneous closure showed a nonsignificant risk reduction of death, stroke, and transient ischemic attack compared with medical treatment (8.5% vs. 24.3%; $P = 0.05$) as well as a reduction in the risk of stroke recurrence (7.8% vs. 22.2%; $P = 0.08$) [38]. Furthermore, a systematic review found that medically managed patients had a recurrent rate of stroke of 3.8% to 12% compared with patients undergoing percutaneous closure of 0% to 4.9% [14]. These reviews have shown that percutaneous closure may have more favorable outcomes over medical therapy in the treatment of patients with cryptogenic stroke and PFO by reducing the risk of death, stroke, and TIA [14,38]. However, these studies were not prospective and did not randomize patients; as such, the outcomes limit a significant comparison between medical management and percutaneous PFO closure. Current guidelines state that there is insufficient evidence to make a definitive recommendation for one treatment modality over the other [18]. Recently, a science advisory from the American Heart Association/American Stroke Association and the American

Table 2. Current Ongoing Clinical Trials on Patent Foramen Ovale (PFO) Closure

Study	Device Utilized	Start Date	Enrollment	Additional Information
CLOSURE-1 Evaluation of the STARFlex septal closure system in patients with a stroke or TIA due to the possible passage of a clot of unknown origin through a PFO	STARFlex septal closure system	2003	Closed	www.clinicaltrials.gov Identifier # NCT00201461
PC-Trial PFO and cryptogenic embolism	Amplatzer PFO occluder	2000	Closed	www.clinicaltrials.gov Identifier # NCT00166257
RESPECT Randomized evaluation of recurrent stroke comparing PFO closure with established current standard of care treatment	Amplatzer PFO occluder	2003	Ongoing	www.strokecenter.org/trials www.clinicaltrials.gov Identifier # NCT00465270
REDUCE GORE HELEX septal occluder for PFO closure in stroke patients	GORE HELEX septal occluder	2008	Ongoing	www.clinicaltrials.gov Identifier # NCT00738894

Adapted from reference 39.

College of Cardiology Foundation strongly encouraged all clinicians involved in the care of patients with cryptogenic stroke and PFO to consider referral for enrollment in these trials to help resolve the uncertainty regarding optimal care for this condition [39].

The risks associated with endovascular closure are not insignificant and complication rates range from 1.5% to 10%. Serious complications include major hemorrhage, cardiac tamponade, pulmonary embolism, the need for surgery, device embolization, and death. Complications reported as minor have included atrial arrhythmias, air embolism, device fracture, and fistula [7–9].

Currently, RCTs comparing medical therapy versus percutaneous PFO closure in patients with cryptogenic stroke are underway. These RCTs are the CLOSURE-1, RESPECT, PC-Trial, and REDUCE, which are investigating different closure devices. CLOSURE-1 and PC-Trial are closed to patient recruitment and are in the follow-up phase, while RESPECT and REDUCE trials are still recruiting patients (Table 2) [39]. These studies are near completion and may provide the answers for determining the best treatment strategy in patients with this condition.

Case Resolution

During the acute phase of the stroke, the patient was medically treated with aspirin. The patient’s neurologic status improved minimally, and there was no evidence of new infarcts either clinically or on subsequent brain imaging. Sources of paradoxical embolus were investigated with venous duplex ultrasonography of bilateral lower extremities

and MRV of the inferior vena cava and deep pelvic veins, but these studies did not show any evidence of thromboembolic disease. A workup for vasculopathies, hypercoagulable states, and hematologic disorders proved unremarkable. Aspirin was subsequently replaced with aspirin plus ER-DP for secondary prevention of recurrent stroke.

After discussions with the patient and his family, the patient decided to enroll in the CLOSURE-1 trial. Percutaneous PFO closure was performed without complications. Subsequently, the patient continued to improve neurologically, did not exhibit any signs of further strokes, and was eventually able to return to work.

Conclusion

Cryptogenic stroke is a diagnosis of exclusion that employs extensive imaging modalities to eliminate known etiologies. There is a high prevalence of PFOs in patients with cryptogenic strokes, and the concomitant presence of an ASA potentiates the risk for a first time or recurrent ischemic stroke. PFOs and ASAs are best detected by TEE. For the secondary prevention of recurrent stroke, aspirin plus ER-DP or clopidogrel alone is recommended over aspirin alone. Even with optimal medical therapy, the risk of recurrent ischemic stroke is consequential. Percutaneous closure of PFOs may prove to be an alternative to medical therapy, and current RCTs are comparing this seemingly low-risk procedure with medical management. Ongoing trials hold the promise for a definitive answer to the question of optimal treatment of patients with PFOs and cryptogenic stroke.

Corresponding author: Joo A. Lee, MD, Riverside Methodist Hospital, 3525 Olentangy River Rd., Suite 4330, Columbus, OH 43214, jalee3d@gmail.com.

Financial disclosures: None.

References

- Lloyd-Jones D, Adams R, Carnethon M, et al. Heart disease and stroke statistics—2009 update: a report from the American Heart Association Statistics Committee and Stroke Statistics Subcommittee. *Circulation* 2009;119:e21–181.
- Sacco RL, Ellenberg JH, Mohr JP, et al. Infarcts of undetermined cause: the NINCDS stroke data bank. *Ann Neurol* 1989;25:382–90.
- Doufekias E, Segal A, Kizer J. Cardiogenic and aortogenic brain embolism. *J Am Coll Cardiol* 2008;51:1049–59.
- Lechat P, Mas JL, Lascault G, et al. Prevalence of patent foramen ovale in patients with stroke. *N Engl J Med* 1988;318:1148–52.
- Saver JL. Emerging risk factors for stroke: patent foramen ovale, aortic arch atherosclerosis, antiphospholipid antibodies, and activated protein C resistance. *J Stroke Cerebrovasc Dis* 1997;6:167–72.
- Kerut EK, Norfleet WT, Plotnick GD, et al. Patent foramen ovale: a review of associated conditions and the impact of physiological size. *J Am Coll Cardiol* 2001;38:613–23.
- Homma S, Sacco RL. Patent foramen ovale and stroke. *Circulation* 2005;112:1063–72.
- Kizer JR, Devereux RB. Patent foramen ovale in young adults with unexplained stroke. *N Engl J Med* 2005;353:2361–72.
- Saver JL. Cryptogenic stroke in patients with patent foramen ovale. *Curr Atheroscler Rep* 2007;9:319–25.
- Overell JR, Bone I, Lees KR. Interatrial septal abnormalities and stroke: a meta-analysis of case-control studies. *Neurology* 2000;55:1172–9.
- Mas JL, Arquizan C, Lamy C, et al. Recurrent cerebrovascular events associated with patent foramen ovale, atrial septal aneurysm, or both. *N Engl J Med* 2001;345:1740–6.
- Goel SS, Tuzcu EM, Shishebor MH, et al. Morphology of the patent foramen ovale in asymptomatic versus symptomatic (stroke or transient ischemic attack) patients. *Am J Cardiol* 2009;103:124–9.
- Meacham RR, Headly AS, Bronze MS, et al. Impending paradoxical embolism. *Arch Intern Med* 1998;158:438–48.
- Khairy P, O'Donnell CP, Landzberg MJ. Transcatheter closure versus medical therapy of patent foramen ovale and presumed paradoxical thromboemboli: a systematic review. *Ann Intern Med* 2003;139:753–60.
- Cabanes L, Mas JL, Cohen A, et al. Atrial septal aneurysm and patent foramen ovale as risk factors for cryptogenic stroke in patients less than 55 years of age. A study using trans-esophageal echocardiography. *Stroke* 1993;24:1865–73.
- Maredu RK, Shah M, Mesa J, et al. Percutaneous closure of patent foramen ovale: a case series and literature review. *Clin Med Res* 2007;5(4):218–26.
- Adams HP Jr, Bendixen BH, Kappelle LJ, et al. Classification of subtype of acute ischemic stroke. Definitions for use in a multicenter clinical trial. TOAST. Trial of Org 10172 in Acute Stroke Treatment. *Stroke* 1993;24:35–41.
- Sacco RL, Adams R, Albers G, et al. Guidelines for prevention of stroke in patients with ischemic stroke or transient ischemic attack: a statement for healthcare professionals from the American Heart Association/American Stroke Association Council on Stroke: co-sponsored by the Council on Cardiovascular Radiology and Intervention: the American Academy of Neurology affirms the value of this guideline. *Stroke* 2006;37:577–617.
- Hirsh J. Diagnosis of venous thrombosis and pulmonary embolism. *Am J Cardiol* 1990;65:45C–9C.
- Cramer S, Rordorf G, Maki JH, et al. Increased pelvic vein thrombi in cryptogenic stroke. Results of the paradoxical emboli from large veins in ischemic stroke (PELVIS) study. *Stroke* 2004;35:46–50.
- Stoddard MF, Keedy DL, Dawkins PR. The cough test is superior to the valsalva maneuver in the delineation of right-to-left shunting through a patent foramen ovale during contrast transesophageal echocardiography. *Am Heart J* 1993;125:185–9.
- Rahmatullah AF, Rahko PS, Stein JH. Transesophageal echocardiography for the evaluation and management of patients with cerebral ischemia. *Clin Cardiol* 1999;22:391–6.
- Cheitlin MD, Armstrong WF, Aurigemma GP, et al. ACC/AHA/ASE 2003 guideline update for the clinical application of echocardiography—summary article: a report of the American College of Cardiology/American Heart Association Task Force on Practice Guidelines (ACC/AHA/ASE Committee to Update the 1997 Guidelines for the Clinical Application of Echocardiography). *J Am Soc Echocardiogr* 2003;16:1091–110.
- Hankey GJ. Warfarin-aspirin recurrent stroke study (WARSS) trial: is warfarin really a reasonable therapeutic alternative to aspirin for preventing recurrent noncardioembolic ischemic stroke? *Stroke* 2002;33:1723–6.
- CAPRIE Steering Committee. A randomised, blinded trial of clopidogrel versus aspirin in patients at risk of ischaemic events (CAPRIE). *Lancet* 1996;348:1329.
- Antithrombotic Trialists' Collaboration. Collaborative meta-analysis of randomised trials of antiplatelet therapy for prevention of death, myocardial infarction, and stroke in high risk patients. *BMJ* 2002;324:71–86.
- Mohr JP, Thompson JLP, Lazar RM, et al. A comparison of warfarin and aspirin for the prevention of recurrent ischemic stroke. *N Engl J Med* 2001;345:1444–51.
- Homma S, Sacco RL, Di Tullio RD, et al. Effect of medical treatment in stroke patients with patent foramen ovale. Patent Foramen Ovale in Cryptogenic Stroke study. *Circulation* 2002;105:2625–31.
- Diener HC, Bogousslavsky J, Brass LM, et al. Aspirin and clopidogrel compared with clopidogrel alone after recent ischaemic stroke or transient ischaemic attack in high-risk patients (MATCH): randomised, double-blinded, placebo-controlled trial. *Lancet* 2004;35:331–7.
- Bhatt DL, Fox KA, Hacke W, et al. Clopidogrel and aspirin versus aspirin alone for the prevention of atherothrombotic events. *N Engl J Med* 2006;354:1706–17.

31. Halkes PH, van Gijn J, Kappelle LJ, et al. Aspirin plus dipyridamole versus aspirin alone after cerebral ischaemia of arterial origin (ESPRIT): randomised controlled trial. *Lancet* 2006;367:1665–73.
32. Sacco RL, Diener HC, Yusuf S, et al. Aspirin and extended-release dipyridamole versus clopidogrel for recurrent stroke. *N Engl J Med* 2008;359:1238–51.
33. Stroke Prevention in Atrial Fibrillation Investigators. Warfarin versus aspirin for prevention of thromboembolism in atrial fibrillation: Stroke Prevention in Atrial Fibrillation II study. *Lancet* 1994;343:687–91.
34. Petersen P, Bowsen G, Godtfredsen J, et al. Placebo-controlled, randomised trial of warfarin and aspirin for prevention of thromboembolic complications in chronic atrial fibrillation: the Copenhagen AFASAK study. *Lancet* 1989;1:175–9.
35. Adams RJ, Albers G, Alberts MJ, et al. Update to the AHA/ASA recommendations for the prevention of stroke in patients with stroke and transient ischemic attack. *Stroke* 2008;39:1647–52.
36. Albers GW, Amarenco P, Easton JD, et al. Antithrombotic and thrombolytic therapy for ischemic stroke: American College of Chest Physicians evidence-based clinical practice guidelines. 8th ed. *Chest* 2008;133:630S–69S.
37. Wechsler LR. PFO and stroke. What are the data? *Cardiol Rev* 2008;16:53–7.
38. Windecker S, Wahl A, Nedeltchev K, et al. Comparison of medical treatment with percutaneous closure of patent foramen ovale in patients with cryptogenic stroke. *J Am Coll Cardiol* 2004;44:750–8.
39. O’Gara PT, Messe SR, Tuzcu EM, et al. Percutaneous device closure of patent foramen ovale for secondary stroke prevention: a call for completion of randomized clinical trials. *Circulation* 2009;119:2743–7.