Evaluation and Management of Adult Chronic Rhinosinusitis

Case Study and Commentary, *Bharat B. Yarlagadda, MD, and Anand K. Devaiah, MD*

CME jointly sponsored by Wayne State University School of Medicine and JCOM

This article is a CME activity. The quiz appears on pages 342–3. Estimated time to complete this activity is 1 hour. Release date: 15 July 2009; valid for credit through 30 July 2010.

Editors' disclosures:
Bobbie Lewis, Editor, JCOM—nothing to disclose
David Pieper, PhD, Wayne State CME—nothing to disclose

Authors' disclosures:
Anand Devaiah, MD—consultant, OmniGuide, Inc.

Program Audience

Primary care physicians.

Educational Needs Addressed

Chronic rhinosinusitis (CRS) is a common disease affecting approximately 31 million adults in the United States. It accounts for billions of dollars in health care expenditures annually and loss of productivity in the workplace. Evolving definitions and diagnostic criteria are in place to expedite management of the disease. Expanding knowledge of the pathophysiology of CRS forms the basis of current treatment regimens. Patients who fail medical management with antibiotics and topical steroids may be amenable to surgical treatment. Primary care physicians will routinely face this disease and should be familiar with the most current guidelines in diagnosis and treatment.

Educational Objectives

After participating in this CME activity, primary care physicians should be able to

1. Discuss the etiology and pathophysiology of CRS
2. Identify the current criteria for diagnosis of CRS
3. Describe the management algorithm for CRS, especially for those patients with initial treatment failures
4. Discuss the role of surgery in CRS

Chronic rhinosinusitis (CRS) is a common disease affecting up to 12.5% of the adult population in America, approximately 31 million people [1]. Based on sheer numbers, the disease greatly impacts the health care system and the national economy as a whole. One survey found that over 22 million office visits per year in the United States are related to a CRS diagnosis [2]. In 1996 alone, national health care expenditures attributable to CRS were estimated at $3.39 billion, spent on office visits, medications, and surgical treatments [3]. Indirect costs were even greater at $5.8 billion due to 12.5 million lost workdays and 58.7 million restricted workdays [3,4]. On an individual level, this amounts to $921 in costs and 4.8 lost workdays per patient-year [5].

Current controversies regarding CRS revolve around the definition, diagnosis, and treatment. National multispecialty committees have convened to standardize diagnostic criteria and formulate an approach to treatment with a focus on evidence-based management [6,7]. Research efforts focus on identifying the underlying pathophysiology with the hope of tailoring treatment.

CASE STUDY

Initial Presentation

A 35-year-old woman presents to her primary care physician complaining of nasal obstruction and facial congestion for the past 4 months.

History

The patient reports a feeling of bilateral nasal congestion creating a sensation of obstructed breathing. She finds herself constantly blowing her nose, with purulent discharge. She also complains of facial pressure and congestion focused over her midface. These sensations have been constantly present over the past 4 months. She denies fevers or chills, epistaxis, acute changes in symptoms, or weight loss. These symptoms have occurred in the past several years but never for this duration. Previous episodes were treated with oral antibiotics, but termination of symptoms did not correlate with the

From the Department of Otolaryngology—Head & Neck Surgery, Boston University School of Medicine, Boston, MA.

course of treatment. She also complains of constant fatigue affecting her performance at work. This has been worsening over the past 4 months. Her past medical history is significant for seasonal allergies for which she takes over-the-counter antihistamines. She is an otherwise healthy mother of 2 who exercises regularly and quit smoking over 10 years ago.

Physical Examination

The patient is a healthy-appearing woman with a blood pressure of 125/70 mm Hg, heart rate of 70 bpm and regular, height of 64 in, and a weight of 135 lb (body mass index, 23.2 kg/m^2). Heart and lung sounds are normal. Examination of the head and neck reveals a nasal septum deviated to the right. Anterior rhinoscopy shows bilateral hypertrophy of the inferior turbinates with mucopurulent discharge. Palpation of the face reveals discomfort over the maxillary and frontal sinuses. The remainder of the head and neck examination is otherwise unremarkable.

- **What is the impact of CRS on quality of life?**

Over the past decade, researchers have studied the effects of CRS on patients with the disease. Though quality of life (QOL) measurements specific to CRS have been developed, the impact of the disease can perhaps be best appreciated when using a broad QOL scale [1]. In a 1995 study utilizing the Medical Outcome Study Short-Form 36 [8], patients with CRS had significantly worse scores in measures of bodily pain and social functioning than patients with congestive heart failure, chronic obstructive pulmonary disease, angina, or chronic back pain/sciatica [9]. The disease burden is underscored by the fact that the CRS cohort was on average 20 years younger (average age, 42.3 years) and suffered from less comorbidity than the patients in the other disease cohorts.

As a result of the high prevalence, a variety of practitioners confront CRS, including those in family practice, internal medicine, emergency medicine, pediatrics, allergy, and otolaryngology. This has led to significant practice variations across and within these disciplines [7]. To reduce such variance, the American Academy of Otolaryngology—Head and Neck Surgery (AAO-HNS) assembled a multidisciplinary rhinosinusitis task force (RSTF). Reports of the 1996 RSTF proceedings, updated in 2003, detail the classification schema for CRS and related diseases, criteria for establishing a diagnosis, and treatment protocols, with an emphasis on evidence-based guidelines [6,10].

- **How is CRS defined and what is the pathogenesis?**

Rhinosinusitis is defined as a symptomatic inflammatory condition of mucosa of the nasal cavity and paranasal sinuses, the fluids within these sinuses, and/or the underlying bone [11]. The term "sinusitis" has been supplanted by "rhinosinusitis" due to evidence that the nasal mucosa is almost universally involved in the disease process [12]. Duration of symptoms plays a key role in classification. The term "chronic" is used when the condition is present for at least 12 consecutive weeks, differentiating CRS from other clinical varieties of rhinosinusitis as seen in **Table 1** [6,11]. Uncomplicated CRS is disease without extension beyond the paranasal sinuses or nasal cavity (ie, without ophthalmologic, neurologic, or soft tissue involvement) [7].

The etiology of CRS is a subject of debate and ongoing research. The current hypothesis involves a multifactorial pathogenesis. The paranasal sinuses are a group of paired, aerated cavities lined with pseudostratified ciliated columnar mucosa that drain into the nasal cavity via the sinus ostia. Several ostia are in close vicinity of the middle meatus, leading to the popular concept of an "osteomeatal complex" as the focus of pathology [13]. Though the true anatomic role of the paranasal sinuses is uncertain, their ability to clear normal mucus secretions depends on 3 major factors: ostial patency, ciliary function, and mucus consistency [11,14]. Any variety of inciting factors may irritate the sinus mucosa leading to inflammation, edema, bacterial proliferation, outflow obstruction, and mucociliary dysfunction.

It has become common in the recent literature to categorize CRS with nasal polyps (CRSwNP) as a subset of CRS if not a distinct entity altogether [15]. CRSwNP is diagnosed based on the endoscopic presence of polyps or polypoid changes near the middle meatus. The differences between the 2 forms are many. Histopathology of sinus mucosa in CRS shows an involvement of neutrophils and mononuclear cells with goblet cell hyperplasia, whereas eosinophils predominate the mucosa in CRSwNP [15]. The milieu of inflammatory mediators and cytokine profiles also differ, with an increase in leukotriene production in polypoid tissue [16]. These differences have implications regarding disease management and response to therapy. Though the 2 forms have overlapping symptomology, patients with CRSwNP have a greater burden of illness and lower QOL scores [17].

The contribution of allergy to the pathogenesis of CRS should not be underestimated. The allergic response, a condition of edema, inflammation, increased vascular permeability, mucus hypersecretion, and impaired ciliary function, may directly contribute to the development of CRS [6]. Up to 84% of medically refractory CRS patients have been shown to have an allergic component [18]. There is a stronger relationship with perennial than seasonal allergies, and these patients display more significant radiographic findings of sinus disease than nonallergic patients, especially seen

Table 1. Classification of Rhinosinusitis

	Duration	Strong History	Include in Differential	Notes
Acute	Up to 4 weeks	≥ 2 major factors, 1 major + 2 minor factors	1 major factor, ≥ 2 minor factors	Fever or facial pain do not constitute suggestive history in absence of other signs or symptoms
Subacute	4–12 weeks	Same as Chronic	Same as Chronic	Complete resolution after effective medical therapy
Chronic (CRS)	≥ 12 weeks	≥ 2 major factors, 1 major + 2 minor factors,* requires objective findings	1 major factor, ≥ 2 minor factors	Fever or facial pain do not constitute suggestive history in absence of other signs or symptoms
Recurrent, acute	≥ 4 episodes/year, each episode lasts 7–10 days with absence of intervening signs of CRS	Same as Acute	Same as Acute	
Acute exacerbations of chronic	Sudden worsening of CRS with return to baseline after treatment			

Adapted from Lanza DC, Kennedy DW. Adult rhinosinusitis defined. Otolaryngol Head Neck Surg 1997;117(3 pt 2):S1–7. Copyright 1997, with permission from Elsevier.

*Recent guideline revisions have emphasized the presence of major factors rather than minor factors in order to make a diagnosis.

after nasal allergen challenge [18,19]. There is also a strong relationship between allergy and development of polypoid disease, possibly through the induction of chronic inflammation that continues long after allergen exposure [20,21].

Microbes have a controversial role in CRS. Though viral prodromes are known to precede and possibly prime the sinus mucosa for episodes of viral rhinosinusitis [22], viral infections are not usually targeted as a part of CRS treatment. The use of antibacterial agents, however, has remained a first-line treatment for many practitioners despite the questionable role of bacteria [6]. The paranasal sinuses, normally considered sterile, house a characteristic set of bacteria in CRS. A 2005 meta-analysis showed that greater than half of CRS patients studied produced polymicrobial flora dominated by anaerobes such as a *Peptostreptococcus* species and *Fusobacterium* as well as *Staphylococcus aureus* and coagulase-negative *Staphylococcus* [23,24]. This is in contrast to the usual pathogens in acute bacterial rhinosinusitis: *Streptococcus pneumoniae, Haemophilus influenzae* and *Moraxella catarrhalis* [13]. The literature is replete with studies showing favorable patient response to treatment with antibiotics targeting these species, suggesting that there is some role for bacteria in CRS etiology [25].

Current research emphasizes the inflammatory response to the presence of bacteria rather than the action of microbes themselves. The finding of a sinus mucosal infiltrate of eosinophils, plasma cells, and lymphocytes suggests a process of "bacterial allergy" [6]. In reality, there is likely a spectrum of illness ranging from an infectious etiology to a purely noninfectious inflammation [24].

Though allergic fungal rhinosinusitis is considered a distinct entity from the CRS discussed in this review, the role of fungi has gained recent attention. Despite the ubiquitous presence of fungi in the nasal cavities of all humans, there is much interest in the ability of fungal allergens to instigate eosinophilic inflammation in susceptible carriers [6,26,27].

Systemic factors also predispose to the development of CRS. Cystic fibrosis patients develop chronic mucosal inflammation and nasal polyps causing mechanical obstruction of sinus ostia [28]. A history of smoking correlates positively with the development of CRS, conferring a 43 times greater risk of developing CRSwNP [29,30]. Patients with inflammatory syndromes such as Wegener's granulomatosis and sarcoidosis are prone to forms of CRS that often require treatment outside of the normal algorithm [31]. Primary ciliary dyskinesia is an example of CRS caused by a defect in a specific element of mucociliary clearance [32]. When clinically suspected, testing for the presence of the above conditions will assist in tailoring treatment.

The etiology of CRS is a complex matter involving many factors occurring in concurrence or individually. However, all of these factors converge onto a common pathway of a state of mucosal inflammation manifesting as clinical disease. From history alone, several of these factors may play a role in the case of our clinic patient.

- **What is the initial approach to a patient with CRS?**

Table 2. Factors Associated with Diagnosis of Chronic Rhinosinusitis

Major Factors	Minor Factors
Nasal obstruction/blockage	Headache
Nasal discharge/purulence or discolored postnasal drainage	Fever (all nonacute varieties)
Purulence in nasal cavity on examination	Halitosis
Facial pain/pressure*	Fatigue
	Cough
	Ear pain/pressure/fullness
	Dental pain
	Hyposmia/anosmia†

Adapted with permission from Report of the Rhinosinusitis Task Force Committee Meeting. Alexandria, Virginia, August 17, 1996. Otolaryngol Head Neck Surg 1997;117(3 Pt 2):S1–68 *and* Fokkens W, Lund V, Mullol J. European position paper on rhinosinusitis and nasal polyps 2007. Rhinol Suppl 2007;(20):1–136.

*Of note, facial pain/pressure alone does not constitute a suggestive history for rhinosinusitis in the absence of another major nasal symptom or sign.

†Recently excluded as a major factor.

Initial Clinic Encounter

Criteria for a diagnosis of CRS have undergone recent changes. The RSTF designated the most common patient complaints associated with CRS as either "major" or "minor" (**Table 2**) [6,11]. According to the initial RSTF guidelines, a diagnosis of CRS can be made by history alone, in the presence of 2 or more major factors, or 1 major factor with 2 or more minor factors. Critics of the symptoms-based diagnosis contend that neither the prevalence of a factor nor its severity correlate with a designation of major or minor [1,5]. Prospective studies have found poor correlation between symptom-based diagnosis and findings on computed tomography (CT) scan, the gold standard for detecting sinus disease [33]; as few as 47% of patients who met subjective criteria had radiologic findings of disease [34]. Thus, recent guideline revisions by both American and European multispecialty committees have suggested mandatory objective findings on anterior rhinoscopy, endoscopy, or CT as well as corroborating symptomology in order to make a diagnosis (**Table 3**) [6,35]. Further, these revisions have changed which symptoms are considered major versus minor and have placed greater emphasis on the presence of major factors alone for a diagnosis [1,35].

Criteria for including CRS in a patient's differential diagnosis are also listed in Table 1. Other entities to include on the differential are based on the presenting complaint. Temporomandibular joint pain, trigeminal neuralgia, and migraine may present with similar headache symptoms. Other pathologies affecting the sinus cavities are also included, namely inverting papilloma or neoplasia [13]. Allergic rhinitis can present with a similar clinical picture and must be distinguished based on the seasonal pattern of symptoms, presence or absence of purulence, and through dedicated allergy testing.

The physical examination of a patient with suspected CRS involves direct visualization of the nasal cavity and associated structures. Anterior rhinoscopy with an otoscope is inexpensive, convenient, and readily available and should be a part of the initial evaluation. Attention is given to the nasal septum, all visible turbinates, and for the presence of polyps, mucopus, bleeding, or crusting. Though the view can be augmented with a nasal speculum, it is restricted to the anterior and inferior nasal cavity.

Diagnosis

Our clinic patient meets the diagnostic criteria for CRS based on her complaints of nasal obstruction, purulent nasal discharge, and fatigue for a period of greater than 12 weeks, as well as a finding of mucopurulence on anterior rhinoscopy. At this point, it is appropriate to initiate therapy.

- **What is the initial treatment of CRS?**

The goal of treatment in CRS is to reduce the mucosal inflammation and impairment of mucociliary flow that is the hallmark of the disease. Successful treatment addresses the underlying cause of inflammation. However, in individual patients, it is extremely difficult to assess the contributions of infectious versus noninfectious causes. As an initial approach, many providers choose to medically treat both possibilities.

Empiric treatment with a prolonged course of orally administered broad-spectrum antibiotics has been a mainstay of treatment. Three to 4 weeks of amoxicillin with clavulanic acid is a first-line choice because of adequate penetration of the sinus mucosa and efficacy against *S. aureus* and anaerobes [15,36]. Many advocate the use of macrolides such as clarithromycin due to concurrent anti-inflammatory effects [37]. The fluoroquinolone ciprofloxacin is used with demonstrated involvement of gram-negative organisms, namely *Pseudomonas aeruginosa* [38]. Antibiotic choice is largely guided by patient tolerance and, when obtained, by culture and sensitivity results from nasal and sinus secretions [39]. There is a lack of evidence comparing randomized head-to-head efficacy of the various antibiotic classes or demonstrating a benefit of multiantibiotic regimens.

Topical antibiotics are not routinely used as primary treatment. A recent meta-analysis found improvement in symptoms and endoscopic findings of disease when topical

Table 3. Revised Criteria for Diagnosis of Chronic Rhinosinusitis

Symptoms	AND	Rhinoscopy / Endoscopy	OR	Imaging
As previously described for > 12 weeks		Discolored nasal drainage, polyposis or polypoid swelling		Computed tomography scan with mucosal thickening, or boney changes
		or		or
		Edema or erythema of the middle meatus or ethmoid bulla		Water's view plain film with > 5 mm mucosal thickening
		or		
		Generalized erythema or edema (equivocal finding, requires imaging)		

Adapted from Benninger MS, Ferguson BJ, Hadley JA, et al. Adult chronic rhinosinusitis: definitions, diagnosis, epidemiology, and pathophysiology. Otolaryngol Head Neck Surg 2003;129(3 Suppl):S1–32. Copyright 2003, with permission from Elsevier.

antibiotics are included in the postsurgical regimen [40,41]. They may also serve a role in the treatment of postsurgical acute exacerbations of CRS [42]. In nonsurgical patients, however, this modality is usually reserved for treatment failures and those patients with cultures guiding therapy, if used at all. There is ongoing debate and research regarding the use of topical antifungal therapy in the form of nebulized amphotericin B as well.

Initial medical management includes a regimen of topically applied corticosteroids. Fluticasone, beclomethasone, budesonide, and mometasone are popular choices. Topical corticosteroids have been shown to down-regulate the inflammatory cytokine profile of sinus mucosa and improve subjective patient symptoms [43–45]. Patients should be aware of the uncommon side effects of mucosal drying and bleeding. Often, the choice of agent simply depends on local practice patterns. However, the patient's overall picture should be kept in mind. For instance, budesonide is used in the treatment of allergic rhinitis and has displayed significantly greater success rates in CRS patients with this comorbidity [46]. Duration of initial therapy is up to 3 months, and patient response is unlikely before 2 weeks of use. Systemic absorption of topical agents is minimal, but there is evidence that using metered-dose inhalers, rather than spray bottles, prevents accidental overdose and subsequent adrenal suppression [43].

Nasal irrigation with physiologic (0.9%) or hypertonic (2%–3%) saline solutions is commonly recommended. A common recipe calls for mixing 2 teaspoons of table salt in 1 L of lukewarm water; buffering with a teaspoon of baking soda is optional. The practice is easy, effective, and safe. Irrigation kits are readily available over the counter for less than $20, plus the cost of ingredients. Daily irrigation has been shown to significantly decrease symptoms and improve QOL scores [47,48]. Anecdotally, patients find the practice quite satisfying. Relief is likely due to improved mucous outflow and a decrease in secretions and load of inflammatory mediators [15].

The use of topical steroids, antibiotics, and nasal irrigation form the cornerstone of maximal medical therapy, usually prescribed for up to 3 months [49,50]. Depending on the practitioner, the antibiotic regimen is used for either the entire duration or simply the first 21 to 30 days. There is growing interest in long-term (3–4 months) use of macrolides, however, due their concurrent anti-inflammatory effects [49]. Oral steroids, namely prednisone, are used by many practitioners in a burst regimen over 6 to 14 days [50]. Some authors consider this as a component of maximal medical therapy as well, especially in patients with polypoid disease [35,49,51]. Oral steroid use must be weighed against their well-known systemic side effects, such as weight gain, immunosuppression, and adrenal insufficiency.

Due to high prevalence in the CRS patient, allergic factors must be addressed early in treatment. Aggressive workup and treatment is warranted for perennial allergies specifically. Skin testing is an effective method of elucidating allergen culprits [24]. The most effective treatment is allergen avoidance, but good results are also achieved with intranasal antihistamine sprays in cases of coexisting allergic rhinitis. Referral to an allergist or immunologist may be helpful in difficult or refractory cases. Successful treatment of coexisting allergy is crucial in the care of the CRS patient; when left unaddressed, these patients have significantly decreased rate of long-term success following standard medical and surgical treatment of CRS [52].

Adjunctive medical interventions may be initiated as well. There is ongoing research into the use of leukotriene inhibitors. Theoretically effective in down-regulating eosinophilic inflammation, randomized controlled trials of these drugs as monotherapy are lacking [15]. Small open-label trials of agents such as montelukast and zafirlukast have shown symptomatic improvement when used as an adjunct to established regimens in subgroups of patients, specifically those with polypoid disease and concurrent asthma [53,54]. Though not used by the majority of practitioners, a

trial course is warranted in selected patients in light of the low morbidity of these drugs [50,55].

Some clinicians also prescribe the use of topical nasal decongestants for symptomatic use. These agents, however, should not be used for longer than 3 to 4 days because they are relatively short-acting and can cause rebound congestion with chronic use. Other directives in medical management include the use of immunotherapy to decrease inflammation, especially in patients with recalcitrant disease and those with concurrent allergic disease; this should be strongly considered in all patients and in particular with recurrent nasal polyposis or sinusitis despite empiric allergy therapy.

Follow-up

After receiving prescriptions for 3 weeks of amoxicillin-clavulanate, inhaled budesonide, and instructions regarding nasal irrigation, the patient was asked to return to the clinic in 1 month for follow-up. At the follow-up visit, the patient notes only mild improvement in her purulent discharge and continues to complain of constant nasal obstruction and fatigue. Cultures are obtained that grow a mixed flora. She is given another 3-week course of antibiotics, a 7-day course of oral prednisone, and asked to continue with the daily inhaled steroids and nasal irrigations. She returns 2 months later for follow-up, stating that she has minimal improvement of her symptoms. She expresses frustration with the inconvenience of her daily medical regimen and wishes to explore other treatment options.

- **How common is treatment failure?**

Dramatic improvement of symptoms is considered a success. The term "treatment failure" generally applies to patients with unchanged, minimally improved, or worsened symptoms after at least 3 months of maximal medical therapy [49,50].

Though some authors report an initial failure rate as low as 25% [24], this number varies significantly depending on the type of practice and duration of follow-up. A recent study found that while 77% of patients do show symptomatic improvement with medical management, the improvement is clinically significant in only 39% of patients [56]. The presence of nasal polyps is a statistically significant predictor of treatment failure and early relapse [51]. A retreatment regimen may be considered, consisting of another antibiotic, oral steroids in burst or taper, and continuing intranasal steroids and irrigation [24]. Repeat antibiotic use should be guided by results from endoscopic cultures in light of the failure of empiric choice [57]. In those with significant improvement, many practitioners recommend maintenance therapy with continued nasal irrigation and topical corticosteroids. Antibiotics are not routinely considered a part of maintenance therapy.

- **What are the steps for further workup?**

In cases of treatment failure, one must reconsider the differential diagnosis. For instance, pretreatment symptoms of facial pain and pressure are not only associated with a poor response to initial medical management but correlate poorly to objective findings of disease on imaging [56]. The presence of these symptoms thus suggests a confounding situation and warrants evaluation for alternative diagnoses. When the diagnosis of CRS is fairly certain, referral to an otolaryngologist can be helpful to continue workup and explore treatment options. Other indications for referral include the presence of severe signs including bleeding, orbital symptoms, facial swelling, uncertainty regarding diagnosis, or the presence of findings such as deviated septum, turbinate hypertrophy, or polyposis, as these conditions are amenable to surgical correction [35]. Unilateral symptoms or physical examination findings, namely unilateral polyps, should raise suspicion of a more serious condition such as malignancy or inverting papilloma [58]. A 2007 position paper released by the European Academy of Allergy and Clinical Immunology contains a diagram noting recommended points for referral to a specialist (**Figure 1**) [35].

After reviewing the history and subjective findings, further evaluation includes flexible or rigid endoscopy. The procedure is performed using local anesthesia and a topical decongestant by a trained practitioner such as an otolaryngologist. Proper technique includes evaluation of all accessible areas in the nasal cavity, including sinus drainage pathways and the nasopharynx, areas well beyond the reach of anterior rhinoscopy [59]. A positive examination includes findings of polyps, mucopurulence, mucosal edema, erythema or crusting and any anatomic variance that may lead to ostial narrowing or occlusion (**Figure 2**) [60]. Positive endoscopy has high specificity and positive predictive value for the presence of sinus disease, 86% and 74% respectively. However, the inability to visualize deep recesses of the nasal cavity leads to a relatively low sensitivity and negative predictive value.

CT scanning is the current gold standard for imaging CRS. A common protocol entails a noncontrast scan with 3-mm slices obtained in axial and coronal planes [61]. Some argue that a cost-efficient 5-mm slice protocol is sufficient as

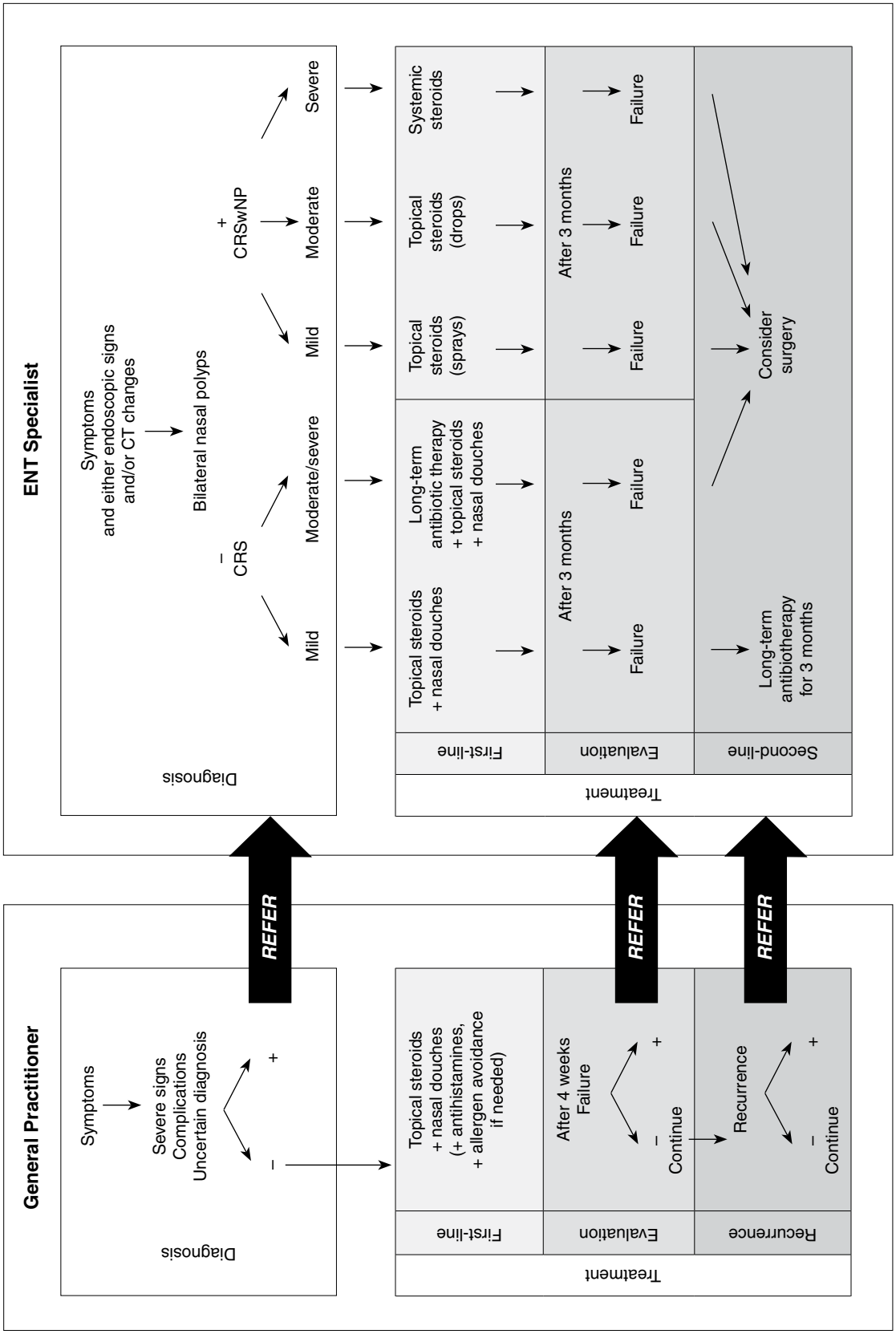

Figure 1. Recommended points of referral to an ear, nose, and throat (ENT) specialist. CRS = chronic rhinosinusitis; CRSwNP = chronic rhinosinusitis with nasal polyps; CT = computed tomography. (Adapted from Fokkens W, Lund V, Mullol J. European position paper on rhinosinusitis and nasal polyps 2007. Rhinol Suppl 2007;[20]:1–136.)

Figure 2. A finding of mucopurulence (*arrow*) under the middle turbinate on endoscopy. (Reprinted with permission from Brown C. Chronic rhinosinusitis: 'it's my sus doc!' Aust Fam Physician 2008;37:308.)

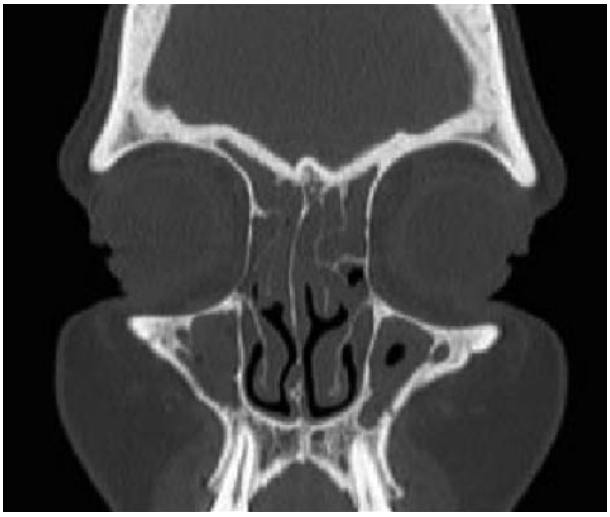

Figure 3. Coronal section of a computed tomography scan demonstrating maxillary sinus opacification (patient's right) and mucosal thickening (patient's left). (Reprinted with permission from Brown C. Chronic rhinosinusitis: 'it's my sinus doc!' Aust Fam Physician 2008;37:310.)

well [60]. The RSTF recommends use of the Lund-MacKay system to evaluate images. A score from 0 to 12 is assigned to each side of the head; an increasing score indicates more extensive mucosal thickening and ostial obstruction (**Figure 3**) [62]. When using a cutoff score of 2, CT scanning and Lund-MacKay scoring are extremely sensitive (94%) in detecting mucosal inflammation seen on histopathologic examination of surgical specimens [63]. This high sensitivity, however, leads to findings of disease in asymptomatic patients. This suggests that CT results must be used in conjunction with pretest findings.

These data might lead some to question the utility of endoscopy. Endoscopy is well suited to confirm a diagnosis made on history and anterior rhinoscopy and can be used to obtain cultures to guide antibiotic choice when empiric therapy fails. Endoscopy is invaluable in preoperative planning and postoperative surveillance and care of the surgical patient [64]. Due to its safety and relative convenience, some feel endoscopy should be incorporated in the care of almost any CRS patient [59]. CT scanning, on the other hand, is a valuable tool for confirming clinical suspicions in light of negative or equivocal endoscopic findings [65]. Many clinicians reserve CT scanning for those who fail initial medical treatment [24]. Like endoscopy, CT is essential for preoperative planning.

Other imaging modalities are not often utilized [6]. Plain films of the sinuses have low sensitivity and specificity, whereas sinus MRI is avoided due to cost and excessively high sensitivity. MRI does have a place in the evaluation of complications such as extension of disease beyond the sinuses, instances of neurologic or soft tissue involvement, and suspected neoplasia.

Follow-up

After referral for further evaluation, the patient undergoes endoscopy demonstrating mucopurulence bilaterally, with a finding of bilateral polyposis obstructing the sinus ostia. She inquires about surgical options for her condition.

- **What is the role of surgery in CRS?**

Functional endoscopic sinus surgery (FESS) is an umbrella term for minimally invasive procedures designed to restore and augment the natural drainage pathways of the paranasal sinuses [66]. FESS is performed under general anesthesia, typically as a same-day procedure. The nasal cavity is directly visualized and various specialized tools are used to relieve obstructive lesions of sinus outflow including polyps and diseased mucosa. The affected sinus air cells are opened in a manner that augments natural mucociliary outflow. In some cases surgeons opt to use real-time stereotactic image guidance provided by reconstructed CT scans, especially in difficult cases.

FESS is indicated in patients with CRS who fail maximal medical therapy or demonstrate complications of disease. Surgical complications are rare and are usually related to damage to adjacent structures including the orbit and skull base. Regular postoperative follow-up is essential. Return visits are generally scheduled for 1, 3, and 6 weeks after the

procedure and entail endoscopic surveillance and debridement of the surgical site. The results of pathologic examination of surgically removed tissue should be reviewed as soon as available to rule out conditions such as neoplasia or inverting papilloma. Medical management with antibiotics and intranasal steroids may continue postoperatively, though the exact timing of their use is under investigation [67–69]. Postoperative antibiotics should be tailored to the results of cultures obtained during surgery.

The frequency of FESS has dramatically increased over the past decade, prompting scrutiny of surgical outcomes. Though individual studies are often low-powered, most meta-analyses of long-term (> 1 year) follow-up show significant improvements in symptoms and QOL reporting [69–71]. Special note is made of dramatic postoperative improvements in fatigue and nasal congestion [69,72]. Revision FESS may be performed in those who fail to improve after the initial surgery and has been shown to provide improvement in these patients [73]. The presence of polyposis, however, complicates the long-term success of FESS. A seminal work found that the presence "advanced mucosal disease" including polyposis was a predictor of poorer outcomes [74]. This was confirmed in a 6-year follow-up study that also showed a higher rate of reoperation in patients with polyps compared with those without polyps [69]. However, it should be noted that only a minority (1 in 3) of CRSwNP required reoperation. Due to the medically refractory nature of CRSwNP, FESS remains a viable treatment option in these patients in light of findings of symptomatic postoperative improvement, at least in the short term [72].

Surgical Treatment

The patient opts to undergo an outpatient FESS procedure. There are no operative complications. She has postoperative follow-up with nasal debris removal to facilitate healing and return of function. She is maintained on her medical therapy afterward to improve sinonasal function and reduce the risk of refractory disease. At her final postoperative visit, she reports dramatic improvement in her nasal obstruction and purulence. She returns to her primary care provider for a routine visit 6 months postoperatively and reports a significant improvement in her energy level and productivity at work.

SUMMARY

CRS is a highly prevalent disease often recalcitrant to therapy. The presence of polypoid disease complicates management and worsens prognosis. CRS in any form is a source of frustration to both patient and provider and presents a tremendous economic burden to the health care system. Research into pathogenesis and the disease process has led to an evolving system for diagnosis. Medical therapy with antibiotics and intranasal steroids are the basis for first-line management, though there is a high rate of treatment failure. Surgery offers promise of relief to those that fail medical management. However, proper patient selection, counseling, and follow-up are essential for a favorable surgical outcome.

Corresponding author: Anand K. Devaiah, MD, Dept. of Otolaryngology—Head & Neck Surgery and Dept. of Neurological Surgery, Boston Univ. School of Medicine, 820 Harrison Ave., FGH Bldg., 4th Fl., Boston, MA 02118, Anand.Devaiah@bmc.org.

References

1. Meltzer EO, Hamilos DL, Hadley JA, et al; American Academy of Allergy, Asthma and Immunology (AAAAI); American Academy of Otolaryngic Allergy (AAOA); American Academy of Otolaryngology—Head and Neck Surgery (AAO-HNS); American College of Allergy, Asthma and Immunology (ACAAI); American Rhinologic Society (ARS). Rhinosinusitis: establishing definitions for clinical research and patient care. J Allergy Clin Immunol 2004;114(6 Suppl):155–212.
2. Schappert SM. Ambulatory care visits to physician offices, hospital outpatient departments, and emergency departments: United States, 1997. Vital Health Stat 13 1999;(143):i–iv, 1–39.
3. Ray NF, Baraniuk JN, Thamer M, et al. Healthcare expenditures for sinusitis in 1996: contributions of asthma, rhinitis, and other airway disorders. J Allergy Clin Immunol 1999;103 (3 Pt 1):408–14.
4. Lund VJ. Impact of chronic rhinosinusitis on quality of life and health care expenditure. Clin Allergy Immunol 2007;20:15–24.
5. Bhattacharyya N. The economic burden and symptom manifestations of chronic rhinosinusitis. Am J Rhinol 2003;17:27–32.
6. Benninger MS, Ferguson BJ, Hadley JA, et al. Adult chronic rhinosinusitis: definitions, diagnosis, epidemiology, and pathophysiology. Otolaryngol Head Neck Surg 2003;129 (3 Suppl):S1–32.
7. Rosenfeld RM, Andes D, Bhattacharyya N, et al. Clinical practice guideline: adult sinusitis. Otolaryngol Head Neck Surg 2007;137(3 Suppl):S1–31.
8. McHorney CA, Ware JE Jr, Lu JF, Sherbourne CD. The MOS 36-item Short-Form Health Survey (SF-36): III. Tests of data quality, scaling assumptions, and reliability across diverse patient groups. Med Care 1994;32:40–66.
9. Gliklich RE, Metson R. The health impact of chronic sinusitis in patients seeking otolaryngologic care. Otolaryngol Head Neck Surg 1995;113:104–9.
10. Report of the Rhinosinusitis Task Force Committee Meeting. Alexandria, Virginia, August 17, 1996. Otolaryngol Head Neck Surg 1997;117(3 Pt 2):S1–68.
11. Lanza DC, Kennedy DW. Adult rhinosinusitis defined. Otolaryngol Head Neck Surg 1997;117(3 Pt 2):S1–7.
12. Bhattacharyya N. Chronic rhinosinusitis: is the nose really involved? Am J Rhinol 2001;15:169–73.
13. Lalwani AK. Current diagnosis & treatment in otolaryngology—head & neck surgery. 2nd ed. New York: The McGraw-Hill

Companies, Inc.; 2008.
14. Keir J. Why do we have paranasal sinuses? J Laryngol Otol 2009;123:4–8.
15. Watelet JB, Eloy PH, van Cauwenberge PB. Drug management in chronic rhinosinusitis: identification of the needs. Ther Clin Risk Manag 2007;3:47–57.
16. Pérez-Novo CA, Watelet JB, Claeys C, et al. Prostaglandin, leukotriene, and lipoxin balance in chronic rhinosinusitis with and without nasal polyposis. J Allergy Clin Immunol 2005;115:1189–96.
17. Banerji A, Piccirillo JF, Thawley SE, et al. Chronic rhinosinusitis patients with polyps or polypoid mucosa have a greater burden of illness. Am J Rhinol 2007;21:19–26.
18. Emanuel IA, Shah SB. Chronic rhinosinusitis: allergy and sinus computed tomography relationships. Otolaryngol Head Neck Surg 2000;123:687–91.
19. Pelikan Z, Pelikan-Filipek M. Role of nasal allergy in chronic maxillary sinusitis—diagnostic value of nasal challenge with allergen. J Allergy Clin Immunol 1990;86(4 Pt 1):484–91.
20. Asero R, Bottazzi G. Nasal polyposis: a study of its association with airborne allergen hypersensitivity. Ann Allergy Asthma Immunol 2001;86:283–5.
21. Hamilos DL. Chronic rhinosinusitis patterns of illness. Clin Allergy Immunol 2007;20:1–13.
22. Puhakka T, Mäkelä MJ, Alanen A, et al. Sinusitis in the common cold. J Allergy Clin Immunol 1998;102:403–8.
23. Brook I. The role of bacteria in chronic rhinosinusitis. Otolaryngol Clin North Am 2005;38:1171–92.
24. Hamilos DL. Chronic sinusitis. J Allergy Clin Immunol 2000;106:213–27.
25. Brook I, Thompson DH, Frazier EH. Microbiology and management of chronic maxillary sinusitis. Arch Otolaryngol Head Neck Surg 1994;120:1317–20.
26. Catten MD, Murr AH, Goldstein JA, et al. Detection of fungi in the nasal mucosa using polymerase chain reaction. Laryngoscope 2001;111:399–403.
27. Ponikau JU, Sherris DA, Kern EB, et al. The diagnosis and incidence of allergic fungal sinusitis. Mayo Clin Proc 1999;74: 877–84.
28. Babinski D, Trawinska-Bartnicka M. Rhinosinusitis in cystic fibrosis: not a simple story. Int J Pediatr Otorhinolaryngol 2008;72:619–24.
29. Benninger MS. The impact of cigarette smoking and environmental tobacco smoke on nasal and sinus disease: a review of the literature. Am J Rhinol 1999;13:435–8.
30. Houser SM, Keen KJ. The role of allergy and smoking in chronic rhinosinusitis and polyposis. Laryngoscope 2008;118:1521–7.
31. Ryan MW. Diseases associated with chronic rhinosinusitis: what is the significance? Curr Opin Otolaryngol Head Neck Surg 2008;16:231–6.
32. Baroody FM. Mucociliary transport in chronic rhinosinusitis. Clin Allergy Immunol 2007;20:103–19.
33. Stewart MG, Johnson RF. Chronic sinusitis: symptoms versus CT scan findings. Curr Opin Otolaryngol Head Neck Surg 2004;12:27–9.
34. Stankiewicz JA, Chow JM. A diagnostic dilemma for chronic rhinosinusitis: definition accuracy and validity. Am J Rhinol 2002;16:199–202.
35. Fokkens W, Lund V, Mullol J. European position paper on rhinosinusitis and nasal polyps 2007. Rhinol Suppl 2007;(20): 1–136.
36. Dinis PB, Monteiro MC, Martins ML, et al. Sinus tissue pharmacokinetics after oral administration of amoxicillin/clavulanic acid. Laryngoscope 2000;110:1050–5.
37. Hatipoglu U, Rubinstein I. Treatment of chronic rhinosinusitis with low-dose, long-term macrolide antibiotics: an evolving paradigm. Curr Allergy Asthma Rep 2005;5:491–4.
38. Faich GA, Morganroth J, Whitehouse AB, et al. Clinical experience with moxifloxacin in patients with respiratory tract infections. Ann Pharmacother 2004;38:749–54.
39. Cincik H, Ferguson BJ. The impact of endoscopic cultures on care in rhinosinusitis. Laryngoscope 2006;116:1562–8.
40. Leonard DW, Bolger WE. Topical antibiotic therapy for recalcitrant sinusitis. Laryngoscope 1999;109:668–70.
41. Lim M, Citardi MJ, Leong JL. Topical antimicrobials in the management of chronic rhinosinusitis: a systematic review. Am J Rhinol 2008;22:381–9.
42. Bhattacharyya N. Antimicrobial therapy in chronic rhinosinusitis. Curr Allergy Asthma Rep 2009;9:221–6.
43. Patel RS, Shaw SR, Wallace AM, McGarry GW. Efficacy and systemic tolerability of mometasone furoate and betamethasone sodium phosphate. J Laryngol Otol 2004;118:866–71.
44. Parikh A, Scadding GK, Darby Y, Baker RC. Topical corticosteroids in chronic rhinosinusitis: a randomized, double-blind, placebo-controlled trial using fluticasone propionate aqueous nasal spray. Rhinology 2001;39:75–9.
45. Giger R, Pasche P, Cheseaux C, et al. Comparison of once- versus twice-daily use of beclomethasone dipropionate aqueous nasal spray in the treatment of allergic and non-allergic chronic rhinosinusitis. Eur Arch Otorhinolaryngol 2003;260:135–40.
46. Lund VJ, Black JH, Szabó LZ, et al. Efficacy and tolerability of budesonide aqueous nasal spray in chronic rhinosinusitis patients. Rhinology 2004;42:57–62.
47. Harvey R, Hannan SA, Badia L, Scadding G. Nasal saline irrigations for the symptoms of chronic rhinosinusitis. Cochrane Database Syst Rev 2007;(3):CD006394.
48. Rabago D, Pasic T, Zgierska A, et al. The efficacy of hypertonic saline nasal irrigation for chronic sinonasal symptoms. Otolaryngol Head Neck Surg 2005;133:3–8.
49. Lund VJ. Maximal medical therapy for chronic rhinosinusitis. Otolaryngol Clin North Am 2005;38:1301–10, x.
50. Dubin MG, Liu C, Lin SY, Senior BA. American Rhinologic Society member survey on "maximal medical therapy" for chronic rhinosinusitis. Am J Rhinol 2007;21:483–8.
51. Subramanian HN, Schechtman KB, Hamilos DL. A retrospective analysis of treatment outcomes and time to relapse after intensive medical treatment for chronic sinusitis. Am J Rhinol 2002;16:303–12.
52. Osguthorpe JD. Surgical outcomes in rhinosinusitis: what we know. Otolaryngol Head Neck Surg 1999;120:451–3.
53. Parnes SM, Chuma AV. Acute effects of antileukotrienes on sinonasal polyposis and sinusitis. Ear Nose Throat J 2000;79: 18–20, 24–5.
54. Ragab S, Parikh A, Darby YC, Scadding GK. An open audit of

montelukast, a leukotriene receptor antagonist, in nasal polyposis associated with asthma. Clin Exp Allergy 2001;31:1385–91.
55. Scadding GK, Durham SR, Mirakian R, et al; British Society for Allergy and Clinical Immunology. BSACI guidelines for the management of rhinosinusitis and nasal polyposis. Clin Exp Allergy 2008;38:260–75.
56. Hessler JL, Piccirillo JF, Fang D, et al. Clinical outcomes of chronic rhinosinusitis in response to medical therapy: results of a prospective study. Am J Rhinol 2007;21:10–8.
57. Brook I. Bacterial infection and antibiotic treatment in chronic rhinosinusitis. Clin Allergy Immunol 2007;20:147–62.
58. Slavin RG. When should consideration be given to referring a patient with chronic rhinosinusitis to an ear, nose, and throat specialist? J Allergy Clin Immunol 2008;121:1519–20.
59. Tichenor WS, Adinoff A, Smart B, Hamilos DL. Nasal and sinus endoscopy for medical management of resistant rhinosinusitis, including postsurgical patients. J Allergy Clin Immunol 2008;121:917–27.
60. Stankiewicz JA, Chow JM. Nasal endoscopy and the definition and diagnosis of chronic rhinosinusitis. Otolaryngol Head Neck Surg 2002;126:623–7.
61. Zinreich SJ. Rhinosinusitis: radiologic diagnosis. Otolaryngol Head Neck Surg 1997;117(3 Pt 2):S27–34.
62. Lund VJ, Kennedy DW. Staging for rhinosinusitis. Otolaryngol Head Neck Surg 1997;117(3 Pt 2):S35–40.
63. Bhattacharyya N, Fried MP. The accuracy of computed tomography in the diagnosis of chronic rhinosinusitis. Laryngoscope 2003;113:125–9.
64. Benninger MS. Nasal endoscopy: its role in office diagnosis. Am J Rhinol 1997;11:177–80.
65. Devaiah AK. Adult chronic rhinosinusitis: diagnosis and dilemmas. Otolaryngol Clin North Am 2004;37:243–52, v.
66. Strong EB, Senders CW. Surgery for severe rhinosinusitis. Clin Rev Allergy Immunol 2003;25:165–76.
67. DelGaudio JM, Wise SK. Topical steroid drops for the treatment of sinus ostia stenosis in the postoperative period. Am J Rhinol 2006;20:563–7.
68. Jiang RS, Liang KL, Yang KY, et al. Postoperative antibiotic care after functional endoscopic sinus surgery. Am J Rhinol 2008;22:608–12.
69. Senior BA, Kennedy DW, Tanabodee J, et al. Long-term results of functional endoscopic sinus surgery. Laryngoscope 1998;108:151–7.
70. Bhattacharyya N. Clinical outcomes after endoscopic sinus surgery. Curr Opin Allergy Clin Immunol 2006;6:167–71.
71. Smith TL, Batra PS, Seiden AM, Hannley M. Evidence supporting endoscopic sinus surgery in the management of adult chronic rhinosinusitis: a systematic review. Am J Rhinol 2005; 19:537–43.
72. Sautter NB, Mace J, Chester AC, Smith TL. The effects of endoscopic sinus surgery on level of fatigue in patients with chronic rhinosinusitis. Am J Rhinol 2008;22:420–6.
73. McMains KC, Kountakis SE. Revision functional endoscopic sinus surgery: objective and subjective surgical outcomes. Am J Rhinol 2005;19:344–7.
74. Kennedy DW. Prognostic factors, outcomes and staging in ethmoid sinus surgery. Laryngoscope 1992;102(12 Pt 2 Suppl 57): 1–18.

Copyright 2009 by Turner White Communications Inc., Wayne, PA. All rights reserved.

JCOM CME WAYNE STATE UNIVERSITY

CME EVALUATION: Evaluation and Management of Adult Chronic Rhinosinusitis

DIRECTIONS: Each of the questions below is followed by several possible answers. Select the ONE lettered answer that is BEST in each case and circle the corresponding letter on the answer sheet.

1. Healthy sinus function depends on all of the following EXCEPT
   A. Patency of the sinus ostia
   B. Intact ciliary function
   C. Absence of fungi in the nasal cavity
   D. Regulated mucous consistency

2. The treatment of chronic rhinosinusitis (CRS) involves several different modalities, both medical and surgical. What is the primary goal of treatment?
   A. Complete eradication of sinus and nasal microbes
   B. Restoration of mucociliary flow and ostial patency
   C Symptomatic relief for comfort measures
   D. To avoid the use of antibiotics due to fears of developing resistance

3. Which of the following statements is FALSE?
   A. It is believed that the inflammatory response to microbes is more pathogenic than the action of the microbes themselves
   B. Current guidelines mandate rhinoscopic, endoscopic, or radiographic evidence to make a true diagnosis of CRS
   C. Endoscopy is an ideal screening tool due to the extremely high sensitivity
   D. The use of systemic steroids in initial management is preferred to topical steroids because of the ease of administration

4. A 45-year-old man presents with nasal obstruction, sinus pressure, and purulent drainage for 4 months. Symptoms are markedly worse on the left side. He undergoes 1 month of oral antibiotics and topical steroids but the symptoms are only minimally improved. What should be the next step in management?
   A. Referral to a specialist for evaluation due to the nature of the symptoms and failure of medical therapy
   B. A repeat course of oral antibiotics
   C. Addition of treatment modalities such as sinus irrigation and decongestants
   D. Outpatient testing to evaluate for concurrent allergic disease

5. Which of the following statements regarding functional endoscopic sinus surgery (FESS) is TRUE?
   A. FESS allows sinus drainage to bypass natural drainage pathways
   B. FESS is indicated after the failure of medical management
   C. A finding of polyposis is an indication for immediate surgical intervention
   D. FESS is restricted to patients who develop complications of CRS

WAYNE STATE UNIVERSITY JCOM CME

EVALUATION FORM: Evaluation and Management of Adult Chronic Rhinosinusitis

Participants may earn 1 credit by reading the article named above and correctly answering at least 70% of the accompanying test questions. A certificate of credit and the correct answers will be mailed within 6 weeks of receipt of this page to those who successfully complete the test.

Circle your answer to the CME questions below:

1.	A	B	C	D
2.	A	B	C	D
3.	A	B	C	D
4.	A	B	C	D
5.	A	B	C	D

Please answer the following questions:

1. How would you rate this educational activity overall?
   __ Excellent __ Good __ Fair __ Poor

2. This article was fair, balanced, free of commercial bias, and fully supported by scientific evidence.
   __ Yes __ No

3. Please rate the clarity of the material presented in the article.
   __ Very clear __ Somewhat clear __ Not at all clear

4. How helpful to your clinical practice was this article?
   __ Very helpful __ Somewhat helpful __ Not at all helpful

5. What changes will you make in your practice as a result of reading this article?
   _____
   _____
   _____
   _____
   _____
   _____

6. What topics would you like to see presented in the future?
   _____
   _____
   _____
   _____
   _____
   _____

Release date: 15 July 2009
Expiration date: 30 July 2010

Please print clearly:

Name: _____

MD/DO/Other: _____

Address: _____

_____

City: _____

State: _____ Zip: _____

Phone: _____

Fax: _____

E-mail: _____

Are you a health care professional licensed to practice in the US/Canada who can use Category 1 AMA PRA CME credit to fulfill educational requirements? ____ Yes ____ No

Physicians are required to report the actual amount of time spent on the activity, up to the maximum designated 1 hour. The actual time spent reading this article and completing the test was _____.

Please mail or fax this sheet to:

Wayne State University, Division of CME
101 E. Alexandrine, Lower Level
Detroit, MI 48201
FAX: 313-577-7554

This activity has been planned and implemented in accordance with the Essential Areas and Policies of the Accreditation Council for Continuing Medical Education (ACCME) through the joint sponsorship of Wayne State University School of Medicine and the *Journal of Clinical Outcomes Management.* Wayne State University School of Medicine is accredited by the ACCME to provide continuing medical education for physicians.

Wayne State University School of Medicine designates this educational activity for a maximum of 1 AMA PRA Category 1 credits. Physicians should only claim credit commensurate with the extent of their participation in the activity.