A Probable Case of Clarithromycin-Digoxin Interaction and Life-Threatening Arrhythmia

Melody Milliron, DO
Daniel Myers, MD

Digoxin is a useful adjunctive medication in the treatment of congestive heart failure and atrial fibrillation.[1] However, it has a narrow therapeutic index and multiple, well-known drug interactions.[2] Erythromycin-digoxin interaction has been reported in many case reports,[3–5] but clarithromycin-induced digoxin toxicity is less well recognized. Digoxin toxicity can result in life-threatening arrhythmias, including ventricular tachycardia, sinoatrial node arrest, and third-degree heart block.[2] Review of Index Medicus did not show any lethal cases of clarithromycin-digoxin toxicity. This report describes a case of life-threatening arrhythmia that may have been caused by clarithromycin-digoxin interaction.

CASE PRESENTATION

Initial Presentation and History

An 84-year-old man was brought to the emergency department by paramedics after he experienced a syncopal event at his home. The paramedics reported that the patient was found in ventricular tachycardia, which resolved with a precordial thump. Upon arrival, the patient complained of generalized weakness. Four days previously, he had been admitted to another facility for treatment of a urinary tract infection and bronchitis. He was discharged from this facility 1 day later on clarithromycin (500 mg twice daily). His medical history was notable for hypertension, aortic stenosis, congestive heart failure, type 2 diabetes mellitus, remote atrial fibrillation, and transient ischemic attack 5 years prior.

The patient denied tobacco, alcohol, or herbal supplement use. In addition to clarithromycin, his medications included digoxin (0.25 mg daily), nifedipine (60 mg daily), and glipizide (10 mg twice daily). No other alterations in his medication regimen had been made.

Physical Examination

On examination, the patient was alert and responded appropriately to questioning. The patient's initial vital signs were as follows: blood pressure, 121/47 mm Hg; heart rate, 60 bpm; and respiratory rate, 16 breaths/min. Cardiovascular examination revealed a 3/6 systolic ejection murmur at the right upper sternal border consistent with aortic stenosis. Respiratory system examination was remarkable for crackles at the right base; however, the left lung was clear on auscultation. Abdominal, musculoskeletal, and neurologic examinations were unremarkable. The patient's skin was warm and dry with good turgor; diaphoresis was not present.

Diagnostic Studies

The basic metabolic panel revealed multiple significant findings that included: potassium, 6.2 mEq/L (normal, 3.5–5.0 mEq/L); blood urea nitrogen, 119 mg/dL (normal, 8–23 mg/dL); serum creatinine, 3.5 mg/dL (normal, 0.6–1.2 mg/dL); bicarbonate, 18 mEq/L (normal, 21–28 mEq/L); and glucose, 559 mg/dL (normal, 70–110 mg/dL). The digoxin level was markedly elevated at 5.7 ng/mL (normal range, 0.8–2.0 ng/mL). Initial electrocardiogram showed an irregular rhythm, heart rate of 68 bpm, and diffuse anterior and lateral ST-interval and T wave changes (**Figure 1**). Results of a portable chest radiograph were consistent with early congestive heart failure.

Treatment and Outcome

The patient was treated with 4 aspirin (81 mg/tablet) and a nitroglycerin drip (5 μg/min). Twenty-five minutes after the initial evaluation, the patient was noted to have a blank stare; the monitor revealed asystole. An attempt was immediately made to pace the patient; however, the pacing attempt was unsuccessful. His ventilation was assisted with a bag valve mask. He was treated with epinephrine and atropine (1 mg each) by intravenous (IV) bolus. In less than 60 seconds, the patient returned to spontaneous rhythm and respirations. He complained of some dizziness. Repeat electrocardiogram showed an irregular rhythm with Q waves in V_1 and V_2, right bundle-branch block and diffuse ST-segment and T wave abnormalities (**Figure 2**). Laboratory testing of blood drawn

Dr. Milliron is an emergency medicine resident and Dr. Meyers is a faculty attending physician at Saint Vincent Health Center, Erie, PA.

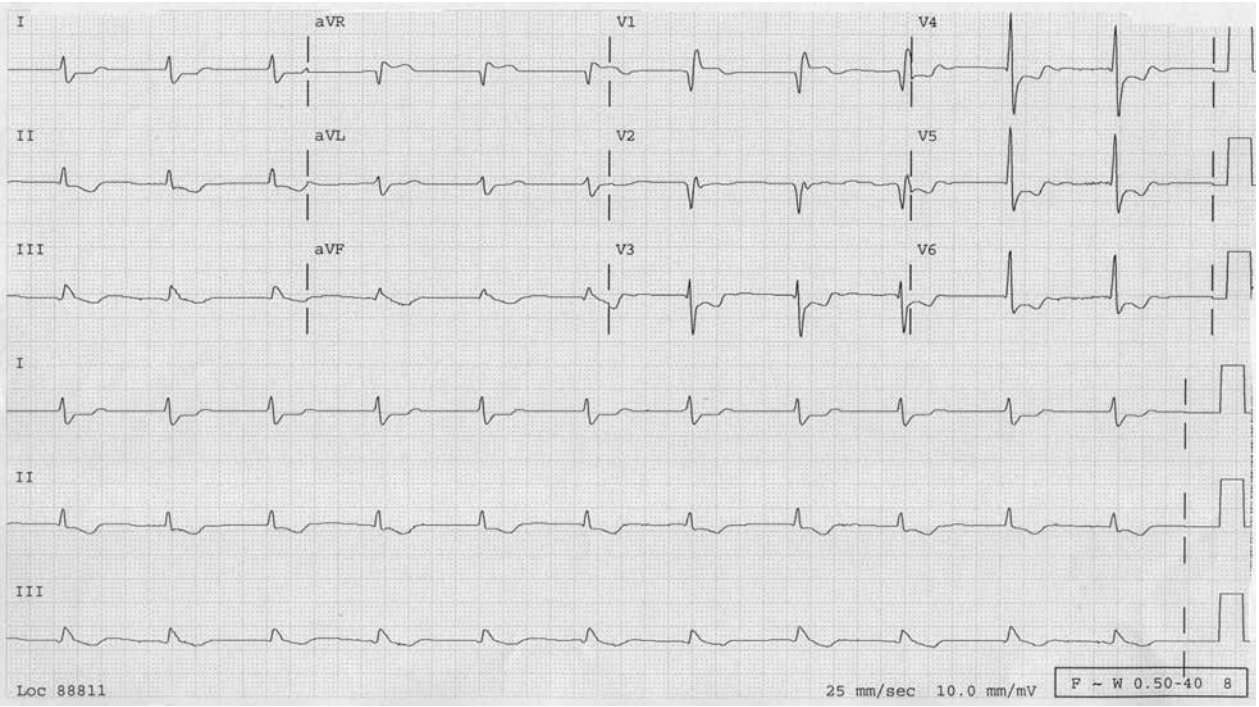

Figure 1. An electrocardiogram taken during the initial work-up of the case patient showing an irregular rhythm, with a heart rate of 68 bpm and diffuse anterior and lateral ST interval and T wave changes.

shortly after asystole was negative for increased cardiac enzymes. The white blood cell count was $17.2 \times 10^3/\mu L$ (normal, $4.5–11.0 \times 10^3/\mu L$) and the hemoglobin level was 11.0 g/dL (normal, 14.0–17.5 g/dL). Values for arterial blood gases were as follows: P_{CO_2}, 26 mm Hg (normal, 35–45 mm Hg); P_{O_2}, 69 mm Hg (normal, 80–100 mm Hg); HCO_3, 14.0 mEq/L (normal, 21–28 mEq/L); and pH, 7.34 (normal, 7.35–7.45).

The provisional diagnoses of asystolic arrest secondary to digoxin toxicity, hyperkalemia, acute renal failure, and hyperglycemia were made. A cardiology consultation was requested. The patient was treated with digoxin-specific Fab fragment (d-Fab). He was also treated with sodium bicarbonate (1 amp IV), insulin (5 units IV), and sodium polystyrene (15 g orally) for his hyperkalemia. The patient's heart returned to sinus rhythm, and the patient was admitted to a cardiac care unit.

Both digoxin and clarithromycin were discontinued. Due to the patient's history of recent infection and elevated white blood cell count, he was started on ceftriaxone (1 g IV daily) and clindamycin (600 mg IV every 8 hours). Blood and urine cultures were negative throughout his hospital course. During inpatient evaluation, outside record review revealed a serum creatinine level of 1.0 mg/dL 1 week prior to presentation. The patient's wife also stated his oral intake had been decreased in the preceding several days. His renal failure was medically managed and improved without hemodialysis. His cardiac enzymes remained negative throughout his stay. He was discharged 6 days later in good condition on nifedipine (60 mg daily) and glipizide (10 mg twice daily). Digoxin (0.125 mg daily) was resumed with close follow-up.

DISCUSSION

According to the Adverse Drug Reaction probability scale (**Figure 3**), this case represents a probable interaction between digoxin and clarithromycin. Other significant contributing factors to the patient's condition include renal dysfunction, possibly related to dehydration, which may have lead to digoxin accumulation.[6] His age and preexisting diabetes mellitus may have also placed him at an increased risk for renal failure. Renal excretion of digoxin occurs in an exponential fashion and is proportional to the glomerular filtration rate.[2] In the patient with abnormal renal function, digoxin's typical half-life of 36 to 48 hours may be prolonged.[2] Renal clearance of digoxin accounts for approximately 80% of total digoxin clearance.[7] Therefore, this patient's renal failure may have significantly contributed to his digoxin toxicity.

Other medication interactions must also be considered. Clarithromycin alone may prolong the QTc

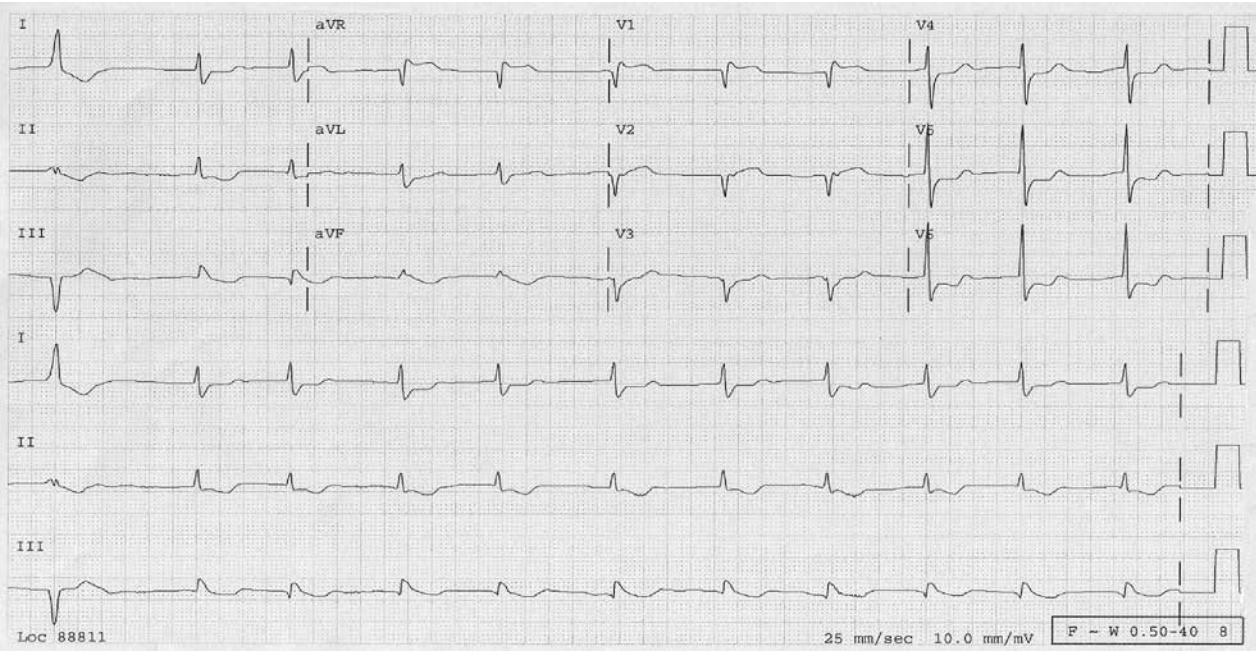

Figure 2. An electrocardiogram taken after the case patient was treated for asystole showing an irregular rhythm with Q waves in V_1 and V_2, right bundle-branch block, and diffuse ST-segment and T wave abnormalities.

segment.[8–10] Nifedipine, a calcium channel blocker, may cause bradycardia in overdose.[11] However, it seems unlikely that nifedipine was the causative agent as the patient did not present with hypotension, bradycardia, or anion gap metabolic acidosis. In addition, he responded appropriately without treatment for calcium channel blocker toxicity. Nifedipine may also cause renal insufficiency, although only 2% of patients developed renal insufficiency in a recent study of hypertensive patients treated with nifedipine.[12] It is less likely that our patient developed renal failure from his long-term nifedipine use, thereby causing toxic digoxin accumulation. Hypotension may also be caused by nitroglycerin administration[13]; the timing in this case, however, makes this a less likely scenario.

Although we cannot definitively state that this patient's life-threatening arrhythmia was solely due to a clarithromycin-digoxin interaction, this case affords the opportunity to examine this underreported entity. The following sections discuss digoxin toxicity and clarithromycin-induced digoxin toxicity as well as review the presentation and treatment of patients with acute digoxin toxicity.

Digoxin: Mechanism of Action

Digoxin, a cardiac glycoside derived from the foxglove plant, has been used to treat congestive heart failure since its discovery in 1785.[2] Digoxin has 3 main actions.[2] First, digoxin inactivates the sodium/potassium cation pump, which normally exchanges extracellular potassium for intracellular sodium.[14] When this pump is inhibited, intracellular sodium increases, thereby increasing reliance on the sodium-calcium exchange pump to maintain membrane potential.[2] As a result of this exchange, intracellular calcium levels rise, thereby increasing the force of cardiac contraction but also increasing the risk of delayed after-depolarization and dysrhythmia.[14] Digoxin's second action, positive inotropic activity, comes at the cost of a higher level of extracellular potassium, which is commonly seen in acute digoxin toxicity.[14] Finally, digoxin increases vagal tone, which decreases atrioventricular nodal conduction, thus increasing the risk of bradydysrhythmia.[14]

Causes of Digoxin Toxicity

The risk for digoxin toxicity is increased in patients with acute myocardial infarction, renal dysfunction, hepatic disease, hypothyroidism, chronic obstructive pulmonary disease, and electrolyte abnormalities, such as hypokalemia, hypomagnesemia, and hypercalcemia.[6] An event that sensitizes myocardial cells or causes metabolic or electrolyte abnormalities may predispose to digoxin toxicity.[14] Various drugs also play a role in digoxin toxicity. Diuretics may cause hypokalemia, thereby enhancing digoxin's pharmacologic effects. Quinidine, verapamil, and amiodarone decrease renal

ADR Probability Scale

To assess the adverse drug reaction, please answer the following and give the pertinent score.

	Yes	No	Do not know	Score
1. Are there previous conclusive reports on the reaction?	+1	0	0	+1
2. Did the adverse event appear after the suspected drug was administered?	+2	–1	0	+2
3. Did the adverse reaction improve when the drug was discontinued or a specific antagonist was administered?	+1	0	0	+1
4. Did the adverse reaction reappear when the drug was readministered?	+2	–1	0	0
5. Are there alternative causes (other than the drug) that could on their own have caused the reaction?	–1	+2	0	–1
6. Did the reaction reappear when a placebo was given?	–1	–1	0	0
7. Was the drug detected in the blood (or other fluids) in concentrations known to be toxic?	+1	0	0	+1
8. Was the reaction more severe when the dose was increased, or less severe when the dose was decreased?	+1	0	0	0
9. Did the patient have a similar reaction to the same or similar drugs in any previous exposure?	+1	0	0	0
10. Was the adverse event confirmed by any objective evidence?	+1	0	0	+1
				5

Key

Total score ≥ 9 Highly probable ____ Total score = 0 Possible _____

Total score = 5–8 Probable X Total score ≥ 0 Doubtful _____

Pharmacist completing report: _____ Date _____

Figure 3. Adverse Drug Reaction (ADR) probability scale. This form was used to determine that the case patient had a probable adverse drug interaction between clarithromycin and digoxin. (Adapted from Naranjo CA, Busto U, Sellers EM, et al. A method for estimating the probability of adverse drug reactions. Clin Pharmacol Ther 1981:30:239–45. Copyright 1981, with permission from the American Society of Clinical Pharmacology and Therapeutics.)

clearance of digoxin clearance, thus increasing digoxin's half-life.[6] Finally, certain drugs increase both oral availability and intestinal absorption of digoxin, namely clarithromycin, quinidine, amiodarone, itraconazole, verapamil, cyclosporine, propafenone, and spironolactone.[7,15]

Clarithromycin-Induced Digoxin Toxicity

Macrolide antibiotics, including clarithromycin, are frequently used as outpatient therapy for respiratory tract infections. Clarithromycin is a semisynthetic macrolide that has been modified to be more effective against a broader range of organisms with fewer side effects than other antibiotics and to be administered twice daily.[16] Clarithromycin extensively diffuses into saliva, sputum, lung tissues, tonsils, nasal mucosa, and the middle ear.[16] Rapid penetration of neutrophils and alveolar macrophages allow for high intracellular concentrations.[16] Clarithromycin is metabolized into at least 8 active metabolites. Cytochrome P450 (CYP3A) is the major hepatic microsomal pathway of hydroxylation and oxidative *N*-demethylation. Excretion is renal, and dose adjustments are recommended in patients with severe renal impairment (creatinine clearance < 1.8 mL/min).[16]

The digoxin-macrolide interaction, however, is believed to occur primarily due to P-glycoprotein inhibition and alterations in gastrointestinal flora.[1] The involvement of CYP3A in digoxin metabolism has been shown in rats, although this role is less clear in humans.[17] Digoxin undergoes primarily renal excretion, including tubular secretion, reabsorption, and glomerular filtration.[18] Digoxin is transported by P-glycoprotein, an adenosine triphosphate–dependent export glycoprotein found on the surface of renal tubular epithelia and the apical membrane of intestinal cells.[7,18] Inhibition of P-glycoprotein–mediated transport by drugs such as macrolides causes a reduction in active renal tubular secretion and a net increase in intestinal resorption of digoxin.[7,15,19] The main role of P-glycoprotein in the digoxin-macrolide interaction appears to be a modulation of absorption across intestinal mucosa.[20] Wakasugi et al[18] showed that digoxin transport by P-glycoprotein

from the basolateral to the apical side of the cell was inhibited by clarithromycin, while cellular accumulation of digoxin increased on both sides of the cell.[18] In addition, gastrointestinal flora metabolize digoxin into digoxin-related products (DRPs), which are less cardioactive than digoxin.[1,2,20] *Eubacterium lentum*, an anaerobic bacillus, is responsible for formation of DRPs.[17] Of the macrolides, clarithromycin is the most active against *E. lentum*.[21] Administration of clarithromycin reduces the population of *E. lentum*, which decreases the conversion of digoxin to DRPs, thus increasing the bioavailability of digoxin.[20] While two thirds of the population excretes less than 5% of a digoxin dose as DRPs, 10% of the population converts up to 40% of a digoxin dose to DRPs.[18] This population is at an increased risk for developing toxic digoxin levels when gastrointestinal flora are altered by antibiotic use.[1]

Clarithromycin-induced digoxin toxicity is not widely reported in the literature; however, several studies are available that provide insights into this syndrome. A retrospective Canadian review of more than 1000 patients with digoxin toxicity revealed that patients who had taken clarithromycin during the previous week were 12 times more likely to develop toxicity than those patients who did not take clarithromycin.[22] A Japanese study of 8 hospitalized patients showed that digoxin concentrations were on average 70% higher in patients treated with clarithromycin when given their usual digoxin dose.[15] A prospective observational Spanish study showed digoxin levels were higher in all 7 patients who were prescribed a 5- to 7-day regimen of oral clarithromycin concurrent with digoxin therapy.[19] Elevated digoxin levels, lower clearance rates, and increased digoxin half-life occurred in all patients.[19] However, only 1 patient who had reduced renal function developed signs of digoxin toxicity.[23] These studies suggest that concurrent use of digoxin and clarithromycin elevates digoxin levels.

Clinical Presentation

Both acute and chronic digoxin toxicity typically present with nausea and/or vomiting, headache, visual changes (possibly halo and/or blue-green vision), confusion, and arrhythmia. However, anorexia, malaise, possible seizure, hypokalemia or eukalemia, and normal or only moderately elevated serum digoxin levels are more typical of chronic toxicity, whereas patients with acute digoxin toxicity present with elevated digoxin levels and hyperkalemia.[6,14]

Treatment of Acute Digoxin Toxicity

In addition to basic life support measures, acute digoxin overdose should be treated with 1 g/kg of charcoal. Symptomatic bradycardia should be initially treated with atropine and cardiac pacing until definitive therapy with d-Fab is available.[2] d-Fab is an antibody that binds and inactivates digoxin and can rapidly reverse toxicity of life-threatening arrhythmias within minutes[24]; indications for its use are listed in the **Table**. However, treatment with d-Fab has risks, including hypokalemia, exacerbation of congestive heart failure, and impaired renal function.[24] In addition, digoxin levels may rebound in 12 to 24 hours as d-Fab undergoes renal clearance.[25] Renal failure/impairment decreases d-Fab clearance by 75% and may lengthen this possible rebound phase from 12 to 130 hours after therapy is initiated.[25] Hemodialysis is ineffective for digoxin removal.[2] Some practitioners consider phenytoin the antidysrhythmic of choice due to its ability to accelerate atrioventricular nodal conduction. However, class IA antidysrhythmics, such as procainamide and quinidine, are contraindicated as they depress atrioventricular nodal conduction.[14] Avoidance of defibrillation is also essential because it increases the risk of refractory ventricular fibrillation.[14] Digoxin-induced hyperkalemia should be treated with insulin and dextrose, sodium bicarbonate, and sodium polystyrene if the serum potassium level is less then 5 mEq/L.[24] d-Fab is indicated as sole therapy for levels greater than 5 mEq/L.[24] Treatment of this patient's hyperkalemia with typical agents, such as calcium chloride or calcium gluconate, may have promoted cardiac toxicity.[14]

Table. Indications for Use of Digoxin-Specific Fab Fragments in Patients with Suspected Digoxin Toxicity

History of large ingestion of digoxin accompanied by elevated digoxin levels
Early use in patients older than 55 years or who have cardiovascular disease
Shock
Hyperkalemia (serum level > 5 mEql/L)
Cardiac arrhythmias: heart block or ventricular arrhythmia

Adapted with permission from Flanagan RJ, Jones AL. Fab antibody fragments: some applications in clinical toxicology. Drug Saf 2004;27: 1119.

CONCLUSION

Physicians must recognize that digoxin metabolism and excretion is altered in patients with renal insufficiency, that digoxin toxicity may be exacerbated by certain antibiotics such as clarithromycin, and that gastrointestinal symptoms that are typical of adverse antibiotic events may also be symptoms of digoxin

toxicity. The significance of digoxin-clarithromycin interaction is becoming increasingly evident. In this patient, there were several options to prevent toxicity. First, this interaction could have been entirely avoided by selection of a different class of antibiotic. Alternative antibiotics for this patient include trimethoprim/sulfamethoxazole or a second- or third-generation cephalosporin.[14] If clarithromycin was still chosen, the digoxin dose should have been decreased and serum digoxin levels closely monitored. Digoxin could also have been administered intravenously, thus bypassing the gastrointestinal tract. Tsutsumi et al[20] found no change in digoxin level after co-administration with erythromycin or clarithromycin when digoxin was administered intravenously. Finally, avoidance of digoxin as an agent may also have been an option. HP

ACKNOWLEDGMENT

The authors acknowledge Phyllis J. Kuhn, PhD, Lake Erie Research Institute, Erie, PA, and Andrew Grimone, PharmD, Saint Vincent Health Center, Erie, PA, for their helpful review and comments.

REFERENCES

1. Bizjak ED, Mauro VF. Digoxin-macrolide drug interaction. Ann Pharmacother 1997;31:1077–9.
2. Hauptmann PJ, Kelly RA. Digitalis. Circulation 1999;99:1265–70.
3. Friedman HS, Bonventre MV. Erythromycin-induced digoxin toxicity. Chest 1982;82:202.
4. Morton MR, Cooper JW. Erythromycin-induced digoxin toxicity. DICP 1989;23:668–70.
5. Sutton A, Pilot MA. Digoxin toxicity and erythromycin. BMJ 1989;298:1101.
6. Nordt SP, Williams SR, Manoguerra AS, Clark RF. Clarithromycin induced digoxin toxicity. J Accid Emerg Med 1998;15:194–5.
7. Rengelshausen J, Goggelmann C, Burhenne J, et al. Contribution of increased oral bioavailability and reduced nonglomerular renal clearance of digoxin to the digoxin-clarithromycin interaction. Br J Clin Pharmacol 2003;56:32–8.
8. Iannini PB. Cardiotoxicity of macrolides, ketolides and fluoroquinolones that prolong the QTc interval. Expert Opin Drug Saf 2002;1:121–8.
9. Lee KL, Jim MH, Tang SC, et al. QT prolongation and torsades de pointes associated with clarithromycin. Am J Med 1998;104:395–6.
10. Volberg WA, Koci BJ, Su W, et al. Blockade of human cardiac potassium channel human ether-a-go-go-related gene (HERG) by macrolide antibiotics. J Pharmacol Exp Ther 2002;302:320–7.
11. Heard K, Kline JA. Calcium channel blockers. Tintinalli JE, Kelen GB, Stapczynski JS, editors. Emergency medicine: a comprehensive study guide. 6th ed. New York: McGraw-Hill; 2004:1023, 1109–11.
12. de Leeuw PW, Ruilope LM, Palmer CR, et al. Clinical significance of renal function in hypertensive patients at high risk: results from INSIGHT trial. Arch Intern Med. 2004;164:2459–64.
13. Clements EA, Kuhn BR. Pharmacology of antidysrhythmic and vasoactive medication. Tintinalli JE, Kelen GB, Stapczynski JS, editors. Emergency medicine: a comprehensive study guide. 6th ed. New York: McGraw-Hill; 2004:215–6, 1023.
14. Dribben W, Kirk MA. Digitalis glycosides. Tintinalli JE, Kelen GB, Stapczynski JS, editors. Emergency medicine: a comprehensive study guide. 6th ed. New York: McGraw-Hill; 2004:1023, 1102–5.
15. Tanaka H, Matsumoto K, Ueno K, et al. Effect of clarithromycin on steady-state digoxin concentrations. Ann Pharmacother 2003;37:178–81.
16. Rodvold KA. Clinical pharmacokinetics of clarithromycin. Clin Pharmacokinet 1999;37:385–98.
17. Xu H, Rashkow A. Clarithromycin-induced digoxin toxicity: a case report and a review of the literature. Conn Med 2001;65:527–9.
18. Wakasugi H, Yano I, Ito T, et al. Effect of clarithromycin on renal excretion of digoxin: interaction with P-glycoprotein. Clin Pharmacol Ther 1998;64:123–8.
19. Zapater P, Reus S, Tello A, et al. A prospective study of the clarithromycin-digoxin interaction in elderly patients. J Antimicrob Chemother 2002;50:601–6.
20. Tsutsumi K, Kotegawa T, Kuranari M, et al. The effect of erythromycin and clarithromycin on the pharmacokinetics of intravenous digoxin in healthy volunteers. J Clin Pharmacol 2002;42:1159–64.
21. Guerriero SE, Ehrenpreis E, Gallagher KL. Two cases of clarithromycin-induced digoxin toxicity. Pharmacotherapy 1997;17:1035–7.
22. Juurlink DN, Mamdani M, Kopp A, et al. Drug-drug interactions among elderly patients hospitalized for drug toxicity. JAMA 2003;289:1652–8.
23. Laberge P, Martineau P. Clarithromycin-induced digoxin interaction. Ann Pharmacother 1997;31:999–1002.
24. Flanagan RJ, Jones AL. Fab antibody fragments: some applications in clinical toxicology. Drug Saf 2004;27:1115–33.
25. Mehta RN, Mehta NJ, Gulati A. Late rebound digoxin toxicity after digoxin-specific antibody Fab fragments therapy in anuric patient. J Emerg Med 2002;22:203–6.

Copyright 2006 by Turner White Communications Inc., Wayne, PA. All rights reserved.