Community-Acquired Methicillin-Resistant *Staphylococcus aureus* Necrotizing Pneumonia: A Report of Three Cases

Saqib I. Hasan, MD
Elizabeth B. Hale, MD

Community-acquired methicillin-resistant *Staphylococcus aureus* (CA-MRSA) has received considerable attention in recent years as the cause of infections among individuals in the community who do not have traditional risk factors for MRSA infections such as hospitalization or extensive contact with the medical system. Recently, CA-MRSA has been implicated as the agent responsible for necrotizing hemorrhagic pneumonia associated with high morbidity and mortality in young immunocompent patients from North America.[1–5] Although MRSA remains a rare cause of community-acquired pneumonia (CAP), its incidence has been increasing in the last several years.[1–5] This article presents 3 cases of necrotizing pneumonia caused by CA-MRSA in otherwise healthy adults. A review of the clinical features and approach to diagnosing and managing MRSA CAP is also provided.

CASE PRESENTATIONS

Case 1

In September 2004, a 49-year-old man was brought to the emergency department (ED) with right-sided pleuritic chest pain, cough, hemoptysis, fever, and chills after a brief incarceration. These symptoms were preceded by nasal congestion and the development of a furuncle over the right cheek for 4 to 5 days. The patient's medical history was significant for current use of tobacco and inhaled cocaine but no intravenous (IV) drug abuse. He had negative purified protein derivative (PPD) of tuberculin and HIV tests during an imprisonment 1 year earlier.

At the time of presentation, the patient had a temperature of 102.6°F, heart rate of 133 bpm, respiratory rate of 30 breaths/min, blood pressure of 125/62 mm Hg, and oxygen saturation on room air of 90%. On auscultation, crackles were heard over the right lung base. A healing furuncle was noted on the patient's right cheek. Laboratory studies, including electrolytes, renal function tests, and complete blood count, were remarkable for a white blood cell (WBC) count of 20,900 cells/µL (normal, 4500–11,000 cells/µL). Initial chest radiograph showed patchy infiltrates in the right lower lobe.

The patient was admitted to the hospital, moxifloxacin (400 mg/day IV) was started, and sputum and blood cultures were obtained. By hospital day 4, a sputum sample and 2 blood cultures were reported to be growing MRSA. The antibiotic susceptibilities for these organisms are listed in the **Table**. A follow-up chest radiograph taken on hospital day 4 revealed cavitary pneumonia in the right lower lobe and bilateral small pleural effusions. Based on initial culture results, treatment with vancomycin (1 g IV every 12 hr) was started on hospital day 4, and moxifloxacin was discontinued. Repeat blood cultures drawn on hospital day 4 were negative. Because blood cultures for MRSA were positive, a transthoracic echocardiogram was performed, which revealed no vegetations. The patient had prompt improvement in his clinical as well as radiologic picture. Thus, the diagnosis of endocarditis was felt to be highly unlikely. On hospital day 9, the patient left against medical advice for a court appearance. As a result, the patient was switched from IV vancomycin to oral linezolid (600 mg twice daily) for an additional 8 days and was discharged. At 6-weeks' follow-up, the patient was doing well.

Case 2

A previously healthy 18-year-old man presented to the ED in May 2005 with severe stabbing pain in the right upper chest that had been preceded by cough with greenish-brown sputum and intermittent fevers for

Dr. Hasan is an assistant professor of medicine, Michigan State University College of Human Medicine, Flint, MI; and an assistant director of infectious diseases, Hurley Medical Center, Flint, MI. Dr. Hale is a clinical associate professor of medicine, Michigan State University, Lansing, MI; and an associate director of infectious diseases, Hurley Medical Center.

Table. Antibiotic Susceptibilities for the Case Patients

	Case 1	Case 2	Case 3
Oxacillin	Resistant	Resistant	Resistant
TMP-SMX	Susceptible	Not tested	Susceptible
Gentamicin	Susceptible	Susceptible	Susceptible
Erythromycin	Resistant	Resistant	Resistant
Clindamycin (by D test)	Not tested	Susceptible	Susceptible
Vancomycin	Susceptible	Susceptible	Susceptible
Ciprofloxacin	Susceptible	Susceptible	Resistant
Moxifloxacin	Not tested	Not tested	Susceptible
Rifampin	Susceptible	Susceptible	Susceptible
Tetracycline	Susceptible	Susceptible	Susceptible
Linezolid	Susceptible	Not tested	Susceptible

TMP-SMX = trimethoprim-sulfamethoxazole.

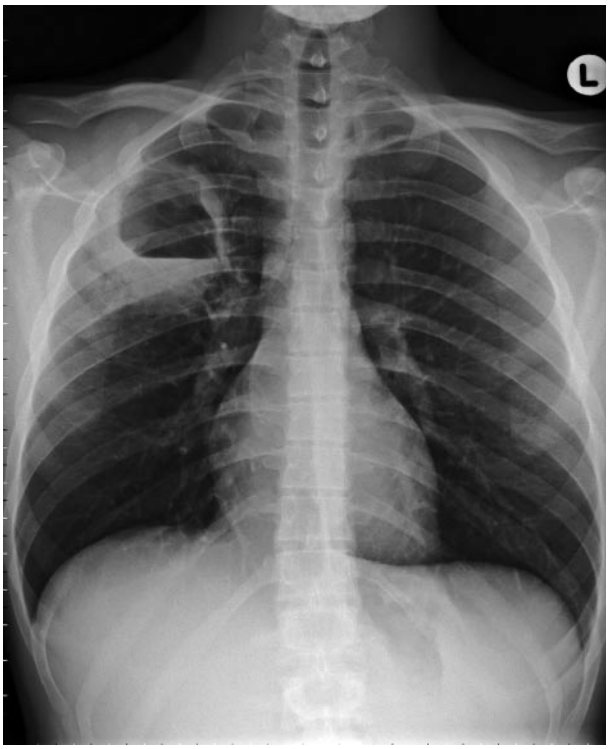

Figure 1. Chest radiograph taken of case patient 2 showing a large pneumatocele with an air-fluid level in right upper lobe of the lungs.

2 weeks. He had undergone incision and drainage of a right external ear abscess approximately 1 month prior to this illness; cultures were not obtained at that time. The patient was prescribed a 2-week course of oral amoxicillin-clavulanate to treat the infection associated with the abscess. He had a history of current tobacco use, but no history of tuberculosis exposure, imprisonment, loss of consciousness, or weight loss. On physical examination, the patient's temperature was 101.1°F and oxygen saturation on room air was 97%. Routine laboratory studies were ordered, which revealed an elevated WBC count of 19,800 cells/μL. Chest radiograph showed an 8 × 7-cm cavitary lesion with an air-fluid level in the right upper lobe (**Figure 1**).

The patient was admitted and placed in airborne isolation. Clindamycin (600 mg every 8 hr) was begun intravenously. The patient reported mild hemoptysis during initial hospitalization, but tuberculosis was ruled out with 3 negative acid-fast bacillus smears. A PPD test also was nonreactive. Blood cultures taken at admission were negative. Gram stain of the sputum revealed a few WBCs and a few gram-positive cocci. By hospital day 4, cultures of sputum samples grew MRSA, which was susceptible to clindamycin with a negative D-test (Table). The patient defervesced on hospital day 3, and a follow-up chest radiograph before discharge showed decrease in size of the cavitary infiltrate and resolution of the fluid level. He was discharged on hospital day 9 with instructions to continue taking oral clindamycin (450 mg 3 times daily) for 2 more weeks.

Case 3

A previously healthy 27-year-old man presented to the ED in September 2006 with a 2-day history of cough, hemoptysis, fever, and increasingly severe right-sided pleuritic chest pain. He also reported having a "boil" on his buttock that had been present for approximately 1 week prior to the onset of the illness. With the exception of current tobacco use, the patient had no significant past medical history. On physical examination, the patient had a temperature of 101.3°F, blood pressure of 130/76 mm Hg, heart rate of 107 bpm, respiratory rate of 18 breaths/min, and oxygen saturation on room air

Figure 2. Chest radiograph showing right upper lobe pneumonia with cavitation in case patient 3.

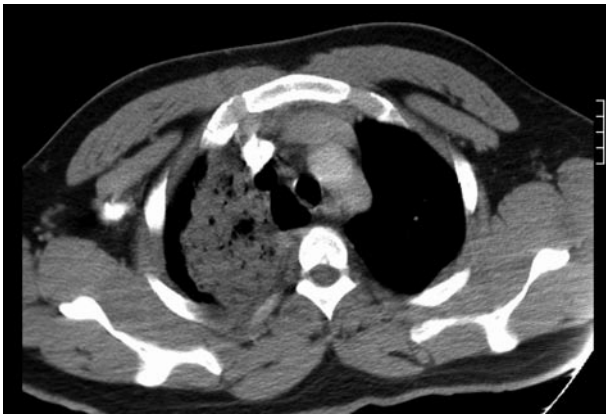

Figure 3. Chest computed tomography scan taken of patient 3 demonstrating necrotizing pneumonia involving the right upper lobe of the lung.

of 95%. Crackles were present over the right upper lung field, and a furuncle with purulent drainage was present on the right buttock, which was swabbed for a culture sample. Blood and sputum samples were also sent to the laboratory. Routine laboratory studies were ordered, which revealed an elevated WBC count of 32,200 cells/μL. Chest radiograph showed right upper lobe consolidation with cavitary changes that were suggestive of a necrotizing process (**Figure 2**). Computed tomography of the chest also showed right upper lobe consolidation with several cavities (**Figure 3**). Sputum Gram stain was reported to show a few WBCs and a few gram-positive cocci.

The patient was admitted to the medical floor, and empiric treatment with moxifloxacin (400 mg/day IV) and clindamycin (600 mg IV every 8 hr) was started. The medication regimen was changed to vancomycin (1g IV every 12 hr) on the following day when cultures of sputum and the buttock lesion were reported to be growing *S. aureus*. These isolates were identified as MRSA susceptible to clindamycin on hospital day 5 (Table), and the antibiotic was changed back to the previous dose of clindamycin. Blood cultures were negative. The patient defervesced 2 days after admission. Cough and pleuritic chest pain slowly improved, and the WBC count decreased over the next few days. The patient was discharged home after 1 week of hospitalization with a prescription for oral clindamycin (450 mg 3 times daily for 2 weeks).

DISCUSSION

The cases reported here are notable for having a less complicated clinical course than many of the cases of MRSA CAP that have been previously reported in the literature.[1–9] The reason why some patients with MRSA CAP have less complicated courses remain unclear. However, many reported cases of MRSA CAP associated with high mortality and morbidity were documented cases of MRSA that carried *Panton-Valentine leukocidin* (*PVL*) genes. Gillet et al[7] compared 16 (8 retrospective and 8 prospective) cases of *PVL*-positive *S. aureus* pneumonia with 36 cases of *PVL*-negative *S. aureus* pneumonia. Overall, the latter patients tended to be less severely ill and to have a significantly higher survival rate than *PVL*-positive cases (94% versus 63% for *PVL*-negative and *PVL*-positive pneumonia, respectively).[7] It should be noted that many of the patients who had worse outcomes in both the *PVL*-positive and *PVL*-negative group had a preceding influenza-like illness. Another recent article also has questioned whether *PVL* is responsible for the increased morbidity and mortality associated with CA-MRSA infection.[10] Therefore, the role of PVL toxins in patient outcomes in MRSA CAP is unclear.

Unfortunately, the presence of *PVL* could not be conclusively determined in the cases reported here. *PVL* testing was not available at our institution, and attempts to test isolates for *PVL* genes at a commercial reference laboratory were unsuccessful. However, it seems unlikely that the isolates were *PVL*-negative given the prevalence of *PVL*-positive toxin genes. In a multicenter study of 422 adults from 11 US cities presenting to the EDs with acute purulent skin and soft tissue infections (SSTIs), the overall prevalence of CA-MRSA infection was 59% (range, 15%–74%). Of these CA-MRSA isolates, 98% carried the *PVL* toxin genes.[11] Other studies have corroborated this high prevalence of *PVL* gene carriage by CA-MRSA isolates in SSTIs.[12–14]

In addition, the presence of furuncles, which was seen in all 3 case patients, has been highly associated with *PVL*-positive *S. aureus*.[6,8,11,13,15] Likewise, the presence of hemoptysis and cavitation in the case patients suggests that they were *PVL*-positive MRSA strains.[1–4,6,7,9]

It is of interest that a preceding influenza-like illness or influenza was documented in several of the previously reported cases of CA-MRSA pneumonia associated with high morbidity and mortality.[1–5,7,9] In contrast, the cases reported here were not associated with influenza-like illness, and none occurred during influenza season. We postulate that sequential infection with influenza followed by MRSA may have led to a worse outcome in these earlier reports. Influenza virus is known to increase respiratory colonization with *S. aureus*, and the virus alters host defense mechanisms by affecting phagocyte function, lymphocyte count, and mucociliary clearance.[16] Associated influenza has been shown to lead to a worse prognosis in prior studies of staphylococcal pneumonia as well.[1–5,9,17]

MRSA CAP

CA-MRSA is an important emerging cause of CAP in previously healthy adults.[1–8] High mortality has been reported with CA-MRSA pneumonia. During the 2006–2007 influenza season in the United States, the reported mortality rate for MRSA CAP was 51%.[5] On autopsy, diffuse bilateral involvement with alveolar hemorrhage and necrosis of interalveolar septa and necrotic ulcerations of the trachea and bronchi have been found.[6,7] Patients who survive MRSA CAP often have significant morbidity requiring prolonged hospital stays in intensive care units.[1–8]

Given the change in epidemiology of *S. aureus*, it is conceivable that necrotizing CAP may become a widespread phenomenon. As such, there is a need for heightened awareness regarding this disease entity. Several recent studies have identified risk factors for infection (primarily in cases of SSTIs) with CA-MRSA, including younger age, antibiotic intake, contact sports, incarceration, low socioeconomic status, and illicit drug use.[11,12,18] Another recent prospective study that attempted to identify risk factors for CA-MRSA infection (eg, younger age, SSTI, snorting/smoking illegal drugs, recent incarceration) found that these factors had insufficient sensitivity, specificity, and predictive values to adequately discriminate between CA-MRSA and community-acquired methicillin-susceptible *S. aureus* infections.[19]

Diagnosis

Pneumonia is suspected on clinical grounds and is confirmed by radiologic findings. *S. aureus* should be considered as a possible cause of CAP in patients with severe pneumonia requiring admission to the intensive care unit, a recent history of furuncles, hemoptysis, pneumatoceles or cavitation seen on chest radiograph, or with gram-positive cocci in clusters seen on sputum Gram stain.[1–4,6,8,9,11,12,15,20] All 3 of our cases had a history of furuncles, 2 of which were active at the time of presentation. *S. aureus* can enter the lung parenchyma either by microaspiration of the upper respiratory flora or by the hematogenous route.[21,22] In cases 1 and 3, the pathogenesis of disease may have been bacteremic seeding from the primary skin infection. In case 2, the skin infection was remote enough that this seems an unlikely source of infection; most likely, he was colonized by CA-MRSA on his respiratory mucosa and developed pneumonia by microaspiration.

The diagnosis of MRSA CAP is conferred based on culture results. Sputum Gram stains showing gram-positive cocci in clusters may be an early clue to the diagnosis of MRSA CAP, thus allowing appropriate antibiotic coverage to be started sooner. Unfortunately, the Gram stains reported by our clinical laboratory were too nonspecific to be helpful in directing early treatment for the cases presented here, which highlights the need for adequate training of the individuals reading these stains and an increased awareness of the potentially useful clinical information that may be gained by accurate and precise reports. However, many clinicians do not perform bacteriologic studies in patients with pulmonary infections and instead treat patients empirically.[5] These cases emphasize the importance of obtaining blood and sputum cultures in patients who are hospitalized with CAP and have cavitary infiltrates.[20] Skin abscesses with purulence should also be cultured to direct the appropriate antimicrobial choice.[11]

Treatment

Initially, the approach to managing patients hospitalized due to CAP is to institute empiric treatment with broad-spectrum antibiotics, with antibiotic selection being narrowed based on the results of antibiotic susceptibilities. In cases with clinical features that suggest CA-MRSA is the underlying etiologic agent, antibiotic coverage for MRSA should be included in initial empiric antibiotic selection while awaiting culture results.[20] In CA-MRSA strains, antibiotic resistance is often limited to β-lactams. In contrast to healthcare-associated MRSA (HA-MRSA) isolates, most CA-MRSA strains remain susceptible to tetracyclines, gentamicin, clindamycin, and trimethoprim-sulfamethoxazole.[8,12,18] The MRSA isolates obtained from the case patients

were resistant to oxacillin and erythromycin but susceptible to gentamicin, clindamycin, vancomycin, rifampin, and tetracycline. In addition, the blood culture isolate from patient 1 and both skin and sputum isolates from patient 3 were found to be susceptible to trimethoprim-sulfamethoxazole and linezolid. Although most CA-MRSA strains are susceptible to fluoroquinolones, rapid emergence of resistance has been seen in HA-MRSA strains.[23] The presence of macrolide resistance may lead to inducible resistance to clindamycin. This resistance requires the use of a double-disk diffusion test to avoid treatment failure.[18] Some authors have recommended use of antibiotics that inhibit protein synthesis, such as clindamycin or linezolid, for pulmonary infections caused by *PVL*-positive MRSA.[1]

CONCLUSION

CA-MRSA remains a rare cause of CAP. History of recent or current skin infections may provide a diagnostic clue that CA-MRSA is the underlying etiologic agent for CAP. CA-MRSA pneumonia is associated with worse outcomes with or following influenza infection, whereas the role of *PVL* gene in disease outcomes remains unclear. Treatment for suspected cases of MRSA CAP should include coverage for MRSA while awaiting the results of cultures and antibiotic susceptibilities. **HP**

Corresponding author: Saqib I. Hasan, MD, Hurley Medical Center, 2 Hurley Plaza Ste. 212, Flint, MI 48503; Shasan1@hurleymc.com.

REFERENCES

1. Francis JS, Doherty MC, Lopatin U, et al. Severe community-onset pneumonia in healthy adults caused by methicillin-resistant *Staphylococcus aureus* carrying the Panton-Valentine leukocidin genes. Clin Infect Dis 2005;40:100–7.
2. Micek ST, Dunne M, Kollef MH. Pleuropulmonary complications of Panton-Valentine leukocidin-positive community-acquired methicillin-resistant *Staphylococcus aureus*. Chest 2005;128:2732–8.
3. Frazee BW, Salz TO, Lambert L, Perdrequ-Remington F. Fatal community-associated methicillin-resistant *Staphylococcus aureus* pneumonia in an immunocompetent young adult. Ann Emerg Med 2005;46:401–4.
4. Hageman JC, Uyeki TM, Francis JS, et al. Severe community-acquired pneumonia due to *Staphylococcus aureus*, 2003–04 influenza season. Emerg Infect Dis 2006;12:894–9.
5. Kallen AJ, Brunkard J, Moore Z, et al. *Staphylococcus aureus* community-acquired pneumonia during the 2006 to 2007 influenza season. Ann Emerg Med 2008 Jun 3 [Epub ahead of print].
6. Lina G, Piemont Y, Godail-Gamot F, et al. Involvement of Panton-Valentine leukocidin-producing *Staphylococcus aureus* in primary skin infections and pneumonia. Clin Infect Dis 1999;29:1128–32.
7. Gillet Y, Issartel B, Vanhems P, et al. Association between *Staphylococcus aureus* strains carrying gene for Panton-Valentine leukocidin and highly lethal necrotising pneumonia in young immunocompetent patients. Lancet 2002;359:753–9.
8. Dufour P, Gillet Y, Bes M, et al. Community-acquired methicillin-resistant *Staphylococcus aureus* infections in France: emergence of a single clone that produces Panton-Valentine leukocidin. Clin Infect Dis 2002;35:819–24.
9. Boussaud V, Parrot A, Mayaud C, et al. Life-threatening hemoptysis in adults with community-acquired pneumonia due to Panton-Valentine leukocidin-secreting *Staphylococcus aureus*. Intensive Care Med 2003;29:1840–3.
10. Voyich JM, Otto M, Mathema B, et al. Is Panton-Valentine leukocidin the major virulence determinant in community-associated methicillin-resistant *Staphylococcus aureus* disease? J Infect Dis 2006;194:1761–70.
11. Moran GJ, Krishnadasan A, Gorwitz RJ, et al. Methicillin-resistant *S. aureus* infections among patients in the emergency department. N Engl J Med 2006;355:666–74.
12. Kaplan SL, Hulten KG, Gonzalez BE, et al. Three-year surveillance of community-acquired *Staphylococcus aureus* infections in children. Clin Infect Dis 2005;40:1785–91.
13. Vandenesch F, Naimi T, Enright MC, et al. Community-acquired methicillin-resistant *Staphylococcus aureus* carrying Panton-Valentine leukocidin genes: worldwide emergence. Emerg Infect Dis 2003;9:978–84.
14. Okuma K, Iwakawa K, Turnidge JD, et al. Dissemination of new methicillin-resistant *Staphylococcus aureus* clones in the community. J Clin Microbiol 2002;40:4289–94.
15. Yamasaki O, Kaneko J, Morizane S, et al. The association between *Staphylococcus aureus* strains carrying Panton-Valentine leukocidin genes and the development of deep-seated follicular infection. Clin Infect Dis 2005;40:381–5.
16. Couch RB. The effects of influenza on host defenses. J Infect Dis 1981;144:284–91.
17. Woodhead MA, Radvan J, Macfarlane JT. Adult community-acquired staphylococcal pneumonia in the antibiotic era: a review of 61 cases. Q J Med 1987;64:783–90.
18. Deresinski S. Methicillin-resistant *Staphylococcus aureus*: an evolutionary, epidemiologic, and therapeutic odyssey. Clin Infect Dis 2005;40:562–73.
19. Miller LG, Perdreau-Remington F, Bayer AS, et al. Clinical and epidemiologic characteristics cannot distinguish community-associated methicillin-resistant *Staphylococcus aureus* infection from methicillin-susceptible *S. aureus* infection: a prospective investigation. Clin Infect Dis 2007;44:471–82.
20. Mandell LA, Wunderlink RG, Anzueto A, et al. Infectious Diseases Society of America/American Thoracic Society consensus guidelines on the management of community-acquired pneumonia in adults. Clin Infect Dis 2007;44 Suppl 2:S27–72.
21. Etienne J. Panton-Valentine leukocidin: a marker of severity for *Staphylococcus aureus* infection [editorial]? Clin Infect Dis 2005;41:591–3.
22. Lowy FD. *Staphylococcus aureus* infections. N Engl J Med 1998;339:520–3.
23. Limoncu MH, Ermertcan S, Cetin CB, et al. Emergence of phenotypic resistance to ciprofloxacin and levofloxacin in methicillin-resistant and methicillin-sensitive *Staphylococcus aureus* strains. Int J Antimicrob Agents 2003;21:420–4.

Copyright 2008 by Turner White Communications Inc., Wayne, PA. All rights reserved.