A 5-Week-Old Boy with a 1-Week History of Vomiting

Alexander Khaletskiy, MD
Michael D. Burg, MD

CASE PRESENTATION

A 5-week-old male infant presented with a 1-week history of vomiting. His mother stated that the vomiting generally occurred soon after the infant was fed. Initially, the vomiting was infrequent but was progressively worsening. The patient's mother reported that the infant had been feeding well and had a good appetite. However, he had begun vomiting the entire volume of formula shortly after being fed since the day prior to this presentation. His mother reported that the vomitus was nonbilious and that there was a decrease in urinary output from 6 to 4 diapers daily. The patient was not febrile, and there was no cough or shortness of breath. History was negative for diarrhea or bloody stool. The infant was born full term via normal spontaneous vaginal delivery. A review of the patient's past medical and family history was noncontributory.

On physical examination, the patient was afebrile with a minimally elevated heart rate. He appeared to be somewhat uncomfortable but was in no acute distress. Mucous membranes were moist, and the lungs were clear on auscultation. The abdomen was moderately distended; on palpation of the abdomen, the infant forcefully vomited and then began to cry. Rectal examination was normal, and the stool was negative for blood. The remainder of the physical examination was normal. An intravenous fluid bolus of 20 mL/kg of normal saline was started, and an abdominal radiograph (**Figure 1**) and electrolyte panel were ordered (**Table**).

WHAT IS YOUR DIAGNOSIS?

(A) Gastroesophageal reflux
(B) Hirschsprung's disease
(C) Hypertrophic pyloric stenosis
(D) Intussusception
(E) Malrotation with midgut volvulus
(F) Necrotizing enterocolitis

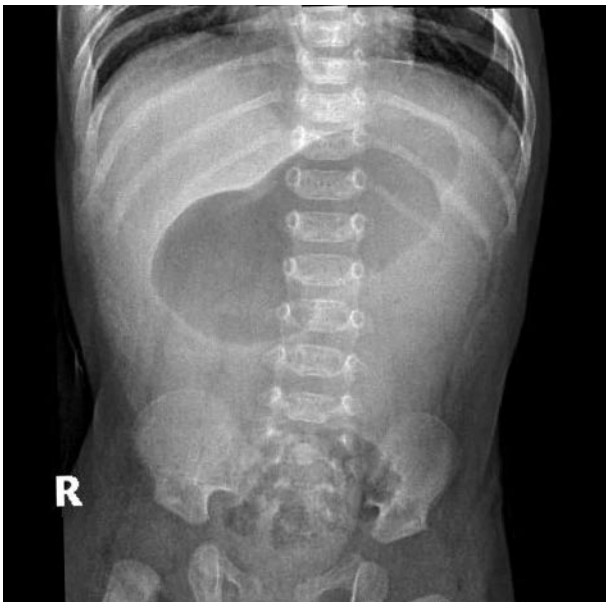

Figure 1. An upright abdominal radiograph of the case patient demonstrating caterpillar sign. Decreased bowel gas is seen distal to the stomach.

Table. Electrolyte Panel for the Case Patient

Study (Units)	Result	Reference Range
Sodium (mEq/L)	137	136–142
Potassium (mEq/L)	3.3	3.5–5.0
Chloride (mEq/L)	90	96–106
Bicarbonate (mEq/L)	34	21–28
Blood urea nitrogen (mg/dL)	15	8–23
Creatinine (mg/dL)	0.2	0.6–1.2
Glucose (mg/dL)	97	70–110

At the time of submission, Dr. Khaletskiy was a resident, Department of Emergency Medicine, The University of California, San Francisco–Fresno Emergency Medicine Residency Program, San Francisco, CA. He is now an emergency medicine physician, Mercy General Hospital, Sacramento, CA. Dr. Burg is an associate clinical professor, Department of Emergency Medicine, The University of California, San Francisco, Fresno–Central Medical Education Program.

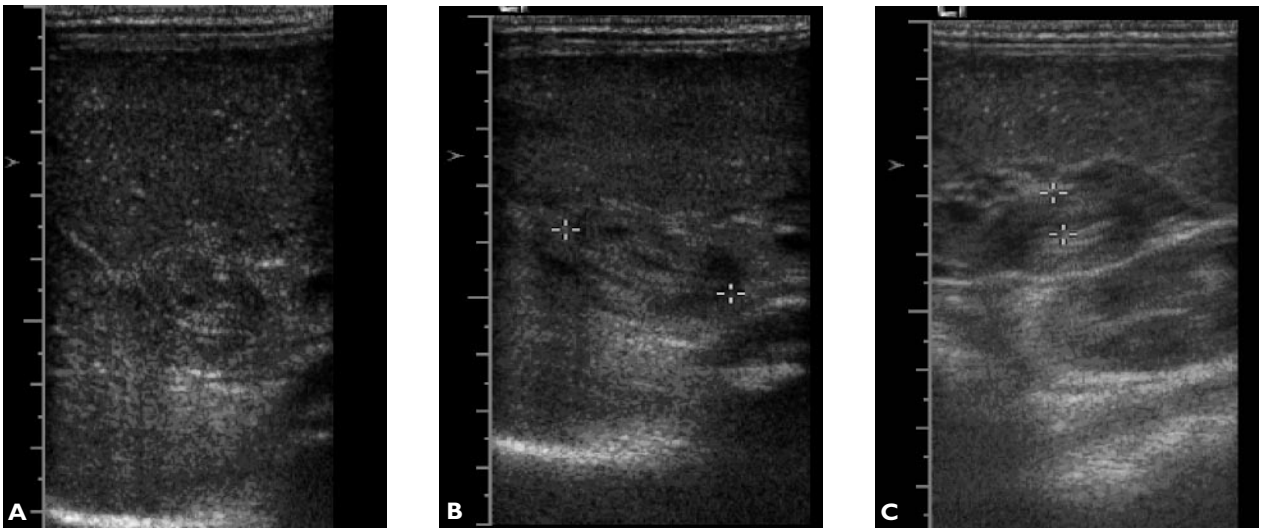

Figure 2. Ultrasound of the case patient demonstrating a hypertrophied pylorus (**A**), with a pyloric length of 17 mm (**B**) and pyloric width exceeding 3 mm (**C**).

ANSWER

The correct answer is (C), hypertrophic pyloric stenosis (HPS).

DISCUSSION

When evaluating vomiting in an infant, obtaining a precise description of the symptoms is important in making the correct diagnosis. Etiologic possibilities vary depending on whether the course of vomiting has been sudden in onset, gradually progressive, chronic, or unchanging. Frequency of emesis may have important implications regarding the severity of disease and the risk for dehydration or electrolyte disturbances. The age of the child will also provide important diagnostic clues.

All of the above listed conditions may cause vomiting in an infant. However, infants who have malrotation with midgut volvulus typically present with bilious emesis, abdominal distention, and shock. Necrotizing enterocolitis (NEC) is most often seen in premature infants in neonatal intensive care. Clinical features include emesis, which can be bloody, hematochezia, abdominal distension, and shock. Unlike the case patient, the infant will be extremely ill in appearance. In gastroesophageal reflux, the emesis is also nonbilious, but vomiting does not worsen over time and is rarely projectile. Intussusception is an unlikely diagnosis in this case since patients who have intussusception most commonly present between age 5 and 12 months. Typically, patients will have cyclical episodes of severe abdominal pain. Neonates with Hirschsprung's disease are often diagnosed in the nursery when they fail to pass meconium. Symptoms may include constipation and poor weight gain. Finally, it should be noted that cases of infantile vomiting are not always gastrointestinal in origin. Other etiologies include infectious agents, intracranial pathologies, inborn errors of metabolism, and medication side effects. Again, careful history taking and physical examination will aid in excluding these etiologies. Nongastrointestinal etiologies were not considered in this patient due to the lack of evidence to support these causes as likely diagnoses.

CLINICAL COURSE OF THE PATIENT

Review of the electrolyte panel and an abdominal radiograph prompted further evaluation. An abdominal ultrasound was performed, which demonstrated a hypertrophied pyloric wall (**Figure 2**). The patient was diagnosed with HPS, and a pediatric surgeon was consulted. The infant underwent successful Ramstedt pyloromyotomy that resulted in complete resolution of his symptoms.

HYPERTROPHIC PYLORIC STENOSIS

HPS in infants is characterized by progressive muscular hypertrophy of the pylorus, which eventually leads to near occlusion of the gastric outlet. The incidence of HPS is approximately 1 case per 250 live births.[1] HPS affects male infants 4 times more frequently than female infants. Cases of HPS can cluster in families, particularly when there is a positive maternal family history.[1]

Etiology

The etiology of HPS remains unclear but is believed to be multifactorial, with genetic and environmental components. *Helicobacter pylori*, immature neurologic transmitter function of the pyloric ring muscle, low nitric oxide synthase activity, elevated prostaglandin, erythromycin use during pregnancy, infant use of erythromycin, and maternal smoking have all been described as possible causes,[2–7] but no clear evidence exists to support any of these propositions.

Presentation

Infants with HPS usually present for medical attention in their second to sixth week of life with progressive worsening of nonbilious emesis that becomes projectile. Initially, infants with HPS remain vigorous and feed well, but as dehydration and metabolic derangements worsen (classically hypochloremic, hypokalemic metabolic alkalosis), they may become lethargic. A palpable pylorus—often referred to as an "olive"—may be found on physical examination. Palpation of an olive in the right clinical setting (ie, in an infant between age 2–8 wk with nonbilious progressive, projectile vomiting as seen in the case patient) is highly suggestive of HPS. Emptying the stomach by inserting a nasogastric tube may facilitate the abdominal examination. Alternatively, examining the infant soon after an episode of vomiting may achieve the same goal. Peristaltic waves may be seen progressing across the child's upper abdomen from left to right just before emesis.

Imaging Studies

Abdominal radiographs may show a modified "double bubble" sign (representing an enlarged body of the stomach and pylorus) or a caterpillar sign (a markedly dilated stomach with exaggerated incisura, which represents increased gastric peristalsis to an area of obstruction). Decreased bowel gas will be seen distal to the stomach (Figure 1). These abdominal radiograph findings are not diagnostic but only suggestive of the diagnosis; therefore, an abdominal ultrasound should be obtained to confirm the diagnosis of HPS, regardless of the presence of clinical findings such as an olive. The diagnostic accuracy of ultrasound for HPS is high, with sensitivity and specificity approaching 100%.[8] Ultrasound will reveal a thick-walled, elongated pylorus. The diagnostic criteria for HPS vary in different reports. Published criteria have ranged from 3 to 4 mm for the pyloric muscle width and from 15 to 19 mm for the pyloric muscle length.[9–11] Ultrasound images of the case patient showed a hypertrophied pyloric wall, with a width and length exceeding 3 mm and 17 mm, respectively (Figure 2).

Differential Diagnosis

HPS is among the potential gastrointestinal causes of vomiting in neonates and infants. As vomiting seen in infants and neonates may be indicative of a serious underlying condition, physicians should be familiar with the differential diagnosis in order to expedite the appropriate management. The following section provides a brief overview of the salient features of malrotation with midgut volvulus, NEC, gastroesophageal reflux, intussusception, and Hirschsprung's disease.

Malrotation with midgut volvulus. Patients who have malrotation with midgut volvulus often present in the first month of life. As noted earlier, infants with this condition will have bilious emesis and abdominal distention and may be quite ill or even in shock on presentation. Bilious emesis is the most common presenting feature of malrotation with midgut volvulus and is present in more than 75% of cases.[12–14] However, it should be noted that 1 study indicated that midgut volvulus is the underling etiology in only 20% of cases where an infant presents with bilious emesis.[12] Abdominal radiographs may show a dilated stomach, air-fluid levels in the small bowel, and a paucity of small bowel gas distally.[15] Upper gastrointestinal imaging is the diagnostic procedure of choice and may reveal a characteristic corkscrew appearance of the duodenum (a spiral course of midgut loops as the opacified duodenum twists around the mesenteric artery).

Malrotation is more common in males, with a ratio of at least 2:1, and approximately 75% of all infants with malrotation will develop volvulus.[16] This condition results from a flaw in embryologic development wherein the duodenum incompletely rotates and fails to attach in the proper anatomic locations. As a result, the mesentery is able to twist upon itself, leading to obstruction and vascular compromise. Malrotation with midgut volvulus is a surgical emergency that has a mortality rate between 3% and 15%.[14] Management includes intravenous fluids, nasogastric suctioning, and urgent surgical consultation. Ill-appearing infants also should receive antibiotics.

Necrotizing enterocolitis. NEC is a disease of premature infants and is most commonly seen in neonatal intensive care units. However, approximately 10% of NEC cases occur in full-term and near-term infants within 1 to 4 weeks of life.[17] Infants with NEC present with bilious or nonbilious vomiting. Hematemesis and hematochezia may occur in more severe cases. Abdominal radiographs will show varying degrees of dilated bowel loops. Pneumatosis intestinalis (gas in the intestinal wall) and biliary tract gas may be seen in advanced NEC. Portal venous gas may be seen in 10%

to 30% of cases.[18] These infants are quite ill and often require respiratory and cardiovascular support. Broad-spectrum antibiotics should be started, and a pediatric surgeon should be emergently consulted.

Gastroesophageal reflux. Gastroesophageal reflux is a common cause of vomiting during infancy and is caused by an incompetent lower esophageal sphincter. Symptom severity ranges from occasional spitting up to persistent vomiting. It may be difficult to distinguish between early gastroesophageal reflux and HPS when a palpable olive is not present, as both conditions present with nonbilious emesis. However, emesis does not worsen with time and is rarely projectile in gastroesophageal reflux, which may aid in distinguishing this condition from HPS prior to ultrasound. Most infants with gastroesophageal reflux will continue to gain weight, although failure to thrive can occur. In general, reflux symptoms resolve by age 3 months. Small frequent feedings, frequent burping, thickened formula, and a semi-upright position after feeding will improve symptoms in most cases.[19] In more severe cases, histamine blockers and metoclopramide can be helpful.[20,21] Nissen fundoplication is indicated in patients who do not respond to conservative and medical management. In fundoplication, the fundus of the stomach is wrapped around the inferior esophagus, preventing the gastric content reflux.

Intussusception. Intussusception most commonly occurs between 5 and 12 months of life. Although intussusception is more often recognized as a cause of small bowel obstruction in children, approximately 5% of cases occur in adults. In adults, intussusception is more likely to be associated with an underlying pathologic process.[22,23] Intestinal obstruction is caused by telescoping of 1 segment of the intestine into another, which leads to obstruction of venous return, edema of the bowel wall, bowel obstruction, and ischemia of the bowel wall. Perforation may also occur. Ileocolic intussusceptions are the most commonly seen type.

Patients with intussusception may present with abdominal pain, vomiting, and bloody stools. Prior episodic abdominal pains may be described. During painful episodes, the child is inconsolable, often described as drawing the legs up to the abdomen and crying in pain. Alternatively, children occasionally present without a history of pain and instead present with lethargy. Abdominal palpation classically reveals a sausage-like mass in the right upper quadrant. Abdominal radiographs are usually abnormal but are not diagnostic. Ultrasound is commonly used to diagnose intussusception. Barium enemas can be both diagnostic and therapeutic, since the pressure exerted by the contrast serves to reduce the intussusception. Air enemas can be used for diagnosis and reduction as well.[24] Surgical correction is required if nonsurgical means fail to reduce the intussusception or in cases of perforation.

Hirschsprung's disease. Hirschsprung's disease is a congenital aganglionosis of the colon and is 1 of the causes of partial intestinal obstruction in early infancy. This pathology is more common in boys.[25] Although Hirschsprung's disease is usually sporadic, it may be associated with Down syndrome.[26] The diagnosis is often suspected in the nursery when the neonate fails to pass meconium within the first 24 hours of life. Constipation, vomiting, and abdominal distention are other presenting symptoms. Abdominal radiographs may reveal a dilated colon with air-fluid levels in the small and large bowel; however, these studies are not useful in most cases. A barium enema revealing a narrow aganglionic segment with proximal dilation is highly suggestive of Hirschsprung's disease.[15] However, total aganglionosis may be missed on barium enema when the transition zone is not visualized. The diagnosis is made by manometry and biopsy. Biopsy will show absence of ganglion cells and the presence of nerve trunk hypertrophy.

Management

Initial management of HPS includes administration of intravenous fluids, correction of electrolyte abnormalities, and pediatric surgical consultation. It should be assumed that the infant is dehydrated in these cases, and he or she should be given an infusion of 5% glucose in a half-normal saline solution with the addition of 10 mEq/L of potassium chloride begun at a rate of 150 mL/kg/day. A bolus of 10 to 20 mL/kg of normal saline may be required. The electrolyte and metabolic abnormalities must be corrected prior to surgery.[26]

Definitive management for HPS is surgical. Ramstedt pyloromyotomy is performed, which involves incision of the hypertrophic pylorus to relieve constriction. This procedure can be performed laparoscopically or open. Studies comparing open with laparoscopic pyloromyotomy suggest that the less invasive laparoscopic approach may be a safe and effective alternative to the open procedure.[27,28]

Nonoperative measures also have been considered for treating HPS. Endoscopically-guided balloon dilation for HPS has been described. Since balloon dilation does not reliably disrupt the seromuscular ring, attempts at this technique are best reserved for patients in whom general anesthesia would pose a significant risk or in whom a surgical approach to the pylorus is not possible.[29] Administering intravenous atropine also

has been studied; however, atropine treatment requires prolonged hospitalization and has a significantly lower success rate than surgery.[30] Nasoduodenal feedings have been described as an effective treatment option as well.[31] However, surgical management remains the treatment of choice. Nonoperative measures are only appropriate if operation is not feasible. Mortality with HPS is rare.[32]

CONCLUSION

HPS is among the causes of vomiting in an infant. Prior to conferring the diagnosis of HPS, care must be taken to exclude patients with gastrointestinal pathologies requiring urgent management (eg, NEC, intestinal obstruction) as well as nongastrointestinal pathologies such as infection and intracranial pathologies. In patients for whom a careful history and physical examination indicates that HPS is a likely diagnosis, initial management includes fluid resuscitation and electrolyte correction as needed. Abdominal ultrasound confirms the diagnosis of HPS. Once diagnosis is established, treatment is typically surgical, with a complete recovery being the expected result. **HP**

Corresponding author: Alexander Khaletskiy, MD, Mercy General Hospital, 4001 J Street, Sacramento, CA 95819; alex1kh@yahoo.com.

REFERENCES

1. Rasmussen L, Green A, Hansen LP. The epidemiology of infantile hypertrophic pyloric stenosis in a Danish population, 1950–84. Int J Epidemiol 1989;18:413–7.
2. Sherwood W, Choudhry M, Lakhoo K. Infantile hypertrophic pyloric stenosis: an infection cause? Pediatr Surg Int 2007;23:61–3.
3. Hussain N, Herson VC. Erythromycin use during pregnancy in relation to pyloric stenosis. Am J Obstet Gynecol 2002;187:821–2.
4. Cooper WO, Griffin MR, Arbogast P, et al. Very early exposure to erythromycin and infantile hypertrophic pyloric stenosis. Arch Pediatr Adolesc Med 2002;156:647–50.
5. Sorensen HT, Norgard B, Pederson L, et al. Maternal smoking and risk of hypertrophic infantile pyloric stenosis: 10 year population based cohort study. BMJ 2002;325:1011–2.
6. Vanderwinden JM, Mailleux P, Schiffmann SN, et. al. Nitric oxide synthase activity in infantile hypertrophic pyloric stenosis [published erratum appears in N Engl J Med 1992;327:1252]. N Engl J Med 1992;327:511–5.
7. Omura N, Kashiwagi H, Aoki T. Changes in gastric hormones associated with gastric outlet obstruction. An experimental study in rats. Scand J Gastroenterol 1993;28:568–72.
8. Hernanz-Schulman M, Sells LL, Ambrosino MM, et al. Hypertrophic pyloric stenosis in the infant without a palpable olive: accuracy of sonographic diagnosis. Radiology 1994;193:771–6.
9. Rohrschneider WK, Mittnacht H, Darge K, Troger J. Pyloric muscle in asymptomatic infants: sonographic evaluation and discrimination from idiopathic hypertrophic pyloric stenosis. Pediatr Radiol 1998;28:429–34.
10. Lund Kofoed PE, Host A, Elle B, Larsen C. Hypertrophic pyloric stenosis: determination of muscle dimensions by ultrasound. Br J Radiol 1988;61:19–20.
11. Yip WC, Tay JS, Wong HB. Sonographic diagnosis of infantile hypertrophic pyloric stenosis: critical appraisal of reliability and diagnostic criteria. J Clin Ultrasound 1985;13:329–32.
12. Lilien LD, Srinivasan G, Pyati SP, et al. Green vomiting in the first 72 hours in normal infants. Am J Dis Child 1986;140:662–4.
13. Kao H. Bilious vomiting during the first week of life. Zhonghua Min Guo Xiao Er Ke Yi Xue Hui Za Zhi 1994;35:202–7.
14. Bonadio WA, Clarkson T, Naus J. The clinical features of children with malrotation of the intestine. Pediatr Emerg Care 1991;7:348–9.
15. Hernanz-Schulman M. Imaging of neonatal gastrointestinal obstruction. Radiol Clin North Am 1999;37:1163–86.
16. Torres AM, Ziegler MM. Malrotation of the intestine. World J Surg 1993; 17:326–31.
17. Kliegman RM, Fanaroff AA. Necrotizing enterocolitis. N Engl J Med 1984; 310:1093–103.
18. Daneman A, Woodward S, de Silva M. The radiology of neonatal necrotizing enterocolitis (NEC). A review of 47 cases and the literature. Pediatr Radiol 1978; 7:70–7.
19. Orenstein SR, McGowan JD. Efficacy of conservative therapy as taught in the primary care setting for symptoms suggesting infant gastroesophageal reflux. J Pediatr 2008;152:310–4.
20. Hassall E. Decisions in diagnosing and managing chronic gastroesophageal reflux disease in children. J Pediatr 2005;146(3 Suppl):S3–12.
21. Hassall E, Israel D, Shepherd R, et al; International Pediatric Omeprazole Study Group. Omeprazole for treatment of chronic erosive esophagitis in children: a multicenter study of efficacy, safety, tolerability and dose requirements. J Pediatr 2000;137:800–7.
22. Azar T, Berger DL. Adult intussusception. Ann Surg 1997;226:134–8.
23. Nagorney DM, Sarr MG, McIlrath DC. Surgical management of intussusception in the adult. Ann Surg 1981;193:230–6.
24. Kim YS, Rhu JH. Intussusception in infancy and childhood. Analysis of 385 cases. Int Surg 1989;74:114–8.
25. Suita S, Taguchi T, Ieiri S, Nakatsuji T. Hirschsprung's disease in Japan: analysis of 3852 patients based on a nationwide survey in 30 years. J Pediatr Surg 2005;40:197–201.
26. Halter JM, Baesl T, Nicolette L, Ratner M. Common gastrointestinal problems and emergencies in neonates and children. Clin Fam Pract 2004;6:731–54.
27. Adibe OO, Nichol PF, Flake AW, Mattei P. Comparison of outcomes after laparoscopic and open pyloromyotomy at a high-volume pediatric teaching hospital. J Pediatr Surg 2006;41:1676–8.
28. Kim SS, Lau ST, Lee SL, et. al. Pyloromyotomy: a comparison of laparoscopic, circumumbilical, and right upper quadrant operative techniques. J Am Coll Surg 2005;201:66–70.
29. Hayashi AH, Giacomantonio JM, Lau HY, Gillis DA. Balloon catheter dilatation for hypertrophic pyloric stenosis. J Pediatr Surg 1990;25:1119–21.
30. Meissner PE, Engelmann G, Troeger J, et al. Conservative treatment of infantile hypertrophic pyloric stenosis with intravenous atropine sulfate does not replace pyloromyotomy. Pediatr Surg Int 2006;22:1021–4.
31. Yamashiro Y, Mayama H, Yamamoto K, et al. Conservative management of infantile pyloric stenosis by nasoduodenal feeding. Eur J Pediatr 1981;136: 187–92.
32. Maxwell-Armstrong CA, Cheng M, Reynolds JR, Holliday HW. Surgical management of hypertrophic pyloric stenosis—can it be performed by general surgeons? Ann R Coll Surg Engl 2000;82:341–3.

Copyright 2008 by Turner White Communications Inc., Wayne, PA. All rights reserved.