Management of Abnormal Cervical Cytology: Review Questions

Teresa E. Baker, MD
Sean S. Tedjarati, MD, MPH

QUESTIONS

Choose the single best answer for each question.

1. **According to the American College of Obstetricians and Gynecologists (ACOG) guidelines, when should cervical cancer screening begin?**
   (A) Age 16 years
   (B) Age 18 years
   (C) Age 21 years or 3 years after initiation of sexual contact
   (D) A year after initiation of sexual contact regardless of age

2. **A 17-year-old woman presents to her gynecologist for a well-patient examination. She states that she is currently sexually active and has been since age 16 years. She has had 2 lifetime sexual partners. The patient admits that she and her current partner use condoms sporadically. She desires a more reliable form of reversible contraception. She smokes about 10 cigarettes per week and drinks alcohol on the weekends but denies any illicit drug use. She takes no medications. All of the following are appropriate recommendations for this patient EXCEPT**
   (A) Empiric treatment for gonorrhea and chlamydia
   (B) Human papillomavirus (HPV) vaccine
   (C) Testing for sexually transmitted diseases (STDs) with cervical cultures
   (D) Tobacco cessation

3. **A 36-year-old woman presents to her gynecologist for an annual examination. The patient is currently on a low-dose oral contraceptive medication. She has had 5 lifetime sexual partners and 4 successful pregnancies. She has never had an STD and has no history of abnormal cervical cytology. She smokes 10 cigarettes daily. A pelvic examination is performed, and a Papanicolaou (Pap) smear reveals high-grade squamous intraepithelial lesions (HSILs). What is the next step in the management of this patient?**
   (A) Colposcopy with cervical biopsy and endocervical assessment
   (B) Cryotherapy
   (C) Reflex HPV typing
   (D) Repeat Pap smear in 6 months

4. **A 60-year-old obese woman with type 2 diabetes and hypertension presents to the gynecologist for an annual examination with complaints of irregular vaginal bleeding. She has been experiencing hot flashes for the past 6 months. Her family practitioner performed a Pap smear 3 years ago and told her it was "mildly abnormal." A repeat Pap smear done at this visit reveals atypical glandular cells (AGCs) not otherwise specified. What is the most appropriate next step in this patient's management?**
   (A) Colposcopy with cryotherapy
   (B) Colposcopy with endocervical assessment and endometrial biopsy
   (C) Immediate hysterectomy
   (D) Pelvic ultrasound

5. **A 50-year-old woman presents to her primary care physician asking to be tested for STDs. She reports recently leaving an abusive relationship and is concerned about her previous partner's sexual history. On pelvic examination, an exophytic lesion is noted on the cervix (Figure). What is the next step in this patient's management?**

Dr. Baker is an assistant professor and Dr. Tedjarati is an associate professor; both are at the Department of Obstetrics and Gynecology, Texas Tech University Health Sciences Center, Amarillo, TX.

(A) Biopsy the cervical lesion
(B) Cervical cone biopsy
(C) Cryotherapy or laser ablation of the cervix
(D) Perform a Pap smear and obtain cervical cultures

6. **A 32-year-old woman recently diagnosed with HIV presents to a clinic for an annual examination. Her last CD4 cell count was 450 cells/mm^3, and her viral load was 10,000 copies/mL. She has never had abnormal cervical cytology and is asymptomatic. On examination, the patient's genital tract, cervix, and uterus appear normal; no adnexal masses are noted. What is the most appropriate approach to cervical cancer screening for this patient?**
   (A) HPV viral typing
   (B) Perform annual Pap smears for 2 years and, if normal, every 3 years thereafter
   (C) Perform Pap smear every 3 months
   (D) Perform Pap smear every 6 months for 1 year and manage according to results

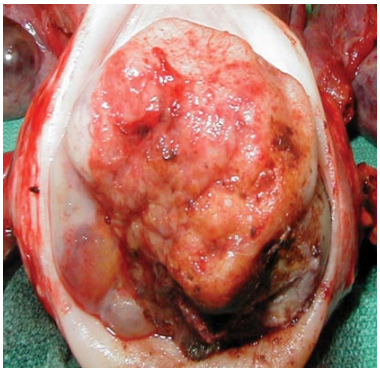

Figure. An exophytic lesion found on the cervix of the patient described in question 5.

ANSWERS AND EXPLANATIONS

1. **(C) Age 21 years or 3 years after initiation of sexual contact.** ACOG currently recommends beginning cervical cancer screening approximately 3 years after initiation of sexual intercourse but no later than age 21 years.[1] Over 50% of women will be infected with HPV within 4 years after onset of sexual activity.[2] In a large cohort study of over 600 female college students, the cumulative incidence of new HPV infection was 43%.[2] The 2-year clearance rate of HPV was over 90%; however, only 5% of women developed cytologic abnormalities.[2] Despite a high prevalence of HPV in sexually active females, only 5% to 15% will develop cervical dysplasia.[3]

2. **(A) Empiric treatment for gonorrhea and chlamydia.** This patient is at increased risk for STDs (age, < 26 yr; sporadic use of condoms; smoking) and she should be screened. However, empiric treatment for gonorrhea and chlamydia in an asymptomatic patient is not warranted. The Advisory Committee on Immunization Practices (ACIP) and ACOG recommend the quadrivalent HPV vaccine for all women aged 9 to 26 years regardless of when sexual contact was initiated.[4] The vaccine protects against HPV types 6, 11, 16, and 18. Even when patients test positive for HPV 16, the vaccine may still protect them from acquiring HPV 6, 11, and 18 and therefore decreases their chance of developing cervical dysplasia or genital warts.[4] HPV vaccines for types 16 and 18 have demonstrated an efficacy of 90% in preventing HPV infection and subsequently cervical dysplasia.[5] There are also emerging data that the type-specific vaccines may protect against future reinocculation to specific HPV types and provide cross protection against other strains of HPV. Cigarette smoking is a cofactor for progression of cervical dysplasia to cervical cancer.[6] Therefore, every clinician should recommend smoking cessation to women at risk of cervical dysplasia. Concurrent tobacco smoking with hormonal contraception increases the risk of thromboembolic disorders in women, especially those over age 35 years. These risks should be taken into consideration when discussing contraception with this patient.

3. **(A) Colposcopy with cervical biopsy and endocervical assessment.** Seventy percent or more of HSILs are classified as cervical intraepithelial neoplasia 2 or 3, and 1% to 2% of women with HSILs have invasive cancer.[7,8] If a patient has HSIL, as in this case patient, the American Society for Colposcopy and Cervical Pathology (ASCCP) recommends management with colposcopy with cervical biopsy and endocervical assessment or an immediate loop electrosurgical excision.[8] In either case, a tissue sample can be obtained to rule out invasive cervical cancer. Cryotherapy does not yield a sample for pathologic testing and thus invasive cervical cancer cannot be ruled out. Additionally, if the cervical lesion extends into the endocervical canal, ablation with cryotherapy may also make future colposcopy with cervical sampling more difficult due to cervical stenosis. Reflex HPV typing is used for identifying high-risk HPV types and for the cytologic diagnosis of atypical squamous cells of undetermined significance. Pap smears are used as a screening tool and would not provide any diagnostic information; there is no benefit from delaying diagnostic evaluation by colposcopy.

4. **(B) Colposcopy with endocervical assessment and endometrial biopsy.** A review of 1869 patients with AGC of undetermined significance found that 33.7% of these patients had a squamous intraepithelial lesion of the cervix, 2.5% had adenocarcinoma in situ, and 1% had invasive adenocarcinoma.[9] Thus, an evaluation of the entire cervix is indicated, including a colposcopic examination with cervical biopsy and endocervical assessment. Women over age 35 years with chronic anovulation and irregular bleeding are at risk for developing endometrial hyperplasia, the precursor for endometrial cancer. Therefore, endometrial sampling is indicated in all women over age 35 years with AGC of undetermined significance as well as in women younger than age 35 years with abnormal bleeding, morbid obesity, oligomenorrhea, or a clinical evaluation suggesting endometrial cancer.[10] If these evaluations do not provide a definitive diagnosis, careful examination of the uterine cavity and upper genital tract (eg, ovaries, tubes) is warranted. Cryotherapy is an option for management of cervical dysplasia without endocervical involvement and thus would not be indicated in this case. Pelvic ultrasound helps to assess the endometrial thickness, structural abnormalities of the uterus, and adnexal structures but does not replace histologic evaluation. Diagnosis should be confirmed before hysterectomy is considered.

5. **(A) Biopsy the cervical lesion.** The Figure shows an exophytic squamous cervical lesion. When a cervical lesion is visualized on pelvic examination, a biopsy of the lesion should be obtained to determine if it is benign or malignant. Although the Pap smear has a sensitivity of 58% for identifying dysplastic cervical cells, it is designed as a screening tool and is not ideal when a lesion is already visible.[7] Cryotherapy or laser ablation would not yield a tissue sample for pathologic evaluation and thus is inappropriate at this time. Cervical cone biopsy (conization) is used to evaluate and treat cervical dysplasia and microinvasive cervical cancer. However, histologic results must first be obtained to determine if a malignant condition exists before performing cervical cone biopsy, a procedure associated with potential morbidity (eg, bleeding, infection, pain, risk for cervical stenosis).

6. **(D) Perform Pap smear every 6 months for 1 year and manage according to results.** All women with HIV are at higher risk of infection, with high-risk HPV types (6, 11, 16, 18) found in approximately 60% of patients.[11] Approximately 40% of HIV-infected women with high-risk HPV types will have normal cytology. The clearance of HPV is strongly determined by the patient's serum HIV viral load, and CD4 count and HIV viral load are important markers for HPV infection. Women with a CD4 count of less than 500 cells/mm^3 have approximately a 9% chance of developing high-grade cervical dysplasia within 2 years as compared with 3% of women who are HIV negative or have a CD4 count of greater than 500 cells/mm^3.[12] All women with HIV should have an initial Pap smear. If cytology is normal, a Pap smear should be repeated in 6 months, and if these results are normal, annual screening can be continued. However, if a cytologic abnormality is found, routine evaluation such as colposcopy and directed cervical biopsies are mandated as in the management of abnormal Pap smears and cervical dysplasia in HIV-negative patients. Initial HPV testing in HIV-infected women is controversial because over 60% will have positive testing and most will not develop invasive cancer.[11] There is no evidence at this time to recommend routine HPV testing in women with HIV. Patients with prior abnormal cytology and other risk factors for cervical cancer should be monitored and evaluated closely.[11,12]

REFERENCES

1. ACOG Committee on Practice Bulletins. ACOG Practice Bulletin: clinical management guidelines for obstetrician-gynecologists. Number 45, August 2003. Cervical cytology screening (replaces committee opinion 152, March 1995). Obstet Gynecol 2003;102:417–27.
2. Ho GY, Bierman R, Beardsley L, et al. Natural history of cervicovaginal papillomavirus infection in young women. N Engl J Med 1998;338:423–8.
3. Smith JS, Lindsay L, Hoots B, et al. Human papillomavirus type distribution in invasive cervical cancer and high-grade cervical lesions: a meta-analysis update. Int J Cancer 2007;121:621–32.
4. Committee on Adolescent Health Care, ACOG Working Group on Immunization. ACOG Committee Opinion No.344: Human papillomavirus vaccination. Obstet Gynecol 2006;108(3 Pt 1):699–705.
5. Villa LL, Costa RL, Petta CA, et al. Prophylactic quadrivalent human papillomavirus (types 6, 11, 16 and 18) L1 virus-like particle vaccine in young women: a randomised double-blind placebo-controlled multicentre phase II efficacy trial. Lancet Oncol 2005;6:271–8.
6. Cannistra SA, Niloff JM. Cancer of the uterine cervix. N Engl J Med 1996; 334:1030–8.
7. American College of Obstetricians and Gynecologists. ACOG Practice Bulletin number 66, September 2005. Management of abnormal cervical cytology and histology. Obstet Gynecol 2005;106:645–64.
8. Wright TC Jr, Massad LS, Dunton CJ, et al; 2006 American Society for Colposcopy and Cervical Pathology–sponsored Consensus Conference. 2006 Consensus guidelines for the management of women with abnormal cervical cancer screening tests. Am J Obstet Gynecol 2007;197:346–55.
9. Eddy GL, Strumpf KB, Wojtowycz MA, et al. Biopsy findings in five hundred thirty-one patients with atypical glandular cells of uncertain significance as defined by the Bethesda system. Am J Obstet Gynecol 1997;177:1188–95.
10. Chhieng DC, Elgert P, Cohen JM, Cangiarella JF. Clinical significance of atypical glandular cells of undetermined significance in postmenopausal women. Cancer 2001;93:1–7.
11. Ahdieh L, Klein RS, Burk R, et al. Prevalence, incidence, and type-specific persistence of human papillomavirus in human immunodeficiency virus (HIV)-positive and HIV-negative women. J Infect Dis 2001;184:682–90.
12. Harris TG, Burk RD, Palefsky JM, et al. Incidence of cervical squamous intraepithelial lesions associated with HIV serostatus, CD4 cell counts, and human papillomavirus test results. JAMA 2005;293:1471–6.

Copyright 2008 by Turner White Communications Inc., Wayne, PA. All rights reserved.