# Left Ventricular Pseudoaneurysm After Inferior Wall Myocardial Infarction

*Venkata S. Gadi, MD*
*Deepak Thekkoott, MD*
*Chaim Kabalkin, MD*
*Adnan Sadiq, MD*
*Mario Sabado, MD*

Left ventricular pseudoaneurysm is a rare but potentially lethal complication of acute myocardial infarction.[1–3] Although relatively little is known regarding their true incidence[1] and possible presentations, pseudoaneurysms have a greater tendency to rupture in comparison with a true aneurysm. Thus, it is essential to recognize and quickly diagnose a pseudoaneurysm to provide appropriate care. This article discusses the case of a patient who presented with left ventricular pseudoaneurysm that occurred following an inferior wall myocardial infarction.

## CASE PRESENTATION

### Initial Presentation and History

An 86-year-old woman presented to the emergency department with a 2-day history of nausea and vomiting. Approximately 1 hour prior to admission, the patient presented to her primary care physician with complaints of nausea and vomiting. The physician noticed abnormal electrocardiographic changes and immediately referred her to the emergency department. She reported a continuous feeling of nausea and had vomited twice; the vomitus contained clear liquid on both occasions. Neither of her symptoms appeared to have been precipitated by food. The patient denied experiencing chest pain, shortness of breath, palpitations, dizziness, or diaphoresis as well as any preceding abdominal pain, constipation, diarrhea, or blood in stools or vomitus.

At baseline, the patient was in good health and was able to perform daily activities. She was able to walk up to 5 blocks on level ground and climb 1 to 2 flights of stairs at a time without difficulty. She reports that often her only limiting symptom was pain in both knees that had been bothering her for some time.

The patient's past medical history was significant for chronic gastroesophageal reflux disease that was fairly well controlled with daily proton pump inhibitor therapy (pantoprazole) and diverticulosis that was complicated by a prior episode of diverticulitis many years ago. Although the patient mentioned a history of arthritis, she apparently was never diagnosed with any significant arthritides. Her medication history included a daily multivitamin and pantoprazole. The patient had never smoked and denied any alcohol or illicit drug use. She also denied any family history of premature coronary artery disease or diabetes; however, she reported a history of hypertension among her siblings.

### Physical Examination

The patient's vital signs on admission were temperature, 98.4°F; pulse rate, 83 bpm and regular; blood pressure, 110/50 mm Hg, equal in both arms and without any pulsus paradoxus; and respiratory rate, 18 breaths/min. She was not in acute distress and was resting comfortably in her bed. Examination of the neck did not reveal carotid bruit but was positive for mildly elevated jugular venous pressure (the venous column was 2–3 cm from the sternal angle). Cardiac examination revealed normal heart sounds without murmurs, rubs, or gallops. Pulmonary examination revealed midline trachea, normal respiratory movements, and no tactile or vocal fremitus; careful auscultation of lungs revealed faint bibasilar crackles that disappeared upon coughing. Abdominal examination revealed normal bowel sounds and a soft abdomen on palpation, and was unremarkable for distension, rigidity, tenderness, organomegaly, or fluid. The remainder

*Drs. Gadi and Thekkoott are fellows in cardiovascular diseases, Dr. Kabalkin and Dr. Sadiq are attending cardiologists, and Dr. Sabado is a cardiothoracic surgeon; all are at Maimonides Medical Center, Brooklyn, NY.*

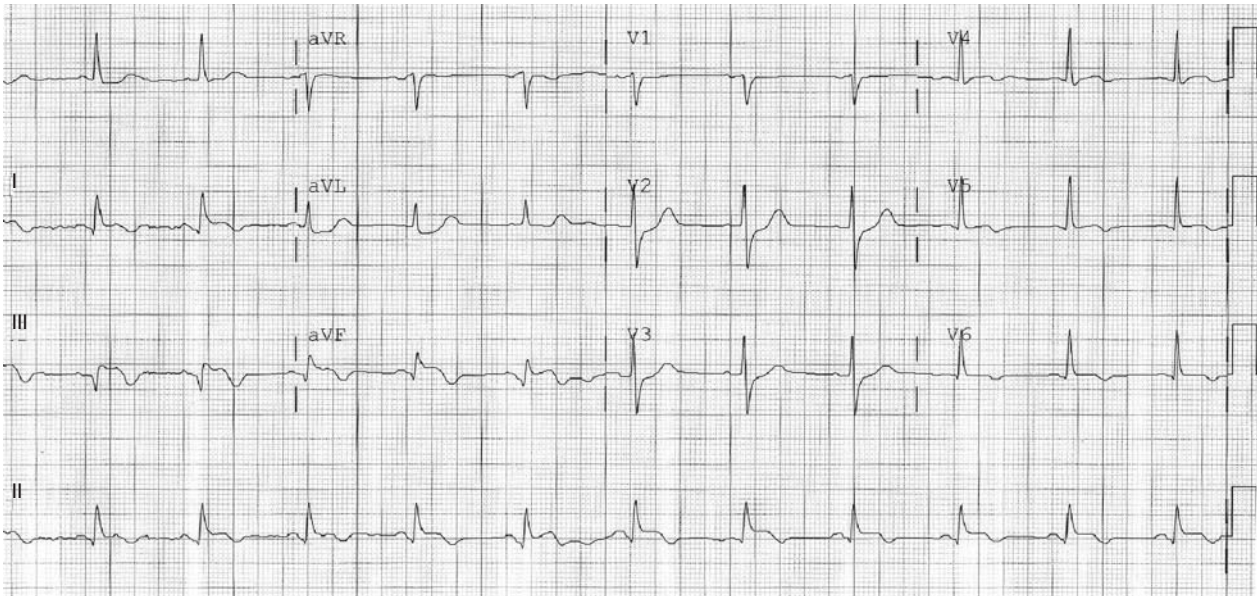


**Figure 1.** Electrocardiogram upon admission. Note the prominent ST-segment elevations along with Q waves and T-wave inversions in leads II, III, and aVF and the minor ST-segment elevations with biphasic T waves in leads $V_4$ and $V_5$.

of the physical examination, including neurologic and extremity examinations, was unremarkable.

### Electrocardiogram and Laboratory Studies

The electrocardiogram (ECG) on admission revealed normal sinus rhythm at 69 bpm, with ST-segment elevations, Q waves, and T-wave inversions in the inferior leads (II, III, aVF) and reciprocal ST-segment depressions with T-wave inversions in leads I, aVL, $V_2$, and $V_3$ (**Figure 1**). Minor (< 1 mm) ST-segment elevations were also noted in leads $V_4$ through $V_6$ along with biphasic T waves.

Cardiac markers were elevated on admission with a maximum cardiac troponin I level of 12.1 ng/mL, a creatine kinase-MB level of 34.5 ng/mL, and a creatine phosphokinase level of 796 U/L. The results of the other laboratory studies, including a complete metabolic panel and blood counts, were unremarkable. A posteroanterior view chest radiograph demonstrated normal cardiac silhouette with mild bilateral pulmonary congestion. Given the clinical presentation, ECG findings, and elevated cardiac biomarkers, a diagnosis of inferior wall ST-segment elevation myocardial infarction with a late presentation was made.

### Management

The patient subsequently underwent diagnostic coronary angiography and left ventriculography, which revealed significant triple-vessel disease with a complete occlusion of the mid portion of the right coronary artery. Left ventriculography revealed a diverticulum-like outpouching of the inferobasal wall (**Figure 2**). Because the etiology of this outpouching was unclear, the patient underwent echocardiography, including transesophageal echocardiography, which demonstrated a regional wall motion abnormality consistent with inferoposterior hypokinesis. Color flow mapping demonstrated passage of blood from the left ventricular cavity into the pericardium through an opening in the left ventricle. Doppler assessment of the flow demonstrated a continuous flow across the myocardium into the pericardium. A moderate pericardial effusion with formed elements suggesting organized pericardial hematoma especially notable surrounding the inferobasal segment was also noted. High-velocity flow was noted, which was consistent with possible pseudoaneurysm (**Figure 3**). A final diagnosis of subacute presentation of inferior wall ST-segment elevation myocardial infarction complicated by likely left ventricular pseudoaneurysm was made.

The patient was admitted to the cardiothoracic surgical intensive care unit (ICU) for observation overnight, and a coronary artery bypass graft (CABG) with possible repair of the pseudoaneurysm was scheduled for the following morning. Overnight, however, the patient developed hypotension that rapidly progressed to impending cardiac tamponade with a pulsus paradoxus of 30 mm Hg. The patient immediately underwent emergency CABG before the scheduled time, along with left ventricular inferior wall infarctectomy and

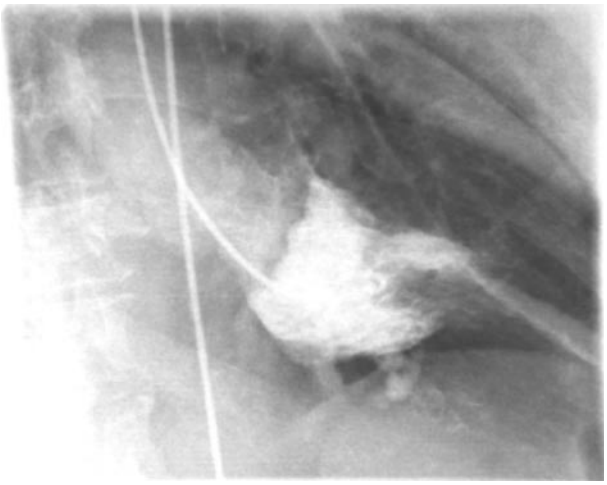

**Figure 2.** Contrast left ventriculogram showing a diverticulum-like outpouching of the inferobasal wall.

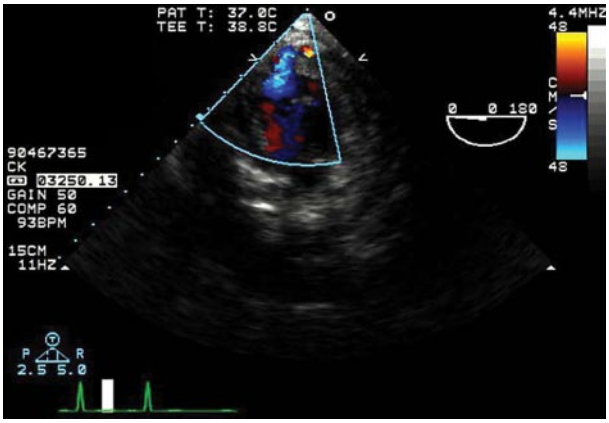


**Figure 3.** Transesophageal echocardiogram (2-chamber) with color flow mapping demonstrating blood flow from the left ventricular cavity into the pseudoaneurysm through the myocardium.

Dacron patch repair of the ruptured infarcted area of the inferior free wall.

### Follow-up

The surgery was largely uneventful; however, the patient remained intubated for approximately 24 hours after the surgery and remained in the cardiothoracic surgical ICU for 3 days. Her further hospital course was complicated by nosocomial pneumonia and sepsis, including another course in the cardiothoracic surgical ICU, and she was on a ventilator for 4 days. The patient remained hospitalized for 2 more weeks while she completed an antibiotic course and was subsequently discharged to a rehabilitation facility.

## LEFT VENTRICULAR PSEUDOANEURYSM

Cardiac rupture is usually fatal and accounts for 7% to 10% of early deaths after acute myocardial infarction.[1–3] In most cases, the cardiac wall ruptures into the peritoneal cavity and causes cardiac tamponade and death. Contained rupture of the heart is recognized less frequently and its incidence is unknown.[1,3] Incomplete rupture of the heart may occur when organizing thrombus and hematoma together with pericardium seal a rupture of the left ventricle and thus prevent the development of hemopericardium.[1] With time, this area of organized thrombus and pericardium can become a pseudoaneurysm that maintains communication with the cavity of the left ventricle.

### Features of Pseudoaneurysm and True Aneurysm

Pseudoaneurysms most commonly occur after myocardial infarction and rarely are seen after surgery, trauma, or infection.[2] Patients are often asymptomatic, and most pseudoaneurysms are detected incidentally on imaging tests. When present, symptoms include recurrent chest pain and symptoms of hypotension.[3] Examination findings include decreased heart sounds, pericardial friction rub, elevation of both left- and right-sided filling pressures, and sinus bradycardia or junctional rhythm.[4] An apical impulse may be detected when the pseudoaneurysm is large, and a third heart sound may be heard when there is mechanical interference of the mass on ventricular filling.[3] In addition, a pansystolic or to-and-fro murmur produced by flow across the mouth of the aneurysm may be heard.[3] The location of pseudoaneurysm is usually posterolateral.[5,6] The walls of pseudoaneurysms are composed of organized hematoma and pericardium and lack any elements of the original myocardial wall. In addition, they communicate with the left ventricular cavity through a narrow neck, and may contain significant quantities of old and recent thrombus, superficial portions of which can cause arterial emboli.[1,5,7–9] Finally, pseudoaneurysms are prone to rupture and cause thromboembolism and arrhythmias.[5]

The prevalence of true aneurysms in survivors of acute myocardial infarction ranges from 4% (in necropsy series) to 40% (angiographic series).[9] Aneurysms most commonly occur after myocardial infarction, and rarely are due to congenital defect, trauma, bacterial endocarditis, myocardial abscess, or Chagas' disease.[10] Patients with true aneurysm have a history of persistent left ventricular failure, angina pectoris, and less commonly, recurrent ventricular tachyarrhythmias and thromboembolism.[11] There are no characteristic diagnostic physical signs, which are often similar to those of pseudoaneurysms.[3] However, an expansile or double apex beat may

be highly suggestive.[12] True aneurysms typically involve the anterior and apical walls.[5,6,13] They always contain some myocardial elements in their walls. In addition, true aneurysms have broad necks and have a lower risk of thromboembolism.[3,11,12] Rupture is rare, and true aneurysms often result in arrhythmias.[11]

### Diagnosis and Prognosis

The diagnosis of pseudoaneurysm is usually suggested by imaging modalities such as 2-dimensional echocardiography, transesophageal echocardiography, computed tomography, magnetic resonance imaging, and left ventricular angiography.[7] The finding of a periventricular sac communicating with the left ventricle through a narrow orifice is considered to be most suggestive of a pseudoaneurysm on contrast left ventriculography; in addition, pseudoaneurysms appear avascular on coronary angiography.[8,9] The echocardiographic detection of pseudoaneurysm was initially reported in 1975. The characteristic features of pseudoaneurysm on echocardiography are sharp discontinuity of the endocardial image at the site of communication with the left ventricular cavity and an orifice that is relatively narrow in comparison with the diameter of the pseudoaneurysm.[8] Pulsed-wave and color-flow Doppler echocardiography have been useful in visualizing the high-velocity, turbulent, bidirectional flow between the left ventricle and pseudoaneurysm.[8]

Pseudoaneurysms have a greater tendency to rupture in comparison with a true aneurysm; moreover, the most common final causes of death are either an arrhythmia or a mechanical event. Thus, urgent surgery is indicated as soon as the diagnosis is made. Generally, survival following a post–acute myocardial infarction left ventricular pseudoaneurysm is rare, and the poor prognosis is attributed to the thin wall of the pseudoaneurysm. Bolognesi and colleagues[5] reported the case of a 70-year-old man with left ventricular pseudoaneurysm who survived 11 years after diagnosis without surgical therapy; however, the etiology of the pseudoaneurysm was not confirmed to be acute myocardial infarction.[9] Hurst and colleagues[14] reported a patient who survived 6 years with post–acute myocardial infarction pseudoaneurysm. Most reports of survival suggest that survival may be prolonged by a very narrow neck between the left ventricle and the pseudoaneurysm, decreased left ventricular systolic performance, and formation of a large thrombus inside the pseudoaneurysm, all of which translate into decreased strength of left ventricular systolic contraction and lesser chance of rupture.[9]

## CONCLUSION

The diagnosis of a left ventricular pseudoaneurysm requires a high index of suspicion due to the often atypical symptomatology. As in this case, pseudoaneurysms can be incidentally discovered on imaging tests. Once diagnosed, pseudoaneurysms should be operated upon urgently due to the risk of rupture, as this case clearly illustrates. Although the patient had been scheduled for surgery in an elective setting a few hours after diagnosis, interim complications developed that necessitated emergent surgery. **HP**

*Corresponding author: Venkata S. Gadi, MD, Maimonides Medical Center, 4802 10th Avenue, Brooklyn, NY 11219; drsatish_gadi@yahoo.com.*

## REFERENCES

1. Zipes DP, Libby P, Bonow RO, Braunwald E. Braunwald's heart disease: a textbook of cardiovascular medicine. 7th ed. Philadelphia: W.B. Saunders; 2005.
2. Hung MJ, Wang CH, Cherng WJ. Unruptured left ventricular pseudoaneurysm following myocardial infarction. Heart 1998;80:94–7.
3. Olivia PB, Hammill SC, Edwards WD. Cardiac rupture, a clinically predictable complication of acute myocardial infarction: a report of 70 cases with clinicopathologic correlations. J Am Coll Cardiol 1993;22:720–6.
4. Yeo TC, Malouf JF, Oh JK, Seward JB. Clinical profile and outcome in 52 patients with cardiac pseudoaneurysm. Ann Intern Med 1998;128:299–305.
5. Bolognesi R, Cucchini F, Lettieri C, et al. Left ventricular false aneurysm: an unusually prolonged natural history. Cathet Cardiovasc Diagn 1995;36:46–50.
6. Goldberg MJ. Left ventricular aneurysm. Br J Hosp Med 1982;27:143–54.
7. Kocak H, Becit N, Ceviz M, Unlu Y. Left ventricular pseudoaneurysm after myocardial infarction. Heart Vessels 2003;18:160–2.
8. Brown SL, Gropler RJ, Harris KM. Distinguishing left ventricular aneurysm from pseudoaneurysm. A review of the literature. Chest 1997;111:1403–9.
9. Tibbutt DA. True left ventricular aneurysm. Br Med J (Clin Res Ed) 1984;289:450–1.
10. Balakumaran K, Verbaan CJ, Essed CE, et al. Ventricular free wall rupture: sudden, subacute, slow, sealed, and stabilized varieties. Eur Heart J 1984;5:282–8.
11. Baur HR, Daniel JA, Nelson RR. Detection of left ventricular aneurysms on two dimensional echocardiography. Am J Cardiol 1982;50:191–6.
12. Komeda M, David TE. Surgical treatment of postinfarction false aneurysm of the left ventricle. J Thorac Cardiovasc Surg 1993;106:1189–91.
13. Catherwood E, Mintz GS, Kotler MN, et al. Two-dimensional echocardiographic recognition of left ventricular pseudoaneurysm. Circulation 1980;62:294–303.
14. Hurst CO, Fine G, Keyes JW. Pseudoaneurysm of the heart. Report of a case and review of literature. Circulation 1963;28:427–36.

Copyright 2007 by Turner White Communications Inc., Wayne, PA. All rights reserved.