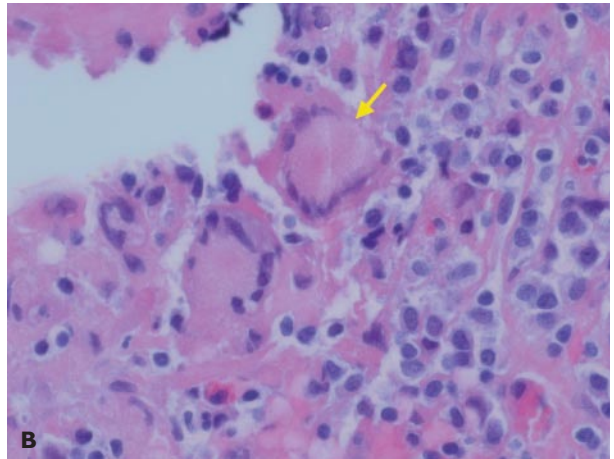
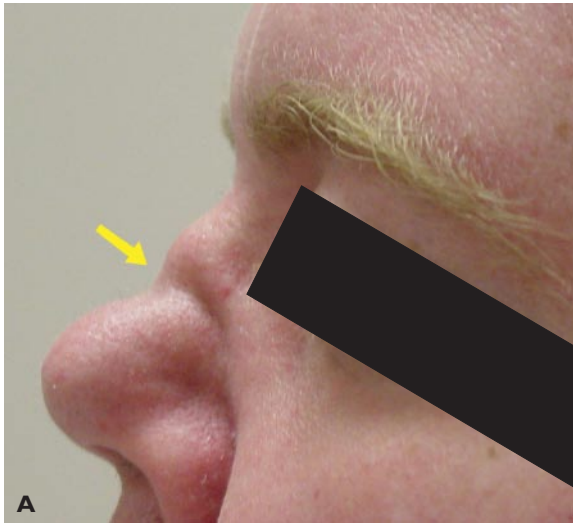


Saddle Nose Deformity

Rashid Khan, MD

Erik Maus, MD



A 25-year-old man with no significant past medical history presented to the otolaryngology clinic due to rhinorrhea, bloody nasal discharge, and bilateral maxillary sinus pain, which he had experienced intermittently for the past 2 years. His physical examination was normal with the exception of an ulcerated nasal mucosa covered with bloody crusts and the appearance of his nose (**Image A**). The results of routine laboratory testing, including a urinalysis, and a chest radiograph were normal. A computed tomography scan of his sinus cavities revealed the presence of inflammatory changes involving both maxillary antra and a deviated nasal septum. A sinus biopsy revealed focal areas of necrosis, scattered multinucleated giant cells (**Image B**), and granulomas; stains for acid-fast bacilli and fungi were negative. A rapid plasma reagin test/microhemagglutination assay was also negative. Serologic studies using indirect immunofluorescence and enzyme-linked immunosorbent assay techniques demonstrated the presence of cytoplasmic-antineutrophil cytoplasm antibody (ANCA) and proteinase-3-ANCA, respectively, confirming the diagnosis of Wegener's granulomatosis.

Saddle nose deformity has a fairly limited differential diagnosis, which classically includes Wegener's granulomatosis as well as trauma, relapsing polychon-

dritis, leprosy, and syphilis. Less common causes are Crohn's disease, pyoderma gangrenosum, Takayasu's arteritis, and sinonasal sarcoidosis. We believe the patient had a limited form of Wegener's granulomatosis involving only the upper respiratory tract, which occurs in approximately 20% of cases.¹ Initial therapy involves inducing remission with daily cyclophosphamide and glucocorticoids.^{2,3} After remission is achieved, cyclophosphamide is discontinued and either methotrexate or azathioprine is initiated. Some physicians choose to continue steroids as well.

REFERENCES

1. Sullivan EJ, Hoffman GS. Pulmonary vasculitis. *Clin Chest Med* 1998;19:759-76.
2. Guillevin L, Lhote F. Treatment of polyarteritis nodosa and microscopic polyangiitis. *Arthritis Rheum* 1998;41:2100-5.
3. Jayne D, Rasmussen N, Andrassy K, et al. A randomized trial of maintenance therapy for vasculitis associated with antineutrophil cytoplasmic autoantibodies. *European Vasculitis Study Group. N Engl J Med* 2003;349:36-44.

Dr. Khan is a clinical instructor, Baylor College of Medicine, Houston, TX. Dr. Maus is an assistant professor of anesthesiology, University of Texas at Houston, Houston, TX.