Pneumococcal Septic Shock in the Setting of Hyposplenic Celiac Disease

Daniel A. Leffler, MD, MS
Jorgé C. Magallon, MD
Atoussa Goldar-Najafi, MD
David Feller-Kopman, MD
Ciaran P. Kelly, MD

Celiac disease is a systemic immunologic disorder in which the sentinel lesion is an enteropathy triggered by polypeptides derived primarily from the gliadin proteins found in wheat, rye, and barley. Ingestion of the offending proteins leads to inflammation and intestinal mucosal damage, which results in a spectrum of abdominal symptoms, increased intestinal permeability, malabsorption, occult gastrointestinal bleeding, and diarrhea.[1] Celiac disease is being diagnosed more frequently, largely due to recent advances in diagnostic modalities.[2] Multiple studies have estimated that the prevalence of celiac disease in populations of persons of European descent is between 1:67 and 1:250,[3,4] and a growing body of literature suggests that celiac disease is a common entity in diverse populations across the globe.

A common complication of celiac disease is hyposplenism, which occurs in up to 75% of newly diagnosed patients.[5,6] Patients with hyposplenism are at risk for severe infectious complications. This article describes a case of overwhelming pneumococcal septic shock and multi-organ system failure in a patient with known celiac disease who was subsequently found to have a nonfunctioning spleen. The relationship between celiac disease and infections as well as the management of hyposplenism are also discussed.

CASE PRESENTATION

Initial Presentation and History

A 34-year-old pregnant woman presented to the labor and delivery unit at 27 weeks' gestation with symptoms of headache and fever. She had been experiencing normal fetal movements all day but had developed a headache accompanied by vomiting 1 day earlier. The night prior to admission, she developed a fever (102°F), accompanied by rigors and myalgias.

Aside from a young daughter who had an upper respiratory infection in the past week, she had no sick contacts. Past medical history was significant for chronic sinusitis, asthma, nasal polyps, and celiac disease, which was diagnosed 6 years earlier by serology in the setting of iron deficiency anemia. However, further evaluation of the patient and initiation of a gluten-free diet were not undertaken because the patient did not have gastrointestinal symptoms. The patient also reported allergies to cephalosporins and nonsteroidal anti-inflammatory drugs. Her current medications included only acetaminophen, prenatal vitamins, and an iron supplement.

Physical Examination and Laboratory Testing

On initial evaluation, the patient had a temperature of 101.6°F, blood pressure of 109/45 mm Hg, a regular heart rate of 116 bpm, a respiratory rate of 20 breaths/min, and an oxygen saturation of 100% without supplemental oxygen. Physical examination was remarkable for mid to lower back tenderness. Her neck was supple, lungs were clear, and heart sounds were normal. Examination of the abdomen revealed a gravid uterus, right upper quadrant tenderness, and a positive Murphy's sign. Fetal heart tones were approximately 150 bpm with moderate variability. Ultrasonographic evaluation of the right upper quadrant showed an enlarged gallbladder with sludge but no stones or evidence of obstruction. A lumbar puncture was unremarkable. Laboratory values on admission (**Table**) were notable for an elevated venous lactate level, increased international normalized ratio, and anemia, which suggested sepsis with early disseminated intravascular coagulation (DIC).

Dr. Leffler is a clinical fellow in gastroenterology, Department of Gastroenterology; Dr. Magallon is a senior resident in internal medicine, Department of Medicine; Dr. Goldar-Najafi is a staff physician, Department of Pathology; Dr. Feller-Kopman is an assistant professor of medicine and director of Medical and Procedure Service; and Dr. Kelly is an associate professor of medicine, Department of Pulmonary-Critical Care. All are at Beth Israel Deaconess Medical Center, Boston, MA.

Table. Admission and Peak Laboratory Results for the Case Patient

Laboratory Study	Initial Value	Peak Value (Hospital Day)	Normal Range
Alanine aminotransferase (U/L)	24	1401 (3)	10–40
Aspartate aminotransferase (U/L)	33	2164 (3)	20–48
Creatinine (mg/dL)	0.8	7.6 (14)	0.6–1.2
Hematocrit (%)	26	22 (2)	35–45
International normalized ratio	2.3	4.2 (2)	0.9–1.1
Platelet count ($\times 10^3/\mu L$)	409	29 (3)	150–450
Total bilirubin (mg/dL)	0.2	4.3 (5)	0.3–1.2
Venous lactate (mg/dL)	8.4	13.9 (3)	4.5–19.8
White blood cell count ($\times 10^3/\mu L$)	8.9	68.0 (7)	4.5–11.0

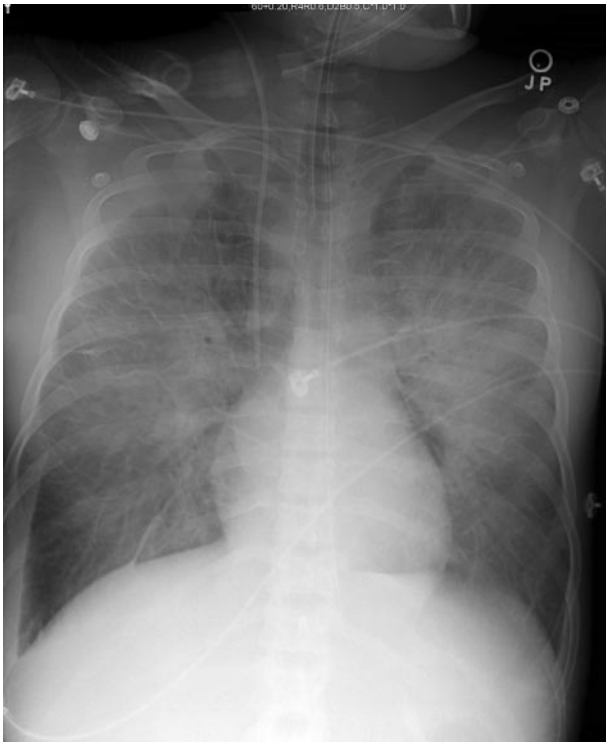

Figure 1. Chest radiograph of the case patient that revealed changes consistent with either multifocal pneumonia or acute respiratory distress syndrome.

Hospital Course

The patient was admitted for fever and presumed infection. Although there had been initial improvement with supportive care, the patient suddenly developed worsening dyspnea. Repeat evaluation of vital signs revealed a heart rate of 120 bpm, a blood pressure of 73/47 mm Hg, and an oxygen saturation of 80% without supplemental oxygen. Supplemental oxygen was administered via a non-rebreather mask. Blood cultures taken on admission revealed gram-positive cocci in all 4 culture bottles. The patient continued to deteriorate, with persistent hypotension and hypoxemia. Intravenous (IV) vancomycin (1 g), aztreonam (2 g), and heparin (initial bolus of 80 IU/kg, followed by infusion of 18 IU/kg/hr) were administered. The patient was managed according to early goal-directed therapy (consisting of aggressive optimization of volume status, central venous and arterial blood pressure, central venous oxygen saturation, and hematocrit)[7] and was admitted to the intensive care unit. She became increasingly hypoxemic and was subsequently intubated on hospital day 1 and ventilated according to Acute Respiratory Distress Syndrome (ARDS) Network protocol.[8] Repeat ultrasonography showed absence of fetal heart tones. A chest radiograph taken on hospital day 2 showed diffuse patchy opacities consistent with multifocal pneumonia or ARDS (**Figure 1**). Results of liver function tests indicated hypotensive liver injury, while the hematocrit and platelet count dropped and the international normalized ratio rose due to progressive DIC (Table).

Norepinephrine and dobutamine were initiated for refractory shock with a central venous oxygen saturation of 50%, and phenylephrine and vasopressin were administered to provide hemodynamic support. Infectious disease consultants recommended the addition of clindamycin 600 mg and IV immunoglobulin 150 mg/kg/day for maximal treatment of probable *Streptococcus pneumoniae* sepsis. As group A streptococci, staphylococci, and enterococci were also considered, the patient was started on gentamycin 60 mg IV 3 times daily. Activated IV drotrecogin alpha (24 μg/kg/hr) was given for severe septic shock,[9] and stress-dose steroids (50 mg hydrocortisone IV 4 times daily) were added.[10] Due to concern that the source of infection could be intrauterine, emergent dilatation and evacuation was performed on hospital day 3, which necessitated the transfusion of 12 U of fresh frozen plasma and 10 U of packed red blood cells. Venous lactate levels peaked on day 3, which was attributed to severe sepsis (Table).

Howell-Jolly bodies, acanthocytes, giant platelets, and target cells, consistent with the diagnosis of hyposplenism, were noted on the peripheral blood smear. The patient's serum IgA tissue transglutaminase titer was elevated at 36 U/mL (normal, < 20 U/mL), which suggested incompletely treated celiac disease. Microbiology speciated the organism, cultured from blood drawn on hospital day 1, to be *Streptococcus pneumoniae* that was sensitive to all antibiotics tested.

Resolution and Follow-up

Drotrecogin alpha was stopped after 96 hours (hospital day 5), and the patient was weaned off the vasopressors and inotropes on day 6. The patient mounted a significant leukemoid reaction, with the white blood cell count peaking at $68 \times 10^3/\mu L$ on day 7, before improving. Serum creatinine levels rose to 7.6 mg/dL by day 14 due to multi-organ dysfunction (Table). Although the patient initially required continuous veno-venous hemofiltration and intermittent hemodialysis, her renal function slowly recovered. She was transferred to the medical floor on day 14 and was discharged in good condition on hospital day 23. After discharge, she underwent duodenal biopsy confirming celiac disease (**Figure 2**), and a radionucleotide scan revealed no evidence of functional splenic tissue (**Figure 3**). She has since received extensive counseling by a nutritionist trained in celiac disease and is expecting another baby.

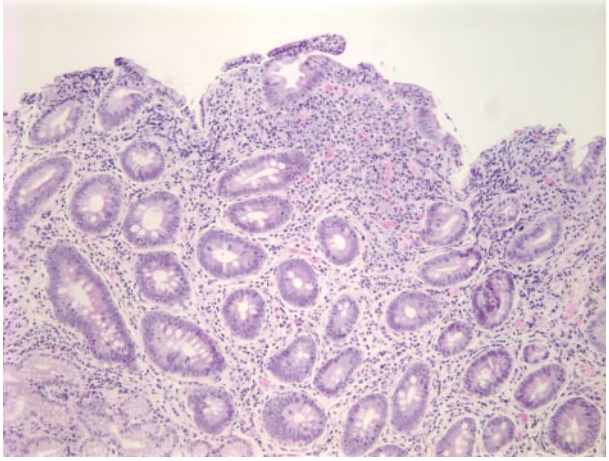

Figure 2. The patient underwent small bowel biopsy of duodenal mucosa, which demonstrated the absence of villi, presence of inflammatory cells in the lamina propria, and increased lymphocytes in the surface epithelium (hematoxylin and eosin stain, 10×).

DISCUSSION

This article presents a patient with known celiac disease who experienced overwhelming pneumococcal septic shock and resultant multi-organ system failure. To our knowledge, only a few cases of pneumococcal sepsis in celiac patients have been reported in the literature.[11–13] In all cases the incidents proved fatal, with the exception of a single case of pneumococcal meningitis that resulted in significant disability.[13] It is difficult to discern what factors were responsible for the survival of our patient. She may have benefited from multiple recent advances in critical care (eg, early goal-directed therapy,[7] activated protein C [drotrecogin alpha], lung protective ventilation, and intensive glucose control) that were utilized in combination with traditional use of vasopressors, head of bed elevation, stress ulcer and deep vein thrombosis prevention, and appropriate antibiotics. In addition, the patient was young and had no comorbidities other than celiac disease.

Infection and Celiac Disease

Aside from case reports, the literature examining the relationship between infection and celiac disease is scarce. Two studies found a higher incidence of urinary tract infections in individuals with celiac disease,[14,15] while another 2 studies reported an increased prevalence of tuberculosis[16] and cavitary lung disease,[17] with most cases of cavitary lung disease being caused by infections. The best evidence that patients with celiac disease may have increased susceptibility for severe infection comes from 2 studies of similar design. Logan et al[18] evaluated 653 patients with celiac disease and found a 1.9-fold increase in mortality, with 2 documented cases of death from sepsis, as compared with the general population. Subsequently, a Swedish registry of hospitalized patients found that patients with celiac disease had a 2-fold increase in overall mortality and a 2.9-fold increased mortality from all infectious causes (defined as infections and parasitic conditions, tuberculosis, and septicemia) as compared with the general population; death from sepsis alone was increased 7.1-fold in patients with celiac disease.[19]

Given that celiac disease is associated with increased intestinal permeability, malabsorption, and hyposplenism, it is not surprising that there is an increased risk of infectious complications in this population. Using the data currently available, it is not possible to definitively quantify the increased risk of infectious complications in celiac disease or the degree to which the factors listed above contribute to this risk. However, between 33% and 76% of adult patients with celiac disease are reported to have reduced splenic function,[5,6,20] which is a risk factor for developing severe or potentially fatal infection due to impaired blood filtration, immune surveillance, and antibody production.

The pathophysiology of splenic dysfunction in celiac disease is not well understood but is directly correlated to an increased age at initiation of a gluten-free diet[21] and seems to be unrelated to a wider reticuloendothelial dysfunction.[22] Although splenic atrophy is likely to be irreversible,[23,24] milder splenic dysfunction may be improved with a gluten-free diet.[25]

Management of Hyposplenism in Celiac Disease

Because hyposplenism is common in patients with

Figure 3. 99m-Technetium-labeled radionucleotide scan of the case patient after discharge demonstrated normal uptake in the liver, heart, and abdominal vessels. There was no activity in the right upper quadrant or abnormal activity elsewhere to suggest functional ectopic splenic tissue.

celiac disease and has the potential for serious or even fatal clinical consequences, individuals with celiac disease and health care providers caring for them should be aware of this risk and consider further testing or steps to prevent infection. Given the cost, efficacy, and safety profile of the pneumococcal vaccine, it seems reasonable to recommend immunization to all patients with celiac disease older than 50 years. Alternatively, Howell-Jolly bodies have been shown to have reasonable sensitivity for detecting impaired splenic function in this population,[26] and blood smear could be routinely evaluated in celiac patients. The presence of blood smear abnormalities or clinical factors such as a history of severe infections should prompt further testing and vaccination.

For patients who are known to be asplenic or hyposplenic, the foundation of management is education, vaccination, and antibiotic prophylaxis.[27] Patients with celiac disease should be educated regarding the potential risks of impaired splenic function and offered testing. If found to be hyposplenic, patients should be encouraged to wear a Medic-Alert bracelet or necklace, carry a wallet card with clinical details, and inform all health care providers (including dentists) of this condition. Also, individuals should seek prompt medical attention for any illness, especially if it involves fevers or rigors. All individuals with impaired splenic function should receive the pneumococcal vaccine at diagnosis, and vaccination should be repeated every 5 to 10 years. One small study, which did not address splenic function, found that patients with celiac disease have an appropriate response to the pneumococcal vaccine.[28] The benefits of *Haemophilus influenzae*, meningococcal, and influenza vaccines are less clear, but these vaccines should probably also be administered. Antibiotic prophylaxis is not generally recommended for adults with impaired splenic function; however, authorities recommend that individuals keep a supply of antipneumococcal antibiotics for use at symptom onset and/or if medical care is delayed.[27]

CONCLUSION

With the increasing prevalence of diagnosed celiac disease, many physicians will find themselves caring for individuals with this disorder. Although celiac disease is primarily a gastrointestinal disorder, it affects multiple organs and care of these patients should be multifaceted. Given that hyposplenism appears to be a common phenomenon in individuals with celiac disease and that hyposplenism may predispose patients to life-threatening infection, it is important for physicians to be aware of this link in order to appropriately manage these patients and reduce the risk of poor or fatal outcomes. **HP**

REFERENCES

1. Farrell RJ, Kelly CP. Celiac sprue. N Engl J Med 2002; 346:180–8.
2. Leffler D, Saha S, Farrel RJ. Celiac disease. Am J Manag Care 2003;9:825–33.
3. Fasano A, Berti I, Gerarduzzi T, et al. Prevalence of celiac disease in at-risk and not-at-risk groups in the United States: a large multicenter study. Arch Intern Med 2003;163:286–92.
4. Not T, Horvath K, Hill ID, et al. Celiac disease risk in the USA: high prevalence of antiendomysium antibodies

in healthy blood donors. Scand J Gastroenterol 1998; 33:494–8.
5. Corazza GR, Bullen AW, Hall R, et al. Simple method of assessing splenic function in coeliac disease. Clin Sci (Lond) 1981;60:109–13.
6. O'Grady JG, Stevens FM, Harding B, et al. Hyposplenism and gluten-sensitive enteropathy. Natural history, incidence, and relationship to diet and small bowel morphology. Gastroenterology 1984;87:1326–31.
7. Rivers E, Nguyen B, Havstad S, et al. Early goal-directed therapy in the treatment of severe sepsis and septic shock. Early Goal-Directed Therapy Collaborative Group. N Engl J Med 2001;345:1368–77.
8. Ventilation with lower tidal volumes as compared with traditional tidal volumes for acute lung injury and the acute respiratory distress syndrome. The Acute Respiratory Distress Syndrome Network. N Engl J Med 2000; 342:1301–8.
9. Dhainaut JF, Laterre PF, Janes JM, et al. Drotrecogin alfa (activated) in the treatment of severe sepsis patients with multiple-organ dysfunction: data from the PROWESS trial. Intensive Care Med 2003;29:894–903.
10. Annane D, Sebille V, Charpentier C, et al. Effect of treatment with low doses of hydrocortisone and fludrocortisone on mortality in patients with septic shock. JAMA 2002;288:862–71.
11. Johnston SD, Robinson J. Fatal pneumococcal septicaemia in a coeliac patient. Eur J Gastroenterol Hepatol 1998;10:353–4.
12. O'Donoghue DJ. Fatal pneumococcal septicaemia in coeliac disease. Postgrad Med J 1986;62:229–30.
13. McKay PJ, Kennedy DH, Lucie NP. Should hyposplenic patients receive prophylaxis against bacterial infection? Scott Med J 1993;38:51–2.
14. Saalman R, Fallstrom SP. High incidence of urinary tract infection in patients with coeliac disease. Arch Dis Child 1996;74:170–1.
15. Fanos V, Verlato G, Matti P, et al. Increased incidence of urinary tract infections in patients with coeliac disease [letter]. Pediatr Nephrol 2002;17:570–1.
16. Stevens FM, Connolly CE, Murray JP, McCarthy CF. Lung cavities in patients with coeliac disease. Digestion 1990;46:72–80.
17. Williams AJ, Asquith P, Stableforth DE. Susceptibility to tuberculosis in patients with coeliac disease. Tubercle 1988;69:267–74.
18. Logan RF, Rifkind EA, Turner ID, Ferguson A. Mortality in celiac disease. Gastroenterology 1989;97:265–71.
19. Peters U, Askling J, Gridley G, et al. Causes of death in patients with celiac disease in a population-based Swedish cohort. Arch Intern Med 2003;163:1566–72.
20. Corazza GR, Zoli G, Di Sabatino A, et al. A reassessment of splenic hypofunction in celiac disease. Am J Gastroenterol 1999;94:391–7.
21. Robinson PJ, Bullen AW, Hall R, et al. Splenic size and function in adult coeliac disease. Br J Radiol 1980; 53:532–7.
22. Palmer KR, Barber DC, Sherriff SB, Holdsworth CD. Reticuloendothelial function in coeliac disease and ulcerative colitis. Gut 1983;24:384–8.
23. Trewby PN, Chipping PM, Palmer SJ, et al. Splenic atrophy in adult coeliac disease: is it reversible? Gut 1981;22:628–32.
24. Corazza GR, Frisoni M, Vaira D, Gasbarrini G. Effect of gluten-free diet on splenic hypofunction of adult coeliac disease. Gut 1983;24:228–30.
25. Magalotti D, Volta U, Bonfiglioli A, et al. Splanchnic haemodynamics in patients with coeliac disease: effects of a gluten-free diet. Dig Liver Dis 2003;35:262–8.
26. Corazza GR, Ginaldi L, Zoli G, et al. Howell-Jolly body counting as a measure of splenic function. A reassessment. Clin Lab Haematol 1990;12:269–75.
27. Brigden ML. Detection, education, and management of the asplenic or hyposplenic patient. Am Fam Physician 2001;63:499–506, 508.
28. McKinley M, Leibowitz S, Bronzo R, et al. Appropriate response to pneumococcal vaccine in celiac sprue. J Clin Gastroenterol 1995;20:113–6.

Copyright 2006 by Turner White Communications Inc., Wayne, PA. All rights reserved.