Cerebrovascular Thrombosis from Protracted Epoetin Alfa Use in a Patient with Chronic Hepatitis C Infection

Rui Yu, MD
Robert W. Chang, MD
Glenn T. Nagami, MD

Since its approval for human use in 1989, epoetin alfa has revolutionized the treatment of anemia due to chronic kidney disease, cancer chemotherapy and/or cancer itself, and HIV infection. Based on this success, epoetin alfa has been used to treat anemia that occurs in numerous other conditions, such as anemia resulting from treatment of chronic hepatitis C. Although usually well-tolerated, epoetin alfa therapy is associated with adverse effects, most commonly headache and elevated blood pressure. Rarely, thrombotic events may occur. This article discusses the case of a man who developed cerebrovascular thrombosis due to prolonged high-dose epoetin alfa treatment for anemia resulting from therapy for chronic hepatitis C. A review of the benefits and adverse events associated with use of epoetin alfa for treating anemia associated with nonmalignant gastrointestinal disorders is also provided. A discussion of darbepoetin, which has similar indications, benefits, and side effects to epoetin alfa, is beyond the scope of this review.

CASE PRESENTATION

History of Presenting Complaint

A 57-year-old man presented to the emergency department (ED) with a 3-day history of confusion and 6- to 7-week history of generalized headaches. The patient's past medical history was significant for atrial fibrillation, long-standing hypertension, depression, and chronic hepatitis C. During a 7-week period prior to the patient's current presentation to the ED, he was evaluated in the urgent care setting on several occasions for his generalized headaches, which were deemed to be tension-type headaches. Three days before admission, he presented again to urgent care for headaches and elevated blood pressure, which the patient reported as ranging from 140 to 160 mm Hg systolic blood pressure. His outpatient antihypertensive regimen was simplified and further optimized. Dosing adjustments included changing metoprolol from 100 mg 3 times daily to 150 mg twice daily, changing diltiazem 120 mg 4 times daily to diltiazem SA 480 mg daily, and increasing benazepril from 20 to 40 mg/day.

Past Medical History

As previously noted, the patient had a history of atrial fibrillation controlled with warfarin therapy (10 mg on Monday/Friday, 7.5 mg on the other days of the week), hypertension, depression (extended-release venlafaxine 75 mg/day orally), and chronic hepatitis C. The patient was diagnosed with hepatitis C 15 years earlier, with chronic hepatitis being diagnosed 9 years ago. Per biopsy, he was found to have genotype 2b and stage 3 liver disease. Proposed 24-week therapy with pegylated interferon and ribavirin was initiated approximately 7 months prior to the current presentation. Three weeks into his therapy, the patient developed anemia and was subsequently treated with subcutaneous epoetin alfa 40,000 U weekly. Complete blood counts were obtained at the hepatitis C clinic, initially every 1 to 2 weeks and then monthly. The patient completed 19 of the scheduled 24 weeks with a significant virologic response, from an initial viral load exceeding 5,900,000 copies/mL to fewer than 10 copies/mL. Due to hospitalization for pneumonia, he was unable to complete therapy and was lost to follow-up. The patient continued receiving epoetin alfa at 40,000 U weekly without interruption, with his last dose being administered 1 week prior to presentation.

Dr. Yu is a resident, Department of Medicine, and Dr. Chang is a fellow, Department of Nephrology, Cedars-Sinai Medical Center/VA Greater Los Angeles Healthcare System, Los Angeles, CA. Dr. Nagami is a professor of medicine, University of California Los Angeles, Los Angeles, CA; and chief, Nephrology Section, VA Greater Los Angeles Healthcare System.

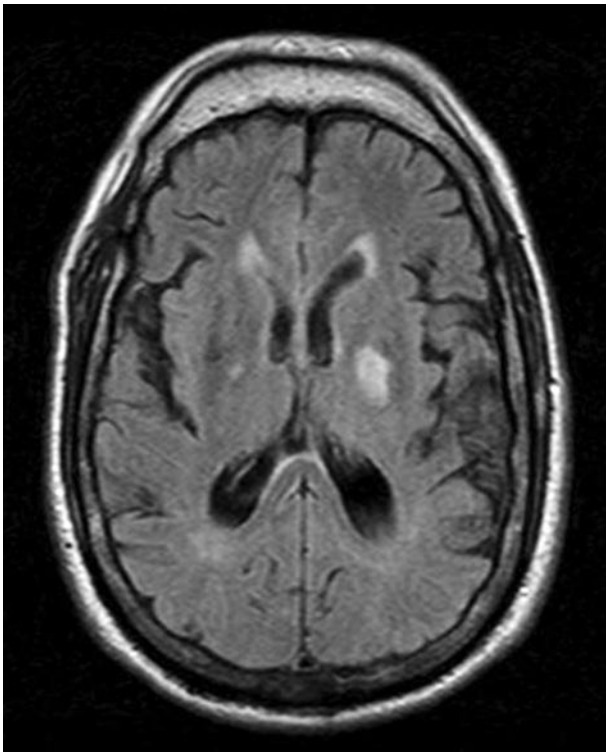

Figure. T2-weighted magnetic resonance image of the brain demonstrating an acute infarct in the left pons.

Presentation

The patient was initially brought into the ED by his wife. Upon presentation, the patient described a constant, generalized headache associated with nausea. His wife stated that the patient had been very lethargic and weak for the past several days. In addition, she observed symptoms of gait instability, difficulty with speech, and decreased alertness for the past 3 days. She denied that the patient had any recent head trauma, loss of consciousness, or seizure-like activity. On physical examination, he had a temperature of 97.3°F, blood pressure ranging from 150/100 to 170/110 mm Hg, and heart rate ranging from 50 to 60 bpm. In general, he was alert and oriented to person and time but not place and was in no acute distress. Cardiovascular examination revealed an irregularly irregular rhythm without evidence of murmurs, rubs, or gallops. Lungs were clear to auscultation and percussion. Abdominal examination was benign, and no edema of lower extremities was present. Laboratory studies including electrolyte panels and complete blood count were ordered. The patient was admitted to the general medicine service for work-up of his altered mental status.

Hospital Course

Upon admission, the patient's blood pressure measurements increased to between 190/100 and 210/120 mm Hg. The patient was oriented only to time. Otherwise, the physical examination (including a neurologic examination that showed no focal findings) was essentially unremarkable. Results of laboratory studies were significant for elevated hematocrit of 54% (normal, 41%–50%) and hemoglobin of 17.7 g/dL (normal, 14.0–17.5 g/dL), both of which had increased from values obtained approximately 1 month ago (respectively, 45% and 14.7 g/dL). International normalized ratio was 2.6, which was within the therapeutic range for atrial fibrillation treated with warfarin. A noncontrast computed tomography (CT) scan of the brain revealed no masses, infarcts, midline shifts, or intracranial bleeds. All of his outpatient antihypertensive medications were continued with the addition of intravenous hydralazine 10 mg, but his blood pressure did not decrease.

The patient was subsequently transferred to a monitored setting in the intensive care unit for intravenous nitroglycerin therapy that resulted in blood pressure measurements ranging from 120/100 to 150/100 mm Hg within 12 hours. On hospital day 2, he was converted back to his oral antihypertensive regimen and was transferred to the general service. His wife, however, noted minimal improvement in his mental status. Over the next 2 days, he became more disoriented. The hematocrit levels rose, peaking at a value of 57%. Given his recent episodes of hypertension in the ED despite medical therapy that previously controlled his symptoms, duplex ultrasound was ordered but showed no evidence of renal artery stenosis. As polycythemia and hyperviscosity from long-standing high-dose epoetin alfa treatment may have contributed to his clinical condition, the patient underwent a series of therapeutic phlebotomies with intravascular fluid support on hospital days 4 and 6. Despite these treatments, the patient developed a facial droop, dysarthria, and blurred vision. Magnetic resonance imaging of the brain taken on hospital day 7 revealed new infarcts of the globus pallidus and the left dorsal pons (**Figure**). On hospital day 9, a contrast-enhanced CT scan of the brain revealed interval changes consistent with bilateral infarctions in the anterior cerebral artery distribution. The patient eventually became unresponsive and hypotensive with respiratory comprise necessitating intubation. The patient's condition did not improve, and his family eventually decided to withdraw life support. The patient died on hospital day 19.

DISCUSSION

Given this patient's medical history and his presenting symptoms that included neurologic abnormalities and a relatively rapid rise in blood pressure and hemoglobin as well as hematocrit levels, the initial diagnostic consideration was an intracranial lesion or hemorrhage. A head CT scan taken on admission, however, was negative for any intracranial process. Secondary causes of hypertension were subsequently evaluated. However, pheochromocytoma was unlikely given the patient's clinical history (eg, no intermittent hypertension, flushing, or palpitations). Ultrasound of the renal vasculature obtained early during the hospitalization was also negative for renal artery stenosis. Once these causes were ruled out and the patient's medical records were thoroughly reviewed on hospital days 2 and 3, it became evident that prolonged epoetin alfa use was the most likely cause of polycythemia in this patient. Despite therapeutic phlebotomy, his neurologic symptoms worsened soon after these measures were employed, and magnetic resonance imaging demonstrated the presence of multiple infarcts.

EPOETIN ALFA

Anemia due to a chronic disease or its treatment may result from decreased red blood cell production, increased hemolysis, and/or blood loss, and more than 1 pathophysiologic mechanism may exist in an individual patient.[1] In chronic hepatitis C treated with combination therapy, anemia is caused by bone marrow suppression associated with interferon-α use (decreased red blood cell production) and hemolysis associated with ribavirin use,[2] which is thought to be caused by oxidative stress to erythrocyte membranes and mitochondrial toxicity through the depletion of adenosine triphosphate.[3] Treatment with epoetin alfa acts similarly to endogenous erythropoietin, which is produced by the peritubular capillary lining cells in the kidneys and is responsible for stimulating erythropoiesis in the bone marrow. Epoetin alfa significantly increases hemoglobin levels in chronic hepatitis C patients who have received interferon and ribavirin,[4,5] which permits maintenance of a higher time-averaged ribavirin dose as compared with those treated with blood transfusions and temporary ribavirin dose reductions.[6,7] Other benefits of treating anemia with epoetin alfa include reduced need for transfusions[6,7] and, possibly, improved quality of life.[5]

Adverse Effects Associated with Epoetin Alfa

Although therapy with epoetin alfa has been proven beneficial in many conditions, it also has been linked to adverse effects in patients receiving chronic therapy. The following discusses major adverse effects associated with chronic epoetin alfa therapy in nonmalignant gastrointestinal disorders and measures that may be taken to prevent these effects.

Hypertension. A well-documented side effect of chronic epoetin alfa administration in chronic renal failure patients is hypertension, particularly a rise in diastolic blood pressure of over 10 mm Hg. Hypertension associated with epoetin alfa use is thought to be caused by hematocrit-dependent and -independent mechanisms.[8] Increased viscosity and enhanced vascular reactivity with correction of vascular tissue hypoxia may be mediated by the increased hematocrit value, especially in patients with preexisting hypertension.[8] Epoetin alfa may also cause vasoconstriction,[9] which may be mediated by increased endothelin production,[10,11] possible changes in vascular tissue prostaglandin production,[12] and up-regulation of tissue renin and angiotensinogen expression.[12] Rarely, dramatic increases in blood pressure, hypertensive encephalopathy, or seizures have been described with protracted epoetin alfa therapy.[13] Predisposing factors to these complications include a history of hypertension and prolonged epoetin alfa use at high doses.[8,14] The case patient had both predisposing factors, which may have contributed to the development of hypertension in a patient whose hypertension had previously been well controlled.

Thrombotic events. Of more concern is the association of thrombotic events with epoetin alfa use, especially in chronic renal failure patients. Numerous studies such as those performed by Besarab et al,[12] Casati et al,[15] and Muirhead et al[16] have shown increased rates of arteriovenous access thrombosis when epoetin alfa has restored near-normal to normal hemoglobin levels. The US Normal Hematocrit Study also described a higher thrombosis rate in dialysis patients with synthetic grafts and natural fistulas who were targeted to a higher hematocrit value.[12]

Although mechanisms for increased thrombotic events are not entirely understood, increased blood viscosity, changes in platelet function, and changes in vascular cell function have been implicated. Higher hematocrit and red blood cell mass result in increased blood viscosity with epoetin alfa[14,17] and may be associated with increased thrombotic events even in apparently normal individuals.[18] Epoetin alfa may not only have a small effect on the platelet count but may also increase platelet activation.[19,20] Stohlawetz et al[20] demonstrated that epoetin alfa infusion activated platelets in normal healthy volunteers. The activation of platelets by epoetin alfa may result from enhanced intracellular calcium

signaling within platelets.[21–24] Endothelial cell prothrombotic factors[25] (including endothelin[10,26] and plasminogen activator inhibitor 1[27]) are increased with epoetin alfa use, which may increase the risk of thrombotic events in these individuals. Vaziri[1] described in vitro evidence that epoetin alfa may support vascular cell growth and proliferation, possibly promoting vascular lesions that can cause thrombosis.

Cerebrovascular thrombosis has been rarely described as a complication of protracted epoetin alfa therapy. Casati et al[15] reported 1 patient who developed reversible focal cerebral ischemia after receiving dose-adjusted intravenous epoetin alfa, with an increase in hemoglobin concentration from 6.5 to 12.2 g/dL. In a study that included 596 hemodialysis patients, Parfrey et al[28] showed a threefold increase in cerebrovascular events in those randomly assigned to hemoglobin concentrations of 13.5 to 14.5 g/dL (n = 12) versus 9.5 to 11.5 g/dL (n = 4). Kooistra et al[29] reported 3 hemodialysis patients who were not at risk for thrombovascular disease and who developed cerebral strokes after epoetin alfa therapy. Finelli and Carley[13] described a 37-year-old peritoneal dialysis patient receiving chronic epoetin alfa therapy whose hematocrit levels increased to 55% and who subsequently presented with headaches caused by thrombosis of the sagittal and transverse sinus. Thrombotic events associated with epoetin alfa therapy may not be limited to patients who are on dialysis. Afdhal et al[7] reported a double-blind study of 185 patients who developed anemia while receiving combination interferon and ribavirin therapy and who were given either epoetin alfa (40,000 U subcutaneously) or placebo. The 1 serious adverse effect observed in the epoetin alfa treatment group was a cerebrovascular accident in a patient whose hemoglobin increased to 14 g/dL. It should be observed that treatment with pegylated interferon has been reported to be associated with thrombotic events.[30,31] However, pegylated interferon is unlikely to be responsible for the case patient's adverse events, as he was no longer receiving interferon therapy when he experienced cerebrovascular thrombosis.

Hemoglobin and hematocrit are the main determinants of oxygen-carrying capacity and blood viscosity. With continued rises in hemoglobin concentration and hematocrit, a point will be reached where oxygen delivery diminishes because of the decline in blood flow due to increased viscosity. Johnson et al[17] described an inverse relationship between cerebral blood flow and blood viscosity/hemoglobin concentration. As seen in this case, the continued rise in hematocrit value from prolonged therapy with high-dose epoetin alfa may have increased blood viscosity and decreased cerebral blood flow, which was manifested in the patient's symptoms of headaches and confusion. Ultimately, increased blood viscosity and decreased cerebral blood flow may have resulted in the patient's progressive cerebral infarcts.

Prevention

Currently, no uniformly accepted upper limit on hemoglobin concentration has been established when using epoetin alfa therapy (**Table**).[32–40] However, normalization of hemoglobin levels has been identified with adverse effects. In both the US Normal Hematocrit Study[12] and the CHOIR trial,[41] patients with advanced chronic kidney disease (both predialysis and dialysis-dependent patients) had increased rates of adverse cardiovascular events without an increased quality of life benefit when hemoglobin levels were targeted for normalization. However, the CREATE trial[42] from European and Asian centers demonstrated that normalizing hemoglobin levels confers a significant quality of life benefit and, with the exception of hypertension, causes no clear increased risk for cardiovascular events. The observed differences in cardiovascular outcomes between these 2 studies[12,41] and the CREATE trial[42] may reflect differences in the patient populations studied or differences in exclusion criteria for preexisting cardiovascular conditions used in these trials.

Given the ever-expanding indications of epoetin alfa therapy, several clinical practice guidelines for a target hemoglobin level have been instituted by various organizations for treating patients with anemia (Table).[32–40] Based upon these clinical practice guidelines, a target hemoglobin level of 12 g/dL seems to be the working consensus to avoid the aforementioned adverse effects. Equally important is the frequency of hemoglobin monitoring. According to the National Kidney Foundation Kidney Disease Outcomes Quality Initiative guidelines,[36] hemoglobin levels should be monitored at least monthly to determine dose adjustments accurately. Patients with unstable and above-target hemoglobin levels require more frequent monitoring (either weekly or biweekly monitoring). The case patient appeared to have good follow-up at the hepatitis C clinic until he was hospitalized with pneumonia. Afterwards, he did not have any further appointments at the clinic, and his many providers did not change or stop therapy with epoetin alfa. This case emphasizes the importance of ensuring that patients understand the potential adverse effects of their medications and the necessity for follow-up visits.

In addition to achieving target or near target hemoglobin levels, regular monitoring of hemoglobin

levels, and as-needed epoetin alfa dose adjustments, it is important to remain alert to symptoms and signs of adverse events that can be associated with therapy. Headaches can be a common side effect of epoetin alfa therapy. When headaches, progressive mental status changes, and polycythemia are observed together, cerebrovascular ischemia and thrombosis should be suspected in an individual who is receiving epoetin alfa.[13]

CONCLUSION

Epoetin alfa has been used to treat chronic anemia with great success and has been generally well tolerated, with headache and elevations in blood pressure being the most common adverse effects. However, prolonged use of epoetin alfa can result in serious effects with significant morbidity and mortality, such as cerebrovascular thrombosis. Frequent monitoring of blood counts must become routine in any patient on epoetin alfa; physicians should clearly explain the risks of this therapy as well as the necessity for regular follow-up appointments. Several guidelines are available to assist clinicians in achieving a target hemoglobin range where epoetin alfa can be used safely. **HP**

Corresponding author: Glenn T. Nagami, MD, VA Greater Los Angeles Healthcare System, Nephrology Section 111L, 11301 Wilshire Boulevard, Los Angeles, CA 90073; glenn.nagami@va.gov.

Table. Various Recommended Target Hemoglobin Levels for Anemic Patients

Clinical Practice Guideline	Target Hemoglobin (g/dL)
JSDT[32]	For dialysis patients with CKD: Adults, 10–11 Relatively young patients, 11–12
ASCO/ASH[33]	Hemoglobin must be < 10 to initiate therapy; target should be lowest hemoglobin concentration that avoids transfusion
NCCN[34]	Hemoglobin must be < 10 to initiate therapy
EORTC[35]	12–13
KDOQI[36]	11–12
NDT[37]	For patient with a NYHA score above 3, < 12; for type 2 diabetes patients with peripheral vascular disease, > 11; levels should be individualized for patients with CKD
CSN[38]	11–12
UK CKD[39]	11–12
CARI[40]	12

ASCO/ASH = American Society of Clinical Oncology/American Society of Hematology; CARI = Caring for Australasians with Renal Impairment; CKD = chronic kidney disease; CSN = Canadian Society of Nephrology; EORTC = European Organization for Research and Treatment of Cancer; JSDT = Japanese Society for Dialysis Therapy; KDOQI = Kidney Disease Outcomes Quality Initiative; NCCN = National Comprehensive Cancer Network; NDT = Nephrology Dialysis Transplantation; NYHA = New York Heart Association; UK CKD = United Kingdom Guidelines for the management of Chronic Kidney Disease.

REFERENCES

1. Vaziri ND. Cardiovascular effects of erythropoietin and anemia correction. Curr Opin Nephrol Hypertens 2001;10:633–7.
2. Kowdley KV. Hematologic side effects of interferon and ribavirin therapy. J Clin Gastroenterol 2005;39(1 Suppl):S3–8.
3. Foley RN, Parfrey PS, Morgan J, et al. Effect of hemoglobin levels in hemodialysis patients with asymptomatic cardiomyopathy. Kidney Int 2000;58: 1325–35.
4. Collantes RS, Younossi ZM. The use of growth factors to manage the hematologic side effects of PEG-interferon alfa and ribavirin. J Clin Gastroenterol 2005;39(1 Suppl):S9–13.
5. Afdhal NH. Role of epoetin alfa in maintaining ribavirin dose. Gastroenterol Clin North Am 2004;33(1 Suppl):S25–35.
6. Dieterich DT, Wasserman R, Brau N, et al. Once-weekly epoetin alfa improves anemia and facilitates maintenance of ribavirin dosing in hepatitis C virus-infected patients receiving ribavirin plus interferon alfa. Am J Gastroenterol 2003;98:2491–9.
7. Afdhal NH, Dieterich DT, Pockros PJ, et al; Proactive Study Group. Epoetin alfa maintains ribavirin dose in HCV-infected patients: a prospective, double-blind, randomized controlled study. Gastroenterology 2004;126:1302–11.
8. Maschio G. Erythropoietin and systemic hypertension. Nephrol Dial Transplant 1995;10 Suppl 2:74–9.
9. Heidenreich S, Rahn KH, Zidek W. Direct vasopressor effect of recombinant human erythropoietin on renal resistance vessels. Kidney Int 1991;39:259–65.
10. Katoh K, Mizuno K, Hashimoto S, et al. Direct evidence for erythropoietin-induced release of endothelin from peripheral vascular tissue. Life Sci 1994; 54:PL253–9.
11. Carlini RG, Gupta A, Liapis H, Rothstein M. Endothelin-1 release by erythropoietin involves calcium signaling in endothelial cells. J Cardiovasc Pharmacol 1995;26:889–92.
12. Besarab A, Bolton WK, Browne JK, et al. The effects of normal as compared with low hematocrit values in patients with cardiac disease who are receiving hemodialysis and epoetin. N Engl J Med 1998;339:584–90.
13. Finelli PF, Carley MD. Cerebral venous thrombosis associated with epoetin alfa therapy. Arch Neurol 2000;57:260–2.
14. Lebel M, Kingma I, Grose JH, Langlois S. Hemodynamic and hormonal changes during erythropoietin therapy in hemodialysis patients. J Am Soc Nephrol 1998;9:97–104.
15. Casati S, Passerini P, Campise MR, et al. Benefits and risks of protracted treatment with human recombinant erythropoietin in patients having haemodialysis. Br Med J (Clin Res Ed) 1987;295:1017–20.
16. Muirhead N, Laupacis A, Wong C. Erythropoietin for anemia in haemodialysis patients: results of a maintenance study (the Canadian Erythropoietin Study Group). Nephrol Dial Transplant 1992;7:811–6.
17. Johnson WJ, McCarthy JT, Yanagihara T, et al. Effects of recombinant human erythropoietin on cerebral and cutaneous blood flow and on blood coagulability. Kidney Int 1990;38:919–24.
18. Shaskey DJ, Green GA. Sports haematology. Sports Med 2000;29:27–38.
19. Taylor JE, Henderson IS, Stewart WK, Belch JJ. Erythropoietin and spontaneous platelet aggregation in haemodialysis patients. Lancet 2006;338:1361–2.
20. Stohlawetz PJ, Dzirlo L, Hergovich N, et al. Effects of erythropoietin on platelet reactivity and thrombopoiesis in humans. Blood 2000;95:2983–9.
21. Van Geet C, Van Damme-Lombaerts R, Vanrusselt M, et al. Recombinant human erythropoietin increases blood pressure, platelet aggregability and platelet free calcium mobilisation in uraemic children: a possible link? Thromb Haemost 1990;64:7–10.
22. Tepel M, Wischniowski H, Zidek W. Erythropoietin increases cytosolic free calcium concentration and thrombin induced changes in cytosolic free calcium in platelets from spontaneously hypertensive rats. Biochem Biophys Res Commun 1991;177:991–7.
23. Fluck RJ, Roger SD, McMahon AC, Raine AE. Modulation of platelet cytosolic calcium during erythropoietin therapy in uraemia. Nephrol Dial Transplant 1994;9:1109–14.
24. Zhou XJ, Vaziri ND. Defective calcium signalling in uraemic platelets and its amelioration with long-term erythropoietin therapy. Nephrol Dial Transplant

2002;17:992–7.
25. Cines DB, Pollak ES, Buck CA, et al. Endothelial cells in physiology and in the pathophysiology of vascular disorders. Blood 1998;91:3527–61.
26. Carlini RG, Dusso AS, Obialo CI, et al. Recombinant human erythropoietin (rHuEPO) increases endothelin-1 release by endothelial cells. Kidney Int 1993; 43:1010–4.
27. Nagai T, Akizawa T, Kohjiro S, et al. rHuEPO enhances the production of plasminogen activator inhibitor-1 in cultured endothelial cells. Kidney Int 1996; 50:102–7.
28. Parfrey PS, Foley RN, Wittreich BH, et al. Double-blind comparison of full and partial anemia correction in incident hemodialysis patients without symptomatic heart disease. J Am Soc Nephrol 2005;16:2180–9.
29. Kooistra MP, van Es A, Marx JJ, et al. Low-dose aspirin does not prevent thrombovascular accidents in low-risk haemodialysis patients during treatment with recombinant human erythropoietin. Nephrol Dial Transplant 1994;9: 1115–20.
30. Goncalves LL, Farias AQ, Goncalves PL, et al. Branch retinal vein thrombosis and visual loss probably associated with pegylated interferon therapy of chronic hepatitis C. World J Gastroenterol 2006;12:4602–3.
31. Zandieh I, Adenwalla M, Cheong-Lee C, et al. Retinal vein thrombosis associated with pegylated-interferon and ribavirin combination therapy for chronic hepatitis C. World J Gastroenterol 2006;12:4908–10.
32. Gejyo F, Saito A, Akizawa T, et al; Japanese Society for Dialysis Therapy. 2004 Japanese Society for Dialysis Therapy guidelines for renal anemia in chronic hemodialysis patients. Ther Apher Dial 2004;8:443–59.
33. Rizzo JD, Somerfield MR, Hagerty KL, et al. Use of epoetin and darbepoetin in patients with cancer: 2007 American Society of Clinical Oncology/American Society of Hematology clinical practice guideline update [published erratum appears in Clin Oncol 2008;26:1192]. J Clin Oncol 2008;26:132–49.
34. National Comprehensive Cancer Network. NCCN clinical practice guidelines in oncology. Cancer- and chemotherapy-induced anemia. V.1.2009. Available at www.nccn.org/professionals/physician_gls/PDF/anemia.pdf. Accessed 11 Aug 2008.
35. Bokemeyer C, Aapro MS, Courdi A, et al; European Organisation for Research and Treatment of Cancer (EORTC) Taskforce for the Elderly. EORTC guidelines for the use of erythropoietic proteins in anaemic patients with cancer: 2006 update. Eur J Cancer 2007;43:258–70.
36. KDOQI; National Kidney Foundation. KDOQI Clinical Practice Guidelines and Clinical Practice Recommendations for Anemia in Chronic Kidney Disease [published erratum appears in Am J Kidney Dis 2006;48:518]. Am J Kidney Dis 2007;47(5 Suppl 3):S11–145.
37. Jacobs C, Hörl WH, Macdougall IC, et al. European best practice guidelines 5: target haemoglobin. Nephrol Dial Transplant 2000;15 Suppl 4:15–9.
38. Barrett BJ, Fenton SS, Ferguson B, et al; Canadian Society of Nephrology. Clinical practice guidelines for the management of anemia coexistent with chronic renal failure. J Am Soc Nephrol 1999;10 Suppl 13:S292–6.
39. Burden R, Tomson C; Guideline Development Committee, Joint Specialty Committee on Renal Disease of the Royal College of Physicians of London and the Renal Association. Identification, management and referral of adults with chronic kidney disease: concise guidelines. Clin Med 2005;5:635–42.
40. Roger S; Caring for Australasians with Renal Impairment (CARI). The CARI guidelines. Haematological targets. Iron. Nephrology (Carlton) 2006; 11 Suppl 1:S217–29.
41. Singh AK, Szczech L, Tang KL, et al. Correction of anemia with epoetin alfa in chronic kidney disease. N Engl J Med 2006;355:2085–98.
42. Drueke TB, Locatelli F, Clyne N, et al. Normalization of hemoglobin level in patients with chronic kidney disease and anemia. N Engl J Med 2006; 355:2071–84.

Copyright 2008 by Turner White Communications Inc., Wayne, PA. All rights reserved.