Management of Chest Pain in the Emergency Department: Review Questions

Richard Regnante, MD
Wen-Chih Wu, MD

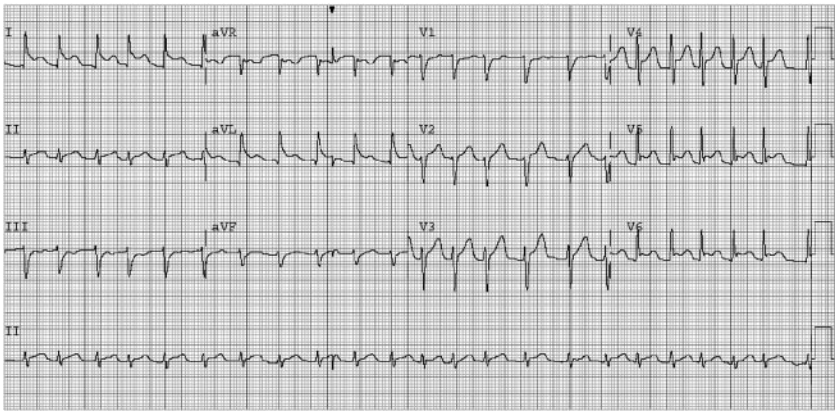

Figure 1. 12-Lead electrocardiogram performed in the case patient described in questions 1 and 2.

QUESTIONS

Choose the single best answer for each question.

Questions 1 and 2 refer to the following case.

A 39-year-old woman with no significant past medical history presents to the emergency department (ED) with chest discomfort that started the night before presentation. The chest discomfort is 3 out of 10 in intensity, constant and sharp in quality, is located in the mid-sternal region, and does not radiate. The discomfort worsens when she takes a deep breath or lies flat and, as a result, the patient slept sitting upright in a recliner the night prior. She incidentally reports having had a recent viral illness with symptoms of a runny nose, nonproductive cough, and myalgias 2 weeks ago. Vital signs include a temperature of 99.1°F, respiratory rate of 16 breaths/min, blood pressure of 135/79 mm Hg, and pulse oximetry of 99% on room air. Physical examination is unremarkable except for an irregular heart beat. A 12-lead electrocardiogram (ECG) is obtained (**Figure 1**). A chest radiograph is normal.

1. **In addition to treating the underlying arrhythmia, what is the next best step to improve this patient's symptoms?**
   (A) Administer a nonsteroidal anti-inflammatory drug (NSAID)
   (B) Administer chewable aspirin (325 mg) and activate the cardiac catheterization team
   (C) Administer intravenous (IV) thrombolytic therapy
   (D) Administer IV heparin bolus followed by an infusion for 48 hours

2. **Several hours after initial management, the patient's pain is markedly improved. A repeat ECG reveals a regular heart rhythm at 60 bpm. What is the next step in this patient's diagnostic evaluation?**
   (A) Admit to the coronary care unit (CCU) and immediately obtain a transthoracic echocardiogram
   (B) Admit to the CCU to rule out myocardial infarction (MI) and perform stress testing in the morning

Dr. Regnante is a clinical fellow in cardiology, Warren Alpert Medical School of Brown University, Providence, RI. Dr. Wu is an assistant professor of medicine, Providence VA Medical Center and Warren Alpert Medical School at Brown University, Providence, RI.

The views expressed in this article are those of the authors and do not necessarily reflect the position or policy of the Department of Veteran Affairs.

This work is supported by the Target Research Enhancement Program, Providence VA Medical Center, providing research time for Dr. Wu; and the Brown Fellowship Program.

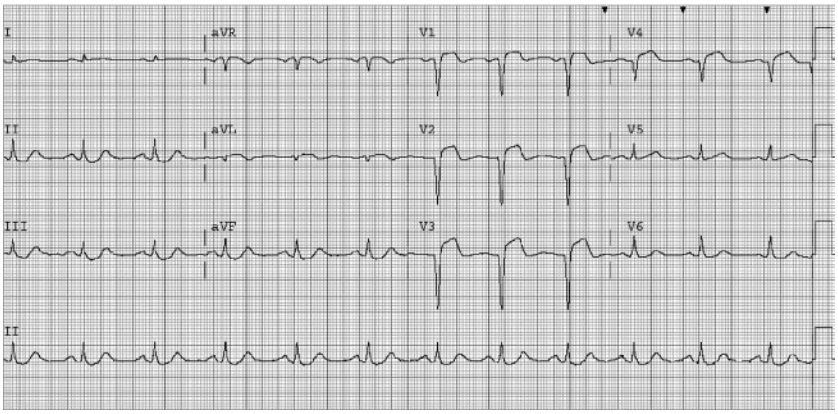

Figure 2. 12-Lead electrocardiogram performed in the case patient described in questions 3 and 4.

(C) Admit to the telemetry unit and obtain viral and Lyme titers and rheumatoid factor and antinuclear antibody levels
(D) Discharge home with echocardiography scheduled as an outpatient

Questions 3 and 4 refer to the following case.

A 79-year-old man with a history of type 2 diabetes mellitus, hypertension, hyperlipidemia, and tobacco abuse presents to the ED with discomfort across his left chest wall, radiating into his jaw and left arm. He notes that the pain began approximately 10 hours prior to admission and was initially mild, but it progressed in intensity and was associated with shortness of breath and diaphoresis, which prompted him to call 911. He was given an aspirin and sublingual nitroglycerin en route to the hospital. On presentation, he is still complaining of chest pain, appears ashen, and is visibly short of breath. Blood pressure is 110/88 mm Hg, respiratory rate is 22 breaths/min, and pulse oximetry is 90% on room air. Physical examination reveals jugular venous distention to the level of his jaw while sitting upright. Cardiac auscultation reveals a regular heart rhythm without murmurs and a loud S_4 gallop. Lung sounds are diminished at the bases with fine crackles bilaterally about a quarter of the way up. The remainder of the examination is unremarkable. The patient is immediately placed on oxygen. After transfer from the stretcher to the examination room, the patient's heart rate is 110 bpm with a blood pressure of 70/59 mm Hg. A 12-lead ECG is quickly obtained (**Figure 2**).

3. What is the next best step in this patient's management to improve his chances of survival?
(A) Activate the coronary intervention team for emergent cardiac catheterization within 90 minutes of first medical contact
(B) Administer IV thrombolytics and IV heparin within 30 minutes of arrival
(C) Start a glycoprotein IIb/IIIa inhibitor and IV heparin, admit to the CCU, and perform cardiac catheterization within the next 24 hours
(D) Wide-open IV fluids through 2 large-bore catheters, initiate IV dobutamine at 20 μg/kg/min, and immediately obtain a transthoracic echocardiogram

4. The patient's symptoms dramatically improve after the treatment. Symptoms do not recur during hospitalization, vital signs have stabilized, and he is ready for discharge 4 days later. On discharge, what is the ideal outpatient medication regimen for this patient?
(A) Aspirin, atenolol, ezetimibe, ramipril
(B) Aspirin, carvedilol, captopril, fenofibrate, subcutaneous enoxaparin
(C) Aspirin, clopidogrel, lisinopril, metoprolol, pravastatin
(D) Cilostazol, ticlodipine, warfarin, lisinopril, atorvastatin

Questions 5 and 6 refer to the following case.

A 46-year-old man with a long history of uncontrolled hypertension and tobacco abuse presents to the ED with acute chest pain that started 45 minutes ago. He describes the pain as sharp and 10 out of 10 in intensity and so unbearable that he had a friend drive him to the ED. The pain is substernal and radiates to his jaw, left arm, and back between his shoulder blades. He has been diaphoretic and nauseous since the pain first started but has not been short of breath. The patient is afebrile, blood pressure is 230/110 mm Hg in the right arm and 180/110 mm Hg in the left arm, respiratory rate is 18 breaths/min, and pulse oximetry is 98% on room air. On examination, he is diaphoretic and writhing in discomfort. There is no significant jugular venous distention. Cardiac auscultation reveals a grade 2/6

high-pitched early diastolic decrescendo murmur at the left sternal border that is accentuated when the patient leans forward. The remainder of the physical examination is unremarkable. A 12-lead ECG shows 5-mm ST-segment elevation in the inferior leads with reciprocal ST-segment depression in leads V_2 and V_3. A portable chest radiograph reveals a widened mediastinum.

5. **What is the most beneficial first step in the treatment of this patient?**
   (A) Administer aspirin, a loading dose of clopidogrel, weight-based IV heparin, and IV metoprolol and activate the cardiac catheterization team for primary coronary angioplasty
   (B) Administer aspirin, heparin, and IV thrombolytics in the ED
   (C) Initiate IV labetalol infusion, titrating to a target heart rate of 60 to 80 bpm and a mean arterial pressure of 60 to 80 mm Hg, and obtain emergent cardiothoracic surgical evaluation
   (D) Initiate IV nitroprusside infusion, titrating to a goal systolic blood pressure of 100 to 120 mm Hg, and obtain emergent cardiothoracic surgical evaluation

6. **What is the next step in the diagnostic work-up of this patient?**
   (A) Cardiac biomarkers and fasting lipid panel within 60 minutes
   (B) Immediate chest computed tomography (CT) with IV contrast
   (C) Immediate coronary angiogram by the cardiologist
   (D) Immediate transthoracic echocardiogram by the cardiologist

ANSWERS AND EXPLANATIONS

1. **(A) Administer an NSAID.** The patient's clinical history is consistent with acute pericarditis, likely viral in nature. The ECG supports this diagnosis, with findings of PR-segment depression as well as concave ST-segment elevation in a large territory that does not follow a coronary artery distribution (Figure 1). An NSAID should be administered to alleviate the patient's chest discomfort.[1] Atrial fibrillation was incidentally found on physical examination at the time of presentation. Atrial fibrillation is not an uncommon finding in patients with pericarditis and may resolve on its own after the inflammatory process subsides.[1,2] The use of anticoagulation in this young woman with no significant risk factors for stroke or thromboembolism would be of little benefit, and it may be harmful given that the patient might have a pericardial effusion associated with pericarditis, which can be worsened by anticoagulation.[2] The patient is not experiencing an acute MI; therefore, IV thrombolytic therapy and aspirin and cardiac catheterization are not indicated.

2. **(D) Discharge home with echocardiography scheduled as an outpatient.** This patient with pericarditis has no high-risk features, such as the presence of ventricular arrhythmias, hemodynamic compromise, cardiac tamponade, fever, an immunocompromised state, trauma, and chronic use of oral anticoagulants. Thus, outpatient follow-up with echocardiography would be the best choice.[1] Because there is no clinical indication of cardiac tamponade or other high-risk features, CCU admission with immediate transthoracic echocardiography is not necessary. The etiology of the chest pain has been established, and no further diagnostic evaluation is necessary for alternative causes of chest pain, such as MI. In addition, active pericarditis is a contraindication to exercise stress testing. Laboratory testing rarely identifies an etiology of pericarditis and is not considered necessary unless the patient has additional signs or symptoms that suggest concomitant systemic illness, such as diseases of rheumatologic origin.[1]

3. **(A) Activate the coronary intervention team for emergent cardiac catheterization within 90 minutes of first medical contact.** This patient presented with an acute ST-segment elevation myocardial infarction (STEMI) of the anterior and septal walls with features of cardiogenic shock. Patients with STEMI and cardiogenic shock benefit from early reperfusion via percutaneous coronary intervention with potential intra-aortic balloon placement.[3] The patient should be treated with dual antiplatelet therapy as well as anticoagulation with either heparin or enoxaparin prior to cardiac catheterization.[3] If findings of a possible mechanical complication of MI are present (eg, ventricular septal rupture, papillary muscle rupture, left ventricular free wall rupture) or if the patient has a high likelihood of needing coronary bypass surgery, then clopidogrel may be withheld due to higher risk of bleeding complications during the perioperative period.[3] This patient has no indication of a mechanical complication of MI, and obtaining a transthoracic echocardiogram may further delay the time to reperfusion. IV fluids are only useful in the setting of right ventricular infarction to restore preload. IV dobutamine is generally not

indicated in the setting of acute MI because it can worsen myocardial ischemia. Evidence suggests that patients with acute STEMI and cardiogenic shock have better outcomes with primary angioplasty than with thrombolytic reperfusion.[3] Starting a glycoprotein IIb/IIIa inhibitor and waiting 24 hours to perform cardiac catheterization in a patient with untreated MI complicated by cardiogenic shock would worsen the patient's chances of survival.

4. **(C) Aspirin, clopidogrel, lisinopril, metoprolol, pravastatin.** After MI, patients should be discharged on dual antiplatelet therapy with aspirin and clopidogrel regardless of the mode of reperfusion.[3] This patient should also be treated with a β-blocker and an angiotensin-converting enzyme inhibitor per current guidelines.[3] Aggressive lipid-lowering therapy with a statin is also important and should be initiated while the patient is in the hospital and continued upon discharge.[3] The other answers do not outline the complete regimen that would be most beneficial to the patient.

5. **(C) Initiate IV labetalol infusion, titrating to a target heart rate of 60 to 80 bpm and a mean arterial pressure of 60 to 80 mm Hg, and obtain emergent cardiothoracic surgical evaluation.** This patient has symptoms of an acute type A aortic dissection extending into the right coronary artery, aortic valve, and aortic arch.[4] A type B dissection involves the descending thoracic aorta and spares the ascending aorta and aortic arch. Clues that should raise suspicion for acute aortic dissection include uncontrolled hypertension, sharp pain radiating to the back, presence of a high-pitched diastolic murmur suggestive of aortic regurgitation, unequal blood pressures between the arms indicating compromise of the left subclavian artery, and a widened mediastinum on chest radiograph. A type A dissection almost always requires urgent surgical intervention necessitating immediate consultation with a cardiothoracic surgeon.[4] In the interim, the patient should be rapidly treated with IV β-blockade to lower blood pressure, heart rate, and shear stress on the dissecting aorta. Labetalol is a mixed α- and β-blocker effective for lowering the blood pressure and reducing the shear stress on the aortic wall.[4] Although the patient has evidence of myocardial injury, the mechanism of MI in aortic dissection is usually a result of mechanical disruption of the coronary ostium rather than an acute thrombotic process, and administration of antiplatelet agents, anticoagulation, and/or thrombolytics could prove lethal. Administering nitroprusside without concomitant β-blockade may increase the cardiac contractility and the shear stress on the aortic wall with the potential to worsen the dissection.

6. **(B) Immediate chest CT with IV contrast.** The patient should be emergently evaluated for aortic dissection using chest CT with IV contrast. Other diagnostic options include bedside transesophageal echocardiogram, magnetic resonance imaging of the chest, and, in rare circumstances, contrast aortography.[4] The decision of which modality to use depends on how stable the patient is, experience of the physician, and availability of the modality in the institution. A transthoracic echocardiogram will not likely provide complete visualization of the aorta to aid in diagnosis. Cardiac biomarkers, fasting lipid profile, and coronary angiogram are helpful but not necessary, especially if they delay timely treatment.[4]

REFERENCES

1. Lange RA, Hillis LD. Clinical practice. Acute pericarditis [published erratum appears in N Engl J Med 2005;352:1163]. N Engl J Med 2004;351:2195–202.
2. Fuster V, Ryden LE, Cannom DS, et al; European Heart Rhythm Association; Heart Rhythm Society. ACC/AHA/ESC 2006 guidelines for the management of patients with atrial fibrillation—executive summary: a report of the American College of Cardiology/American Heart Association Task Force on Practice Guidelines and the European Society of Cardiology Committee for Practice Guidelines (Writing Committee to Revise the 2001 Guidelines for the Management of Patients with Atrial Fibrillation) [published erratum appears in J Am Coll Cardiol 2007;50:562]. J Am Coll Cardiol 2006;48:854–906.
3. Antman EM, Hand M, Armstrong PW, et al; Canadian Cardiovascular Society; American Academy of Family Physicians; American College of Cardiology; American Heart Association. 2007 focused update of the ACC/AHA 2004 guidelines for the management of patients with ST-elevation myocardial infarction: a report of the American College of Cardiology/American Heart Association Task Force on Practice Guidelines [published erratum appears in J Am Coll Cardiol 2008;51:977]. J Am Coll Cardiol 2008;51:210–47.
4. Chen K, Varon J, Wenker OC, et al. Acute thoracic aortic dissection: the basics. J Emerg Med 1997;15:859–67.

SELF-ASSESSMENT QUESTIONS ON THE WEB

Now you can access the entire self-assessment series on the Web. Go to www.turner-white.com, click on the "Hospital Physician" link, and then click on the "Self-Assessment Questions" option.

Copyright 2008 by Turner White Communications Inc., Wayne, PA. All rights reserved.