

# Hydropneumothorax Caused by Inadvertent Placement of a Dobhoff Tube

Gregory Howell, MD

Rebecca L. Shriver, MD, FCCP

## CASE PRESENTATION

### Initial Presentation and History

A 78-year-old woman was evaluated by the pulmonary service for dyspnea and an abnormal chest radiograph. The patient had been admitted to the hospital to undergo partial maxillectomy for squamous cell carcinoma of the left maxilla (completed 2 days previously without complication).

The patient had a past medical history of hypothyroidism, atrial fibrillation, irritable bowel syndrome, hypertension, osteoarthritis, and colon cancer (resected 20 years ago). She had several surgeries in the past, including an appendectomy, a tonsillectomy, 4 Caesarean sections, a hysterectomy related to cervical carcinoma, and a cholecystectomy. Due to peptic ulcer disease, she also underwent partial gastric resection. She denied problems with anesthesia or a family history of such problems.

Her medications included diltiazem, hydrochlorothiazide, risedronate, levothyroxine, vitamin supplements (ie, vitamin C, vitamin B<sub>12</sub>, potassium, vitamin E, multivitamin, glucosamine chondroitin sulfate, coenzyme Q10, calcium citrate, vitamin D, black cohosh, chelated magnesium, fiber capsules), and hydrocodone elixir as needed for pain.

The patient had a more than 20 pack-year tobacco history; however, she quit smoking 22 years ago. She reported drinking a glass of wine daily, and she denied illicit drug use.

### Physical Examination

Physical examination on postoperative day 2 revealed a woman in no acute distress who was alert and oriented to questions. She was afebrile with a pulse of 82 bpm, blood pressure of 156/82 mm Hg, and a respiratory rate of 20 breaths/min. The wound from her partial maxillectomy was clean and intact. A Dobhoff tube was in place in the right nare. Her cardiovascular examination was normal, and the respiratory examination revealed

dullness to percussion at the right base with diminished breath sounds. The remainder of the patient's examination was unremarkable.

Her complete blood count and basic metabolic profile were normal. An arterial blood gas indicated hypoxemia with a pH of 7.43, a partial pressure of carbon dioxide of 44 mm Hg, and a partial pressure of oxygen of 50 mm Hg with the patient breathing room air. Her chest radiograph showed a hydropneumothorax (Figure 1).

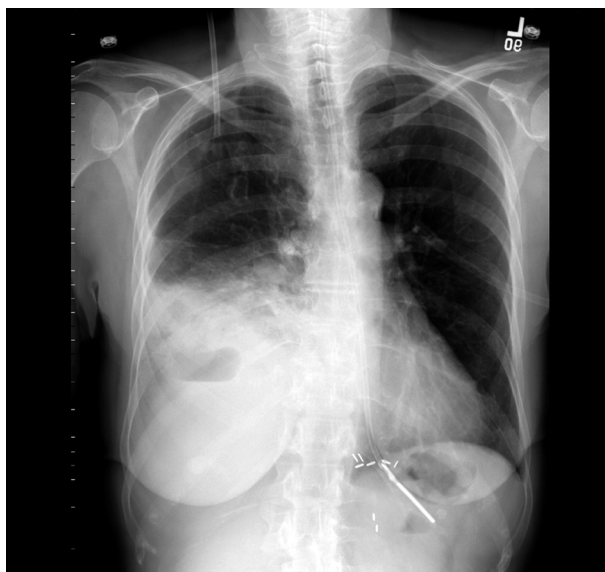### Clinical Course

After reviewing prior radiographs, it was discovered that a Dobhoff tube had been malpositioned in the patient's right lung on the day prior to the consult (Figure 2). Upon further chart review, it was found that enteral nutrition had been started per nutritional protocol through the Dobhoff tube prior to correction of its position. After initiation of enteral feedings, the patient developed mild dyspnea, which persisted and worsened through the night. Her dyspnea was associated with a decrease in oxygen saturation, and she required approximately 3 to 4 L of oxygen per nasal cannula.

This patient's dyspnea and pleural effusion was presumed to be the result of traumatic insertion of the Dobhoff tube into her right pleural space via the right mainstem bronchus, with subsequent intrapleural infusion of enteral nutrition and water boluses. A tube thoracostomy was performed for drainage with good initial results, but due to complications with the tube (ie, kinking) and incomplete resolution of the pleural effusion, video-assisted thoracoscopy was required for definitive management.

---

*Dr. Howell is a pulmonary and critical care medicine fellow, University of Missouri-Kansas City, School of Medicine, Kansas City, MO. Dr. Shriver is in private practice at Midwest Pulmonary Consultants, Kansas City, MO.*



**Figure 1.** Chest radiograph of the case patient on postoperative day 2 demonstrating hydropneumothorax.

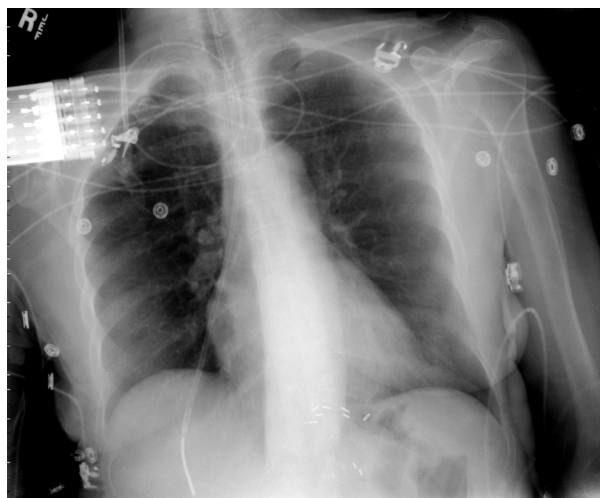
## DISCUSSION

Several complications of nasogastric and orogastric tube placement have been described, including intracranial placement,<sup>1</sup> knots in the feeding tube,<sup>2</sup> sinus infection, bleeding and esophagitis,<sup>3</sup> and traumatic placement resulting in a laceration of the parietal pleura and pneumothorax.<sup>4–8</sup> In a case series, Salzman and colleagues<sup>9</sup> postulated that guide wires were a primary cause of adverse events. Complications still persist even though guide wires are now used less frequently.

### Tube Placement and Technique

Nasogastric or orogastric feeding tube placement should be considered in any patient who requires mechanical ventilation or has altered mental status, oropharyngeal dysfunction due to a cerebrovascular accident or neuromuscular disorder, or other disorders that prohibit oral intake of nutrition. Enteral feeding is preferred to parenteral feeding because it has nutritional advantages and is associated with fewer complications, particularly infections.

Proper technique for feeding tube placement should routinely be employed to avoid complications. The size of the tube should be appropriate for the insertion site, guide wires should not be used, and the tube should not be forced through resistance. The nasogastric tube should be advanced with the head in a neutral or slightly flexed position. Large-bore (12 Fr) nasogastric or orogastric tubes should be used in patients requiring short-term medications or feedings (< 1 week).<sup>10</sup> Narrow-bore



**Figure 2.** Chest radiograph of the case patient 1 day prior to pulmonary consult demonstrating misplacement of a Dobhoff tube.

tubes (8 Fr), such as Dobhoff tubes, are more comfortable for patients and can be left in place for up to 6 weeks.<sup>10</sup> Narrow-bore feeding tubes have a lower incidence of ulceration of the nose, pharynx, and stomach than large bore tubes. However, 2 studies of patients with narrow-bore feeding tubes showed a similar incidence of tracheopulmonary misplacement (2%),<sup>11,12</sup> which is greater than the 1.3% rate of pneumothorax observed with central venous catheter placement.<sup>13</sup>

Patients with altered mental status or who have endotracheal or tracheostomy tubes are at higher risk for tracheopulmonary misplacement.<sup>11</sup> Other means of tube placement (eg, fluoroscopy, laryngoscopy, endoscopy-guided insertion) may be considered in these patients<sup>11</sup> but are controversial due to cost. Marderstein and colleagues<sup>12</sup> showed that placing an enteral tube to 35 cm and obtaining a radiograph prior to further advancement reduced the incidence of pneumothorax in higher-risk intensive care unit patients, but this also increases cost.

### Evaluation of Tube Placement

Evaluation of tube placement includes auscultating the epigastrium for air insufflated through the tube, checking for respiratory symptoms (eg, dyspnea), testing the patient's ability to speak, listening for sounds of air exchange, or observing exhalation bubbles when the tube's free end is held under water after the tube has been inserted past the carina tracheae. Burns and colleagues<sup>14</sup> reported that using end-tidal CO<sub>2</sub> measurements was cost-effective for assuring proper tube placement, but their study was small. Unfortunately,

this evaluation method is not reliable for detecting malposition of the tube.<sup>10</sup>

Metheny and Titler<sup>10</sup> provided algorithms for assessing tube placement using a combination of clinical examination, pH testing, and radiographic confirmation. Several studies have shown that only radiographic studies can reliably confirm placement of the feeding tube. Despite cited evidence, this practice continues to be controversial because of cost and availability.<sup>15</sup> There are no published trials to date that compare clinical versus radiographic evaluation of proper tube placement, but retrospective analysis of available data seems to favor radiographic confirmation. Although cost and availability vary between institutions, portable chest radiographs can prevent significant morbidity and mortality by confirming tube placement prior to initiation of feedings.

If a feeding tube is found to be misplaced, it should be removed immediately, an investigation of possible adverse outcomes should be conducted, and treatment should be initiated immediately, if necessary. The patient and his/her family should be made aware of any adverse events immediately upon their identification. Of note, patients who have had a feeding tube misplaced are at higher risk for having a subsequent feeding tube misplacement. In these patients, techniques other than blind insertion (eg, fluoroscopic or fiberoptic guidance) should be considered when placing a feeding tube. **HP**

#### REFERENCES

1. Metheny NA. Inadvertent intracranial nasogastric tube placement. *Am J Nurs* 2000;102:25–7.
2. Wien FE, Cooperman J. Images in clinical medicine. Complication of Cantor-tube insertion. *N Engl J Med* 2001;344:974.
3. Marinella MA. An unusual cause of dysphagia [letter]. *N Engl J Med* 1997;336:1612–3.
4. Thomas B, Cummin D, Falcone RE. Accidental pneumothorax from a nasogastric tube [letter]. *N Engl J Med* 1996;335:1325.
5. Konarzewski WH, Richards GD, Thomson SJ. Pneumothorax following insertion of a nasogastric tube [letter]. *Anaesthesia* 1986;41:678.
6. Duke GJ, Harding J. Pneumothorax from a nasogastric tube [letter]. *Anaesth Intensive Care* 1990;18:265.
7. Gough D, Rust D. Nasogastric intubation: morbidity in an asymptomatic patient. *Am J Emerg Med* 1986;4:511–3.
8. Culpepper JA, Veremakis C, Guntupalli KK, Sladen A. Malpositioned nasogastric tube causing pneumothorax and bronchopleural fistula [letter]. *Chest* 1982;81:389.
9. Salzman GA. Pulmonary complications from small-diameter, flexible nasoenteric feeding tubes. *Mo Med* 1986;83:81–4.
10. Metheny NA, Titler MG. Assessing placement of feeding tubes. *Am J Nurs* 2001;101:36–46.
11. Rassias AJ, Ball PA, Corwin HL. A prospective study of tracheopulmonary complications associated with the placement of narrow-bore enteral feeding tubes. *Crit Care* 1998;2:25–8.
12. Marderstein EL, Simmons RL, Ochoa JB. Patient safety: effect of institutional protocols on adverse effects related to feeding tube placement in the critically ill. *J Am Coll Surg* 2004;199:39–50.
13. Hagley MT, Martin B, Gast P, Traeger SM. Infectious and mechanical complications of central venous catheters placed by percutaneous venipuncture and over guidewires. *Crit Care Med* 1992;20:1426–30.
14. Burns SM, Carpenter R, Truitt JD. Report on the development of a procedure to prevent placement of feeding tubes into the lungs using end-tidal CO<sub>2</sub> measurements. *Crit Care Med* 2001;29:936–9.
15. Hall FM. Mandatory radiographs after tube placement [letter]. *N Engl J Med* 1997;336:1108–9.

Copyright 2005 by Turner White Communications Inc., Wayne, PA. All rights reserved.