Thoracic Spinal Cord Compression Caused by Metastatic Pheochromocytoma

Jennifer I. Chang, MD
Sabrina S. Hong, MD
Christian J. Gastelum, MD, MBA
Nicholas N. Nissen, MD
Ray Chu, MD
Run Yu, MD, PhD

Pheochromocytoma is a tumor derived from adrenal medulla chromaffin cells that produces and secretes catecholamines. It can also present as a paraganglioma of the extra-adrenal sympathetic and/or parasympathetic nervous system. The incidence of pheochromocytoma is approximately 1 to 6 cases per million persons.[1] At the initial diagnosis of pheochromocytoma, the primary tumor may be either benign or malignant, but it is difficult to differentiate between benign and malignant tumors prior to metastasis.[2] After surgical resection of a presumed benign pheochromocytoma, only 13% of cases recur, again either as a benign or malignant tumor.[3] Approximately 10% of all pheochromocytomas are considered malignant.[2,4] Presence of distant metastases clinically defines malignancy. The most common sites of metastases are the bones, lungs, liver, and retroperitoneal or mediastinal lymph nodes.[2,4–13] This article reports the case of a woman who had pheochromocytoma that metastasized to the thoracic spine and presented with cord compression, necessitating urgent neurosurgical intervention. A review of the surgical management of patients with metastatic pheochromocytoma is also provided.

CASE PRESENTATION

Initial Presentation

A 57-year-old woman presented to the emergency department of a community hospital with complaints of nonradiating lower back pain and gradual weakness of the lower extremities bilaterally. The patient's past medical history was significant for metastatic pheochromocytoma and diabetes mellitus (diagnosed 10 years ago). Review of systems was negative for headaches, palpitations, sweats, seizures, fevers, chills, nausea, and vomiting.

History

Seven years prior to the current presentation, the patient was diagnosed with pheochromocytoma in the right adrenal gland following presentation with chest pain, dyspnea, diaphoresis, and mood changes. At that time, the patient refused surgical intervention. Two years later, right adrenalectomy was performed. The patient had no symptoms for 2 years, at which point she presented with symptoms of blurry vision and vomiting. Laboratory studies revealed hyperglycemia and high levels of urinary catecholamines, and a computed tomography (CT) scan revealed a 4-cm left adrenal mass. The patient was started on oral phenoxybenzamine (10 mg every 12 hr), with which she was only intermittently compliant. She was lost to follow-up before she could be scheduled for surgery.

Six months later, the patient noted recurrence of headaches, visual changes, and chest pain. She was diagnosed with non–ST-elevated myocardial infarction, which was thought to be caused by a catecholamine surge since coronary catheterization revealed no evidence of coronary artery disease. Magnetic resonance imaging (MRI) of the abdomen revealed a large retroperitoneal lymph node with involvement of the left adrenal gland. Octreotide scan and positron emission tomography (PET) showed activity in the posterior retroperitoneum, lower cervical and thoracic spine at T8 and T12-L1, and right sacral area. Left adrenalectomy, left perinephrectomy,

Dr. Chang and Dr. Hong are internal medicine residents, Kaiser Los Angeles Medical Center, Los Angeles, CA. Dr. Gastelum is an endocrinology fellow, Cedars-Sinai Medical Center, Los Angeles, CA. Dr. Nissen is a staff physician, Department of Surgery, Cedars-Sinai Medical Center, and Department of Surgery, David Geffen School of Medicine at UCLA, Los Angeles, CA. Dr. Chu is a staff physician, Department of Neurosurgery, and Dr. Yu is a staff physician, Division of Endocrinology, Cedars-Sinai Medical Center.

Figure 1. Magnetic resonance image demonstrating cord compression at T12 (*arrow*).

right renal hilar mass resection, and perinephric lymphadenectomy were performed. Pathology was consistent with metastatic pheochromocytoma. No evidence of lymphovascular permeation into the adjacent sympathetic ganglion was seen. The 7 lymph nodes resected were negative for metastatic spread.

Repeat PET performed 2 months later showed multiple focal areas of increased activity in the skeletal system consistent with worsening disease, including lesions at C1 through C7, T7, T11, T12, and L2. Involvement of the rib cages bilaterally, right ischium, and right mid proximal femur was also seen. Three months following PET scan, the patient's course was complicated by a pathologic fracture of the right femur bone, which necessitated rod placement. Six months following this repair, the patient underwent external beam radiotherapy to the spine and neck for pain control and local tumor bulk reduction. Although this therapy controlled local symptoms well, the patient had gross tumor progression. One month after completing radiation therapy, she was treated with seven 21-day cycles of vincristine, dacarbazine, and cytoxan to reduce tumor bulk. The patient had chronic pain controlled with oral opiates (oxycodone 60 mg twice daily and hydrocodone plus acetaminophen as needed) but otherwise functioned well until 10 months later when she developed nonradiating lower back pain and gradual weakness of the lower extremities bilaterally that prompted the current presentation. The patient's blood pressure was well controlled with oral labetalol 100 mg twice daily for 2.5 years.

Physical Examination

After 6 days, the patient was transferred to a tertiary hospital experienced in treating patients with pheochromocytoma. During this time, her blood pressure fluctuated but remained well controlled. Upon transfer, the patient developed hypertension, with blood pressure readings as high as 188/100 mm Hg. The patient was awake, alert, and comfortable. Physical examination revealed decreased muscle strength bilaterally in the lower extremities: right iliopsoas, 3/5 strength; left iliopsoas, 4/5 strength; and both quadriceps, 4/5 strength. Sensation was decreased below the T10 dermatome, especially on the right side. She had tenderness over the cervicothoracic junction, lower thoracic spine, and sacral area. When queried, the patient indicated that the pain was 8.5 on a pain scale of 1 to 10. No clonus was present. Reflexes were 2+ at the knee and biceps on the left and 1+ at the knee and biceps on the right.

Hospital Course

CT revealed metastasis to C7, T7, T9 through T12, and L2 vertebrae as well as a T12 right pedicle fracture. MRI demonstrated spinal stenosis at T7 and cord compression at T12 (**Figure 1**). Intravenous (IV) dexamethasone was administered immediately to temporarily alleviate cord compression until the patient's blood pressure could be controlled for surgery. Because her blood pressure was well controlled before hospitalization, the high blood pressure observed during the physical examination was thought to be caused by pain. She was continued on her prescribed blood pressure medication (oral labetalol 100 mg twice daily). Additionally, she received a single dose of oral clonidine (0.1 mg) due to a systolic blood pressure reading that exceeded 185 mm Hg on hospital day 1. Pain decreased to a score of 5 with administration of hydromorphone through a patient-controlled analgesia (PCA) device, but her blood pressure remained elevated at 170/110 mm Hg on hospital day 1. Oral labetalol was increased (100 mg every 8 hr) with minimal improvement of blood pressure. The endocrine service was consulted for preoperative management on hospital day 3. The patient was started on oral phenoxybenzamine (20 mg twice daily) for α-blockade. The patient had been taking furosemide for chronic lower extremity edema, which was discontinued on

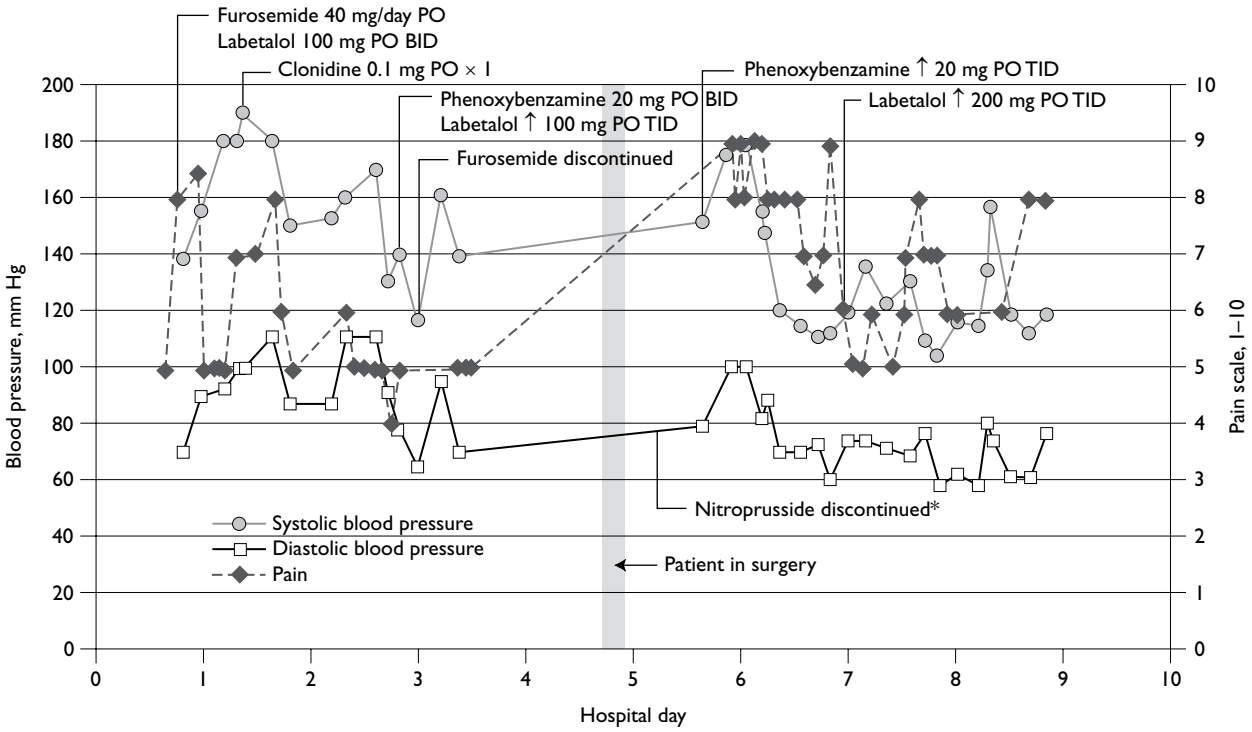

Figure 2. Preoperative and postoperative fluctuation of the case patient's systolic blood pressure, diastolic blood pressure, and pain level over time with antihypertensive medication administration. *See* Figure 3 for intraoperative fluctuations in blood pressure control. ↑ = dose increase; BID = twice daily; PO = by mouth; TID = 3 times daily. *Nitroprusside was started intraoperatively.

hospital day 3 due to concern regarding intravascular volume control. IV fluids were started (5% glucose/0.9% NaCl plus KCl 20 mEq/L at a rate of 75 mL/hr). Preoperatively, blood pressure was controlled to a level of 140/70 mm Hg (**Figure 2**).

On hospital day 4, the patient underwent T12 vertebrectomy and fusion of T11 through L1 with expandable titanium cage and plating (**Figure 3**). During induction of anesthesia, the patient was hypertensive to 212/100 mm Hg, during which time a nitroprusside drip and additional doses of IV esmolol (50 mg) and labetalol (5 mg) were initiated; blood pressure control was then achieved (**Figure 4**). Postoperatively, the patient became hypertensive, which was determined to be due to inadequate pain control from a disconnected PCA device. After PCA was reinstated and pain control was regained, the patient's blood pressure decreased to approximately 160/85 mm Hg. Nitroprusside drip was discontinued, and the patient was switched from IV to oral hypertensive medications (phenoxybenzamine increased to 20 mg every 8 hr and labetalol 100 mg every 8 hr) on hospital day 5. On postoperative day 3 (hospital day 7), the patient's oral labetalol was increased (200 mg every 8 hr) because she was still hypertensive. Subsequently, the patient had improved blood pressure control for the remainder of her hospital stay (blood pressure ranging from 100–140/60–80 mm Hg). On postoperative day 13 (hospital day 17), she was discharged in stable condition to physical rehabilitation and was being considered for enrollment in a clinical trial to receive ^{131}I-metaiodobenzylguanidine (MIBG).

METASTATIC PHEOCHROMOCYTOMA

This case illustrates the natural history of metastatic pheochromocytoma and emphasizes important principles in surgically managing this disease (preoperative management, debulking, and monitoring intraoperative hemodynamics), especially in patients who need urgent intervention. As was noted earlier, malignant disease may be present at the time of initial diagnosis of pheochromocytoma or may present following removal of the primary tumor. Metastasis may be indolent and has been reported to occur nearly 20 years later, emphasizing the need for long-term follow-up with these patients. However, most metastases occur within 5 years,[2] which was seen in the case patient. Although the bones are among the most common sites for pheochromocytoma metastases, spinal metastasis

Figure 3. Postoperative magnetic resonance image demonstrating T11 to L1 fusion with expandable titanium cage and T11 to L1 plating with anterolateral plate (*arrow*).

is generally rare.[2,4–13] Previous case reports have described both cervical and thoracic spine metastases,[5–13] the latter of which was seen in the case patient. The overall 5-year survival in malignant pheochromocytoma ranges from 40% to 74%.[2,4]

Management

Treatment of metastatic pheochromocytoma is usually considered palliative, and no evidence-based guidelines are available to guide treatment due to the lack of randomized controlled trials.[4,14] The following section discusses the options available for managing metastatic pheochromocytoma.

Surgical debulking. Although resection can be curative in cases of benign pheochromocytoma, surgical intervention in metastatic disease seldom is. Surgical debulking is performed primarily to ameliorate symptoms (eg, hypertension) by reducing tumor bulk and associated catecholamine secretion and to manage complications,[1–4] such as the spinal compression resulting from thoracic metastasis seen in the case patient. As operations in patients with pheochromocytoma are high risk due to perioperative cardiovascular complications, elective operations should be deferred until after pheochromocytoma resection. If emergent or urgent operations are necessary, clinicians should make a balanced decision. Temporizing measures should be used, if available, to allow at least some blood pressure control and volume repletion.[1] In the case patient, dexamethasone was administered preoperatively to alleviate spinal cord compression until the patient's blood pressure was controlled. Corticosteroids are known to reduce edema in experimental models, and the administration of corticosteroids can alleviate pain rapidly and enhance recovery.[15]

Preoperative management for all patients diagnosed with pheochromocytoma involves optimizing blood pressure control and volume repletion to prevent perioperative cardiovascular complications. α-Blockers (eg, phenoxybenzamine) are most frequently used to manage blood pressure and should precede β-blockers to avoid unopposed α action that causes paradoxical blood pressure increase.[1] Alternatively, calcium channel blockers can be used instead of α-blockers.[16] β-Blockers are used if patients develop tachycardia after blood pressure is controlled. Patients are encouraged to eat salty foods and may require IV hydration preoperatively to correct the chronic volume depletion caused by excessive catecholamine action. Generally, at least 2 weeks of preoperative preparation is preferred. In patients with metastatic disease, these principles still apply, but these patients typically are taking blood pressure medications and are volume repleted to a certain extent preoperatively.[14,17,18] As such, they do not require aggressive IV hydration.

In preoperatively managing the case patient, the endocrine service encountered 2 issues. The first was determining the reason that the patient became hypertensive at transfer despite receiving the same medications that controlled blood pressure well prior to hospitalization. In this instance, hypertension could have been caused by significant pain, by increased catecholamine secretion associated with metastatic disease, or both. As overtreatment of hypertension is dangerous and pain control is important by itself, the patient's pain control was first optimized, resulting in partial improvement of blood pressure. The second issue involved the best method for preoperatively normalizing blood pressure in this patient. Although IV medications have the advantage of rapid correction of blood pressure, their antihypertensive effects are short, and this largely stable patient would have to be transferred to the intensive care unit prior to surgery because these agents require frequent dosing adjustments. As the patient's blood pressure was not dangerously high on

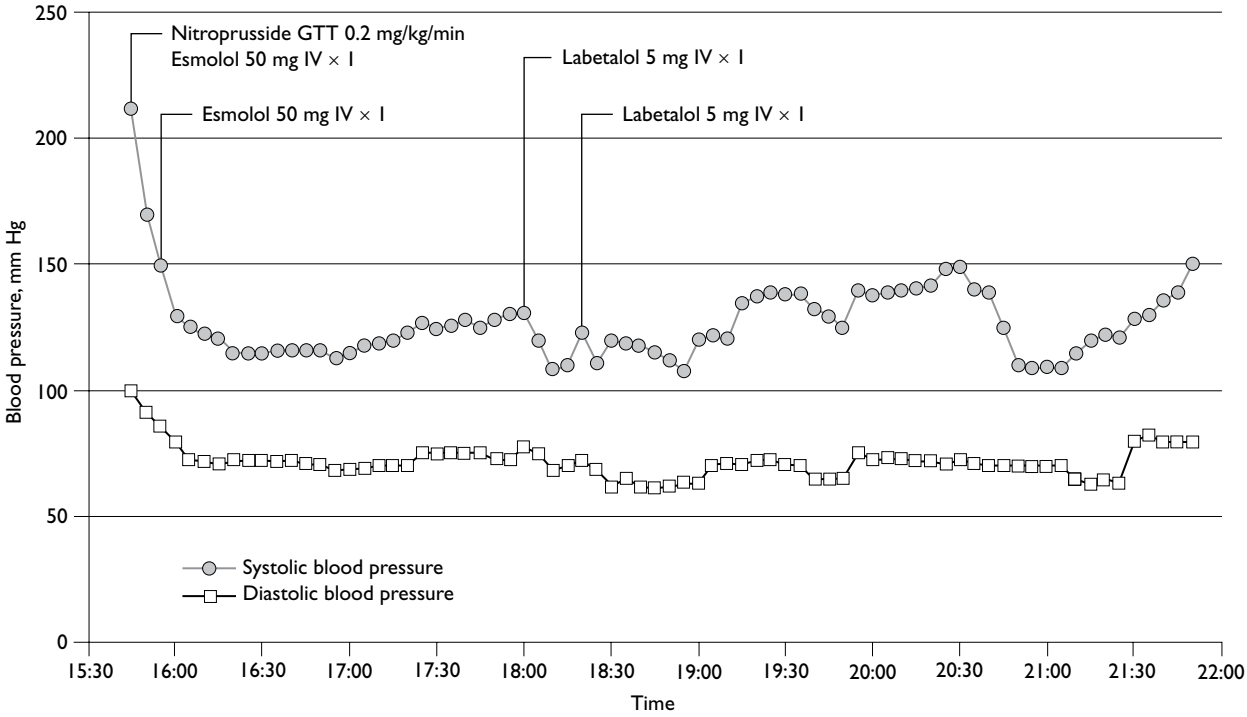

Figure 4. Intraoperative fluctuations of the case patient's systolic and diastolic blood pressures with administration of antihypertensive medication. GTT = drops; IV = intravenous.

the day prior to surgery, the endocrine service opted to use a high starting dose of phenoxybenzamine (20 mg twice daily) to prepare her for the operation, which controlled her blood pressure well. The case patient also had been previously treated with a diuretic agent (furosemide), which made her volume status an issue of concern during the time of anesthesia induction. Furosemide was discontinued on hospital day 3, and the patient received IV fluids. However, aggressive IV hydration was not attempted because the planned surgery would only slightly decrease the tumor burden.

Intraoperative blood pressure fluctuations are common in patients with pheochromocytoma, despite optimal preoperative preparation, due to the large quantities of catecholamine released during anesthesia and tumor manipulation, which often overwhelm the effects of preoperative medications.[17,18] Anesthesiologists use IV medications to control intraoperative blood pressure.[1] Postoperatively, blood pressure needs to be monitored, as hypotension can occur if volume repletion is insufficient.[1] However, postoperative hypotension is rare after surgical debulking in patients with metastatic pheochromocytoma because the remaining tumor mass usually produces enough catecholamines to maintain blood pressure.[1] As expected, hypotension was not encountered either intraoperatively or postoperatively in the case patient because the operation did not significantly decrease the tumor burden.

Other treatment modalities. Chemotherapy is commonly used for inoperable tumor and/or residual disease following surgical debulking. Currently, a combination of cyclophosphamide, vincristine, and dacarbazine (CVD) is most commonly used.[14] External beam radiotherapy also can be used for palliation of painful bone metastases and inoperable tumors.[4] Radiopharmaceutical treatment with ^{131}I-MIBG has been used to treat malignant pheochromocytoma in clinical trials. In most patients, ^{131}I-MIBG is not curative and is used as adjuvant therapy.[4,14] As noted earlier, the patient was considered for enrollment in a clinical trial to receive ^{131}I-MIBG radiotherapy. Prior to surgical debulking to alleviate spinal cord compression, the case patient received surgical resection and cytoreduction, surgical management of bone complications, chemotherapy, and external beam radiation. Surgical intervention is indicated for cord compression, but it is not known if the operation has enduring benefit and long-term follow-up is needed. The patient did not receive local external beam radiation after the operation because she had already received several rounds of such therapy

on the spine with questionable responses and she had minimal tumor burden at T12 without local pain after the operation.

SUMMARY

All patients with pheochromocytoma require long-term follow-up after resection of apparently benign tumor(s). If recurrence or metastasis is identified, the tumor burden should be surgically reduced as much as is feasible. All patients with pheochromocytoma undergoing surgery require preoperative blood pressure control and intravascular volume repletion. Postoperative management of patients with residual disease involves antihypertensive medications, ^{131}I-MIBG radiotherapy, and/or chemotherapy. Complications of metastatic pheochromocytoma should be managed on a case-by-case basis. **HP**

Corresponding author: Run Yu, MD, PhD, Cedars-Sinai Medical Center, B-131, 8700 Beverly Blvd., Los Angeles, CA 90048; run.yu@cshs.org.

REFERENCES

1. Manger WM, Eisenhofer G. Pheochromocytoma: diagnosis and management update. Curr Hypertens Rep 2004;6:477–84.
2. Eisenhofer G, Bornstein SR, Brouwers FM, et al. Malignant pheochromocytoma: current status and initiatives for future progress. Endocr Relat Cancer 2004;11:423–36.
3. Plouin PF, Chatellier G, Fofol I, Corvol P. Tumor recurrence and hypertension persistence after successful pheochromocytoma operation. Hypertension 1997;29:1133–9.
4. Chrisoulidou A, Kaltsas G, Ilias I, Grossman AB. The diagnosis and management of malignant phaeochromocytoma and paraganglioma. Endocr Relat Cancer 2007;14:569–85.
5. Thompson NW, Allo MD, Shapiro B, et al. Extra-adrenal and metastatic pheochromocytoma: the role of 131I meta-iodobenzylguanidine (131I MIBG) in localization and management. World J Surg 1984;8:605–11.
6. Thompson NW. Malignant pheochromocytoma. Acta Chir Aust 1993;4:235–9.
7. Loh KC, Fitzgerald PA, Matthay KK, et al. The treatment of malignant pheochromocytoma with iodine-131 metaiodobenzylguanidine (131I-MIBG): a comprehensive review of 116 reported patients. J Endocrinol Invest 1997;20:648–58.
8. Yurt A, Arda MN, Vardar E. Metastatic pheochromocytoma of the thoracic spinal extradural space. Case report and review of the literature. Kobe J Med Sci 2005;51:49–53.
9. Zelinka T, Timmers HJ, Kozupa A, et al. Role of positron emission tomography and bone scintigraphy in the evaluation of bone involvement in metastatic pheochromocytoma and paraganglioma: specific implications for succinate dehydrogenase enzyme subunit B gene mutations. Endocr Relat Cancer 2008;15:311–23.
10. Olson JJ, Loftus CM, Hitchon PW. Metastatic pheochromocytoma of the cervical spine. Spine 1989;14:349–51.
11. Kheir E, Pal D, Mohanlal P, et al. Cervical spine metastasis from adrenal pheochromocytoma. Acta Neurochir (Wien) 2006;148:1219–20.
12. Yamaguchi S, Hida K, Nakamura N, et al. Multiple vertebral metastases from malignant cardiac pheochromocytoma—case report. Neurol Med Chir (Tokyo) 2003;43:352–5.
13. Miyamori I, Yamamoto I, Nakabayashi H, et al. Malignant pheochromocytoma with features suggesting the Brown-Sequard syndrome. A case report. Cancer 1977;40:402–5.
14. Scholz T, Eisenhofer G, Pacak K, et al. Clinical review: Current treatment of malignant pheochromocytoma. J Clin Endocrinol Metab 2007;92:1217–25.
15. Quinn JA, DeAngelis LM. Neurologic emergencies in the cancer patient. Semin Oncol 2000;27:311–21.
16. Combemale F, Carnaille B, Tavernier B, et al. [Exclusive use of calcium channel blockers and cardioselective beta-blockers in the pre- and peri-operative management of pheochromocytomas. 70 cases.] [Article in French.] Ann Chir 1998;52:341–5.
17. Pacak K. Preoperative management of the pheochromocytoma patient. J Clin Endocrinol Metab 2007;92:4069–79.
18. van der Horst-Schrivers AN, Kerstens MN, Wolffenbuttel BH. Preoperative pharmacological management of pheochromocytoma. Neth J Med 2006;64:290–5.

Copyright 2009 by Turner White Communications Inc., Wayne, PA. All rights reserved.