Toxoplasmic Encephalitis

Matthew J. Letizia, DO
Joseph R. Lo Faro, MD
Marcin K. Kociuba, DO
Harold T. Huss, DO

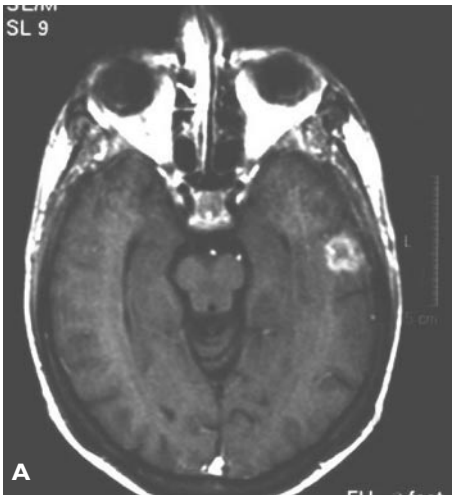

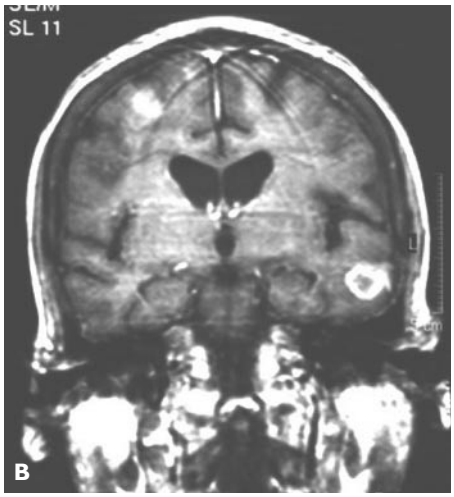

A 43-year-old woman with HIV and hepatitis C virus infection presented to the emergency department following a witnessed tonic-clonic seizure. The patient's family reported that over the previous 9 months she had experienced progressive changes in her mental status and had demonstrated forgetfulness, irritability, frequent falls, and an ataxic gait. Upon arrival, the patient was combative, confused, and moving all extremities. Physical examination was notable only for cachexia, poor skin turgor, and diffuse oral thrush. Computed tomography (CT) and magnetic resonance imaging (MRI) revealed multiple ring-enhancing lesions in the brain (**Image A** and **Image B**). She was admitted to the hospital where she was found to have a CD4+ cell count of 311 cells/µL and a *Toxoplasma* IgG level exceeding 200 IU/mL (normal, < 8 IU/mL).

T. gondii is an obligate intracellular parasite that is found in 25% to 50% of healthy adults in the United States.[1] Acquired via ingestion of cysts from undercooked meat or oocysts excreted in cat feces, *T. gondii* infection is controlled by the actions of the cell-mediated immune system in the normal host.[2] Reactivation of latent infection, as seen in patients with AIDS, is caused by a disabled immune system and can result in life-threatening toxoplasmic encephalitis.[3] Toxoplasmic encephalitis is rarely seen until the CD4+ count falls below 100 cells/µL. However, this patient was among the 10% of infected individuals in whom toxoplasmic encephalitis is diagnosed with a count above 200 cells/µL. Presenting signs and symptoms of toxoplasmic encephalitis vary, with headaches, seizures, disorientation, and hemiparesis being the most common. The diagnosis of toxoplasmic encephalitis is supported by the combination of positive serology for *Toxoplasma* and a characteristic finding of multiple ring-enhancing lesions on CT or MRI. CT or MRI is the recommended imaging study. A combination of pyrimethamine and sulfadiazine is the preferred treatment, which was instituted in this case and resulted in a positive outcome.[2] Approximately 10% of AIDS patients in the United States die of toxoplasmic encephalitis.[4] **HP**

REFERENCES

1. Carruthers VB. Host cell invasion by the opportunistic pathogen *Toxoplasma gondii*. Acta Trop 2002;81:111–22.
2. Montoya JG, Liesenfeld O. Toxoplasmosis. Lancet 2004;363:1965–76.
3. Weiss LM, Kim K. The International Congress on Toxoplasmosis. Int J Parasitol 2004;34:249–52.
4. Hill D, Dubey JP. *Toxoplasma gondii:* transmission, diagnosis and prevention. Clin Microbiol Infect 2002;8:634–40.

Drs. Letizia and Lo Faro are attending emergency medicine physicians, Trinitas Hospital, Elizabeth, NJ; Dr. Kociuba is an attending emergency medicine physician, Raritan Bay Medical Center, Perth Amboy, NJ; and Dr. Huss is a surgical resident, University of Massachusetts Medical Center, Worcester, MA.

Copyright 2008 by Turner White Communications Inc., Wayne, PA. All rights reserved.