Central Pontine Myelinolysis in a Patient Admitted for Alcohol Withdrawal

Richard L. Bakst, MD
Michael E. Kasper, MD
Richard E. Greene, MD

Central pontine myelinolysis (CPM) refers to the nerve damage that occurs due to destruction of myelin sheath that covers nerve cells in the pons. CPM is frequently associated with rapid correction of hyponatremia, and it manifests as confusion, quadriplegia, pseudobulbar palsy, and/or locked-in syndrome (quadriplegia and anarthria with preserved consciousness) that develop over several days. CPM is typically fatal.[1] Milder, nonfatal cases of CPM also have been reported, most notably in normonatremic patients who abuse alcohol.[2–4] Diagnosing CPM in a normonatremic alcoholic patient can be challenging, given that neurologic symptoms are frequently present in these patients and that the presentation of CPM varies greatly. This article discusses the case of a normonatremic, alcoholic man who presented with a combination of dementia, cerebellar findings, and resting tremor. This article also reviews the pathophysiology, differential diagnosis, and management of CPM.

CASE PRESENTATION

A 46-year-old man with a history of alcohol abuse was transferred for management of alcohol withdrawal with confusion and tremors of 1 day's duration. Over the last 10 years, the patient had been hospitalized numerous times for alcohol withdrawal and related seizures. His last drink was 3 to 4 days prior to admission, and there was no recent seizure activity in the past month.

After beginning alcohol use at age 19 years, his alcohol consumption had gradually increased over the following 10 years. At age 30 years, his alcohol abuse became unmanageable, leading to the loss of his job, which he was unable to resume. The patient consumed only beer, approximately 140 oz/day. He has never used illegal drugs, and his only other substance abuse includes a 20 pack-year history of cigarette smoking. The patient also has a long history of poor nutrition, with his food intake consisting of at most 1 sandwich daily for the past 15 years. He reported the subjective sense of significant weight loss over the past 6 months, which was later confirmed by his family. On the day of admission, the patient was alert, oriented only to self, tremulous, and complaining of mild right upper quadrant pain.

Physical Examination

The patient was resting comfortably and appeared slender with evidence of cachexia, including bitemporal wasting. His vital signs were as follows: blood pressure, 110/87 mm Hg; heart rate, 84 bpm; respirations, 16 breaths/min; and temperature, 97.0°F. Erythematous scaly plaques were present on the malar region of the face with involvement of the eyebrows as well. A grade 2/6 systolic ejection murmur was appreciated at the apex with no radiation. Mild right upper quadrant tenderness was elicited with deep palpation but not voluntary guarding or rebound. The liver was not palpable and was percussed to 11 cm.

On neurologic examination, the patient scored 10 out of 30 points on the Folstein Mini-Mental State Examination[5] with deficits in orientation, immediate and short-term memory, and concentration tasks. Cranial nerve examination revealed tongue fasciculations with a deviation of the tongue to the left on protrusion. Facial expressions were blunted. Speech onset was delayed, and speaking volume was low. Motor examination revealed full strength in all extremities; however, the patient was slow to initiate movement. A resting tremor that disappeared with movement was present in the jaw and in the hands when extended. Reflexes were 3+ throughout and symmetrical; plantar reflexes were downward. Sensation to fine touch, pain, and vibration were intact. Romberg's sign was present, and

At the time of submission, Dr. Bakst was a medical student at New York University School of Medicine, New York, NY. He is now an intern at the Department of Internal Medicine, Mount Sinai Medical Center, New York, NY. Dr. Kasper is a resident at New York University Medical Center, New York, NY. At the time of submission, Dr. Greene was a resident at New York University School of Medicine, New York, NY; he is currently a clinical instructor there.

Figure 1. Magnetic resonance imaging scan (T1-weighted sagittal view) showing a hypointense area in the central pons (*arrow*) that is indicative of central pontine myelinolysis.

joint proprioception was intact. On finger-to-nose test, the patient was slow to initiate movement with mild dysmetria and "past pointing." Rapid alternating movements were intact. Gait was wide-based and unsteady with a tendency to fall to the left; the patient was unable to tandem walk. The patient received a Clinical Institute Withdrawal Assessment for Alcohol Revised (CIWA–Ar) score of 18 out of 67 points, corresponding to severe withdrawal symptoms and an increased risk of delirium tremens and seizure.[6]

Laboratory Results

Laboratory studies including complete blood count and serum chemistries were ordered. Blood chemistry and hematology results were as follows: sodium, 139 mEq/L (normal, 136–142 mEq/L); phosphorous, 1.6 mg/dL (normal, 2.3–4.7 mg/dL); hemoglobin, 10.5 g/dL (normal, 14.0–17.5 g/dL); aspartate transaminase (AST), 95 U/L (normal, 10–30 U/L); alanine transaminase (ALT), 50 U/L (normal, 10–40 U/L); direct bilirubin, 0.3 mg/dL (normal, 0.1–0.2 mg/dL); total protein, 6.1 g/dL (normal, 6.0–8.0 g/dL); and albumin, 3.7 g/dL (normal, 3.5–5.0 g/dL). A blood alcohol level was not available on transfer.

Hospital Course

Despite the patient's stable vital signs, he was thought to be in alcohol withdrawal and was started on chlordiazepoxide, thiamine, and folate. Additional laboratory studies were ordered, which included thyroid function tests as well as ammonia, vitamin B_{12}, and folate levels; results were available by hospital day 2, and all were normal. The patient also underwent syphilis (using rapid plasma reagin) and HIV testing. Both tests were available by hospital day 3 and were negative. On hospital day 3, an ultrasound of the abdomen was performed, which revealed a normal sized liver with possible evidence of a fatty liver or hepatitis. AST and ALT began to trend below the upper limit of normal, and the patient no longer complained of right upper quadrant tenderness. On hospital day 5, a noncontrast computed tomography (CT) scan of the brain revealed a few patchy areas of nonspecific low attenuation in the periventricular matter and no acute intracranial pathology.

Over the next 7 hospital days, the patient's mental status remained unchanged. The resting tremor of the patient's hands and jaw as well as his tongue fasciculations improved but did not disappear; otherwise, the neurologic examination remained unchanged. The patient was continued on chlordiazepoxide for possible persistent alcohol withdrawal; however, a cause for the patient's dementia and neurologic deficits was pursued. On hospital day 12, a contrast CT scan of the brain was performed and read as normal. An interventional radiology–guided lumbar puncture was also performed, and cerebrospinal fluid cell count, glucose, protein, and Gram stain were all within normal limits. On hospital day 13, noncontrast magnetic resonance imaging (MRI) of the brain was performed, revealing mild microvascular disease, mild cerebral and cerebellar volume loss, and a central pontine lesion most consistent with CPM (**Figure 1**). No specific therapy was initiated.

On hospital day 15, the patient's mental status had improved slightly (alert and oriented, ×2), and his physical examination remained unchanged. Chlordiazepoxide was tapered and discontinued. The patient was discharged to a nursing home on day 16. Notably, the patient was normonatremic through his hospital course (**Figure 2**).

DISCUSSION

Given the constellation of symptoms and laboratory findings in this patient, several potential diagnoses were investigated. The presence of recent weight loss, seborrheic dermatitis, and general cachectic appearance suggested infection with syphilis or HIV or AIDS with neurologic involvement. However, the negative HIV and syphilis tests and the persistence of symptoms

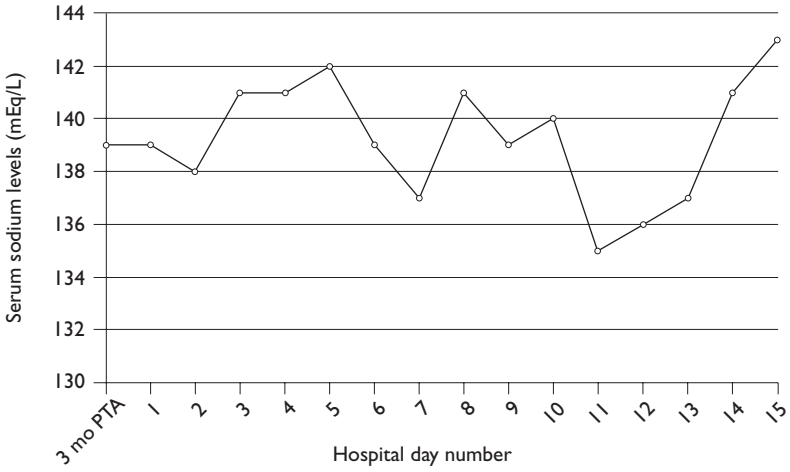

Figure 2. The case patient's serum sodium levels 3 months prior to admission (PTA) and during his hospital course.

thought to be caused by alcohol withdrawal in this patient prompted a search for other causes. A diagnosis of beer potomania was also entertained. Beer potomania is characterized by a history of binge beer drinking, poor dietary intake, severe hyponatremia, polyuria, and various mental status changes or seizures.[7] Although the possibility that the patient was hyponatremic in the past secondary to beer potomania cannot be excluded, there was no evidence of acute hyponatremia. Records obtained from prior hospitalizations also did not reveal evidence of hyponatremia. Additionally, the patient denied polyuria; however, urine osmolarity was not obtained. In retrospect, a thiamine level should have been obtained because this laboratory test is an important component in the evaluation of any nutritionally depleted patient, particularly alcoholics. After many unrevealing laboratory tests and a CAT scan, an MRI of the brain was obtained, which revealed the pontine lesion consistent with CPM (Figure 1).

CENTRAL PONTINE MYELINOLYSIS

Pathogenesis and Pathophysiology

CPM was initially described by Adams and colleagues[8] in 1959 as a disease affecting alcoholic and/or malnourished persons. In 1976, Tomlinson and colleagues[9] suggested that the rapid correction of serum sodium in hyponatremic patients was the causative factor, which was supported by studies using rat models.[10] Since then, several cases of CPM with normonatremia, particularly in alcoholic persons, have been reported, suggesting alcohol's potential role in the pathogenesis of the disorder.[11–13] In addition to alcoholism, other associated etiologies of CPM include liver transplantation,[14] burns,[15] AIDS,[16] and hyperemesis gravidarum.[17]

The exact pathogenesis of CPM continues to elude investigators, although various mechanisms have been proposed. Rapid correction of hyponatremia remains the best documented etiologic factor, and the resulting osmotic demyelination has been well characterized.[18] To combat an osmotic shift of water from the intravascular space, cells activate protective osmoregulatory mechanisms that prevent swelling and resulting cerebral edema. Initially, cells begin to lose electrolytes (notably sodium and chloride) rapidly, rendering themselves isotonic to the intravascular and extracellular compartments and thereby stabilizing cell volume. If the serum abnormality persists, chronic hyponatremia ensues, and the brain chooses to preserve volume over osmolarity, resulting in the loss of organic osmolytes into the extracellular space.

When the outward movement of these cerebral ions is complete, the brain is especially vulnerable to osmotic injury. Oligodendroglia are particularly susceptible to dehydration and volume changes due to their physically tight alignment in the basis pontis. During rapid correction of hyponatremia, intracellular electrolyte corrections are swift, but the brain is unable to correct the loss of organic osmolytes quickly enough, resulting in cellular dehydration, damage to the myelin sheath, and oligodendrocyte degeneration.[19] Based on this premise, investigators have reported a protective effect of administering the organic osmolyte myoinositol in preventing demyelination in rats after correction of chronic hyponatremia.[20]

The process of maintaining an iso-osmolar environment with respect to the serum is energy consuming. If the patient is malnourished, as is typically the case in alcoholic persons, the cells may lack sufficient energy reserve to maintain the Na^+/K^+ ATPase pump activity and to synthesize organic osmoles. Additionally,

alcohol-associated thiamine deficiency may exacerbate the problem because it decreases brain glucose uptake. This energy supply–demand imbalance results in a pro-apoptotic drive.[21] Specifically, neurons may release glutamate in response to osmotic stress, increasing intracellular calcium and thereby promoting apoptotic cell death. Therefore, CPM likely results from a multifactorial process, and these different mechanisms may also account for variable clinical courses observed among patients with CPM.

Clinical Presentation

The classic clinical picture of CPM is pseudobulbar palsy, confusion, and locked-in syndrome developing over a period of several days.[1] As more case reports of CPM were published, it became clear that CPM has a variable presentation. The variable presentation seen in patients with CPM has been explained by the complexity of the area of demyelination as well as the fact that other areas of the brain are often involved, which is termed extrapontine myelinolysis (EPM). Other regions of the brain typically affected include (in descending order of frequency) the cerebellum, lateral geniculate body, external capsule, hippocampus, putamen, and cerebral cortex/subcortex.[22] The case patient had no imaging-based evidence of EPM; evoked brainstem potentials were not measured.

One report described asymptomatic patients with CPM lesions detected by magnetic resonance relaxometry.[23] In fact, it is now recognized that many CPM cases are clinically asymptomatic.[24] Autopsy series have reported asymptomatic lesions at an occurrence rate of approximately 0.5%.[25] Other reports have described CPM cases associated with movement disorders, including parkinsonism.[26–28] The case patient had features of parkinsonism. As the duration of this patient's CPM is unknown, it is possible that he had longstanding asymptomatic CPM and that his parkinsonism-like features were indicative of a secondary neurologic process; however, brain MRI did not reveal findings that would point to a secondary etiology. Rarely, orolingual dyskinesia and dystonia have been described as late complications of CPM.[28–30] The orolingual abnormalities seen in the present case, however, were not consistent with central nervous system dysfunction characteristic of these reports,[28–30] as the presence of tongue fasciculation and deviation suggests dysfunction at the level of the hypoglossal motor nucleus in the medulla or more peripherally. The etiologies of hypoglossal nerve damage are beyond the scope of this case report. However, further work-up of these neurologic symptoms is warranted.

Neurobehavioral features of CPM include impaired attention and concentration, difficulty in mental tracking, reduced immediate memory span, and impaired delayed recall,[31] all of which were present in the case patient. The limited available information suggests that the neurobehavioral aspects of CPM are related to white matter disease in the pons, and that the cognitive profile in these cases is similar to that of white matter dementia.[24]

Clinical Course

The clinical course of CPM associated with rapid correction of hyponatremia is typically devastating, with the development of irreversible neurologic deficits 2 to 6 days after correction. The prognosis for hyponatremic CPM is poor, with mortality rates as high as 50% in the first 2 weeks after presentation.[32] However, several case reports documenting asymptomatic pontine myelinolysis in alcoholics noted that these patients had a more benign course.[3,4] Additionally, a case series of CPM in 9 alcoholic patients without acute correction of hyponatremia reported that their clinical course was more benign as compared with patients who developed CPM from rapid correction of hyponatremia.[2] The patient's course typically featured reversible conscious disturbances, truncal ataxia, and gait instability. The explanation for this association in chronic alcoholics remains unclear. It has been reported that symptoms and signs of alcohol-associated CPM can disappear completely; however, the pontine lesion persists on MRI, although it decreases in size.[33,34]

Radiologic Features

The classic appearance of CPM on MRI includes a symmetric, trident-shaped signal intensity abnormality in the central pons. CT is less sensitive than MRI in the detection of CPM because of brainstem bone artifact known as Hounsfield's lines. Notably, the appearance of the lesion on MRI lags behind the clinical symptoms, typically by 2 weeks, limiting its utility in achieving an early diagnosis of CPM.[35] However, MRI with diffusion-weighted imaging (DWI) is more sensitive to water molecule motion and may prove to be useful in the early diagnosis of CPM.[36] In terms of prognosis and severity, the size of the pontine lesion does not correlate with the severity of the neurologic illness or the final outcome.[37] The case patient, for example, had a large sized pontine lesion on MRI but lacked the classic severe features of CPM. As noted earlier, the pontine lesion persists on MRI, although it decreases in size.[33,34]

Differential Diagnosis

The presence of the previously mentioned neurologic and neurobehavioral symptoms in a hyponatremic or

alcoholic patient suggests the diagnosis of CPM, which is confirmed by MRI. As CPM is a rare condition, more common conditions that share similar clinical features should be considered prior to conferring the diagnosis of CPM. However, when the suspicion of acute CPM is high, we recommend MRI with DWI (if available) given the delay in appearance of the lesion using standard imaging modalities. An important teaching point from this case is that persistent alcohol withdrawal greater than 1 week despite treatment needs to be worked up for other causes.

The clinical diagnosis of CPM may be difficult to make in alcoholic patients because neurologic involvement occurs frequently in these patients. The variability in symptoms also makes identifying alcohol-associated CPM more challenging. In addition to various etiologies that were considered as the potential cause of the case patient's symptoms (eg, beer potomania, HIV/AIDS), the differential diagnosis for alcohol-associated CPM includes Wernicke's encephalopathy, alcoholic cerebellar degeneration, and alcohol-associated ventricular enlargement and cognitive dysfunction. Wernicke's encephalopathy is a common, acute neurologic disorder that is caused by thiamine deficiency and is characterized by the clinical triad of encephalopathy, oculomotor dysfunction, and gait ataxia.[38] Although the case patient did not display evidence of oculomotor dysfunction, his history of undernutrition placed him at risk for Wernicke's encephalopathy. In retrospect, a thiamine level should have been obtained.

Mild cerebral volume loss, most likely caused by the patient's alcohol abuse, was detected on MRI. Although such volume loss could certainly account for some of the patient's cognitive dysfunction, it could not account for the entire clinical presentation. Further neuropsychological testing is required to better characterize the patient's cognitive deficits. Similarly, MRI detected mild cerebellar volume loss, which may account for some of the patient's neurologic findings. Notably, an alcoholic case of CPM with mainly cerebellar signs has been described.[39] Similarly, alcohol-associated ventricular enlargement and cognitive dysfunction, which may be seen in chronic alcohol abuse, may be responsible for some of the patient's symptoms but do not account for all symptoms such as the gait disturbances and cerebellar signs.

Treatment

In patients with known hyponatremia or patients who are at risk for CPM, the best treatment is prevention. Upon identifying a hyponatremic patient, the severity must be assessed. In symptomatic hyponatremia, the rate of correction should be between 1 and 2 mEq/L/hr; total daily correction should not exceed 8 mEq/L.[40] A basic metabolic panel should be obtained every 3 to 4 hours to monitor sodium status. In addition to hypertonic saline, intravenous urea, which induces an osmotic diuresis, has been used to treat hyponatremia. Mild asymptomatic hyponatremia (sodium > 125 mEq/L) can be safely managed with an appropriate oral sodium diet and fluid restriction.

After the insult of CPM, management should be supportive and directed towards minimizing morbidity and mortality. Based on the premise that myelinotoxic compounds and a speculative inflammatory process are contributing to the pathogenesis of CPM, patients have successfully been treated with plasmapheresis, intravenous immunoglobulins, and steroid administration.[18,41–43] However, these therapies need to be studied further. CPM has also been treated successfully with daily thyroid-releasing hormone for 6 weeks.[44] It remains unclear if these interventions provide benefits in alcohol-associated benign CPM. Importantly, efforts should be made to help individuals stop their alcohol abuse and improve their nutritional status.

The management of CPM-associated neurobehavioral deficits remains challenging. Associated confusion can be managed with low-dose atypical antipsychotic medications for a limited time. Notably, one report described neuropsychologic and gait improvement with methylphenidate.[45] Additionally, vigorous rehabilitation is essential to ensure optimal physical recovery.

CONCLUSION

Although CPM is a rare condition typically associated with rapid correction of hyponatremia, physicians must be aware of the spectrum of its clinical presentations, particularly in alcoholic patients, to ensure proper patient care. Prevention of CPM in patients with known hyponatremia or in those who are at risk for CPM is managed by carefully correcting sodium levels. In patients with alcohol-associated CPM, the challenge is to recognize the underlying etiology of neurologic and neurobehavioral symptoms in a normonatremic patient who chronically abuses alcohol. Notably, persistent alcohol withdrawal despite treatment warrants further work-up. Care for patients with alcohol-associated CPM, who typically have a more benign course and better prognosis, is mainly supportive and focused on symptomatic treatment. **HP**

Acknowledgment: The authors thank Adina Kalet, MD, for her helpful comments on the manuscript as well as Gregory Mints, MD, and Jamie Hoffman, MD for their assistance with the case.

Corresponding author: Richard Bakst, MD, Mount Sinai School of Medicine, 1 Gustave L. Levy Place, Department of Medicine, Box 118, New York, NY 10021; Rich.Bakst@gmail.com.

REFERENCES

1. Wright DG, Laureno R, Victor M. Pontine and extrapontine myelinolysis. Brain 1979;102:361–85.
2. Mochizuki H, Masaki T, Miyakawa T, et al. Benign type of central pontine myelinolysis in alcoholism—clinical, neuroradiological and electrophysiological findings. J Neurol 2003;250:1077–83.
3. Strub MU, Steck AJ, Fuhr P. Asymptomatic central pontine myelinolysis. Neurology 1999;53:914.
4. Razvi SS, Leach JP. Asymptomatic pontine myelinolysis. Eur J Neurol 2006;13:1261–3.
5. Folstein MF, Folstein SE, McHugh PR. "Mini-mental state." A practical method for grading the cognitive state of patients for the clinician. J Psychiatr Res 1975;12:189–98.
6. Sullivan JT, Sykora K, Schneiderman J, et al. Assessment of alcohol withdrawal: the revised clinical institute withdrawal assessment for alcohol scale (CIWA-Ar). Br J Addict 1989;84:1353–7.
7. Fenves AZ, Thomas S, Knochel JP. Beer potomania: two cases and review of the literature. Clin Nephrol 1996;45:61–4.
8. Adams RA, Victor M, Mancall EL. Central pontine myelinolysis: a hitherto undescribed disease occurring in alcoholic and malnourished patients. AMA Arch Neurol Psychiatry 1959;81:154–72.
9. Tomlinson BE, Pierides AM, Bradley WG. Central pontine myelinolysis. Two cases with associated electrolyte disturbance. Q J Med 1976;45:373–86.
10. Kleinschmidt-DeMasters BK, Norenberg MD. Neuropathologic observations in electrolyte-induced myelinolysis in the rat. J Neuropathol Exp Neurol 1982;41:67–80.
11. Laitt RD, Thornton M, Goddard P. Pontine myelinolysis in a normonatraemic alcoholic [letter]. Clin Radiol 1993;47:432–3.
12. Bernsen HJ, Prick MJ. Improvement of central pontine myelinolysis as demonstrated by repeated magnetic resonance imaging in a patient without evidence of hyponatremia. Acta Neurol Belg 1999;99:189–93.
13. Mascalchi M, Cincotta M, Piazzini M. Case report: MRI demonstration of pontine and thalamic myelinolysis in a normonatremic alcoholic. Clin Radiol 1993;47:137–8.
14. Bonham CA, Dominguez EA, Fukui MB, et al. Central nervous system lesions in liver transplant recipients: prospective assessment of indications for biopsy and implications for management. Transplantation 1998;66:1596–604.
15. McKee AC, Winkelman MD, Banker BQ. Central pontine myelinolysis in severely burned patients: relationship to serum hyperosmolality [published erratum appears in Neurology 1988;38:1662]. Neurology 1988;38:1211–7.
16. Miller RF, Harrison MJ, Hall-Craggs MA, Scaravilli F. Central pontine myelinolysis in AIDS. Acta Neuropathol (Berl) 1998;96:537–40.
17. Lampl C, Yazdi K. Central pontine myelinolysis. Eur Neurol 2002;47:3–10.
18. Brown WD. Osmotic demyelination disorders: central pontine and extrapontine myelinolysis. Curr Opin Neurol 2000;13:691–7.
19. Lien YH, Shapiro JI, Chan L. Study of brain electrolytes and organic osmolytes during correction of chronic hyponatremia. Implications for the pathogenesis of central pontine myelinolysis. J Clin Invest 1991;88:303–9.
20. Silver SM, Schroeder BM, Sterns RH, Rojiani AM. Myoinositol administration improves survival and reduces myelinolysis after rapid correction of chronic hyponatremia in rats. J Neuropathol Exp Neurol 2006;65:37–44.
21. Ashrafian H, Davey P. A review of the causes of central pontine myelinosis: yet another apoptotic illness? Eur J Neurol 2001;8:103–9.
22. Martin RJ. Central pontine and extrapontine myelinolysis: the osmotic demyelination syndromes. J Neurol Neurosurg Psychiatry 2004;75 Suppl 3:iii22–8.
23. Sullivan EV, Pfefferbaum A. Magnetic resonance relaxometry reveals central pontine abnormalities in clinically asymptomatic alcoholic men. Alcohol Clin Exp Res 2001;25:1206–12.
24. Kleinschmidt-Demasters BK, Rojiani AM, Filley CM. Central and extrapontine myelinolysis: then...and now. J Neuropathol Exp Neurol 2006;65:1–11.
25. Newell KL, Kleinschmidt-DeMasters BK. Central pontine myelinolysis at autopsy; a twelve year retrospective analysis. J Neurol Sci 1996;142:134–9.
26. Defebvre L, Rogelet P, Destee A, Verier A. Regressive dystonia and cerebellar ataxia: two unusual symptoms in central pontine myelinolysis. J Neurol 1995; 242:450–4.
27. Sullivan AA, Chervin RD, Albin RL. Parkinsonism after correction of hyponatremia with radiological central pontine myelinolysis and changes in the basal ganglia. J Clin Neurosci 2000;7:256–9.
28. Salerno SM, Kurlan R, Joy SE, Shoulson I. Dystonia in central pontine myelinolysis without evidence of extrapontine myelinolysis. J Neurol Neurosurg Psychiatry 1993;56:1221–3.
29. Chu NS. Orolingual dyskinesia in central pontine myelinolysis. Acta Neurol Taiwan 2004;13:156–7.
30. Tison FX, Ferrer X, Julien J. Delayed onset movement disorders as a complication of central pontine myelinolysis. Mov Disord 1991;6:171–3.
31. Vermetten E, Rutten SJ, Boon PJ, et al. Neuropsychiatric and neuropsychological manifestations of central pontine myelinolysis. Gen Hosp Psychiatry 1999;21:296–302.
32. Gocht A, Colmant HJ. Central pontine and extrapontine myelinolysis: a report of 58 cases. Clin Neuropathol 1987;6:262–70.
33. Korogi Y, Takahashi M, Shinzato J, et al. MR findings in two presumed cases of mild central pontine myelinolysis. AJNR Am J Neuroradiol 1993;14:651–4.
34. Yuh WT, Simonson TM, D'Alessandro MP, et al. Temporal changes of MR findings in central pontine myelinolysis. AJNR Am J Neuroradiol 1995;16 (4 Suppl):975–7.
35. Kumar S, Fowler M, Gonzalez-Toledo E, Jaffe SL. Central pontine myelinolysis, an update. Neurol Res 2006;28:360–6.
36. Ruzek KA, Campeau NG, Miller GM. Early diagnosis of central pontine myelinolysis with diffusion-weighted imaging. AJNR Am J Neuroradiol 2004;25:210–3.
37. Laubenberger J, Schneider B, Ansorge O, et al. Central pontine myelinolysis: clinical presentation and radiologic findings. Eur Radiol 1996;6:177–83.
38. Charness ME, Simon RP, Greenberg DA. Ethanol and the nervous system. N Engl J Med 1989;321:442–54.
39. Ozgur-Ilhan I, Demirbas H, Yalcin GA, et al. Alcoholic case of central pontine myelinolysis with mainly cerebellar signs. Eur Addict Res 2005;11:155–6.
40. Adrogue HJ, Madias NE. Hyponatremia. N Engl J Med 2000;342:1581–9.
41. Grimaldi D, Cavalleri F, Vallone S, et al. Plasmapheresis improves the outcome of central pontine myelinolysis [letter]. J Neurol 2005;252:734–5.
42. Deleu D, Salim K, Mesraoua B, et al. "Man-in-the-barrel" syndrome as delayed manifestation of extrapontine and central pontine myelinolysis: beneficial effect of intravenous immunoglobulin. J Neurol Sci 2005;237:103–6.
43. Rojiani AM, Prineas JW, Cho ES. Protective effect of steroids in electrolyte-induced demyelination. J Neuropathol Exp Neurol 1987;46:495–504.
44. Zein EF, Karaa SE, Rollot F, et al. Treatment of central pontine myelinolysis with thyrotropin-releasing hormone. Presse Med 2006;35(4 Pt 1):618–20.
45. Bridgeford D, Arciniegas DB, Batkis M, et al. Methylphenidate treatment of neuropsychiatric symptoms of central and extrapontine myelinolysis. J Stud Alcohol 2000;61:657–60.

Copyright 2008 by Turner White Communications Inc., Wayne, PA. All rights reserved.