Series Editors: Angelo P. Giardino, MD, PhD
Patrick S. Pasquariello, Jr., MD

A 17-Year-Old Boy with Umbilical Discharge

Michael S. Martin, MD
Robert M. Lembo, MD

CASE PRESENTATION

History

A 17-year-old boy, recently emigrated from Mexico, presented to the pediatric emergency department complaining of a yellow, foul-smelling discharge from the umbilicus. He noticed the drainage 3 days previously while changing out of his shirt, which had been stained yellow over the site of drainage. The following morning he experienced increasingly sharp, intermittent abdominal pain around the site of the discharge, which had increased in quantity.

The abdominal pain was located only at the site of drainage and did not radiate to any other location. The pain, however, was worse when he strained to urinate or defecate. As far as the patient recalled, the site of the drainage was clean and the skin was intact 3 days prior to presentation. On the evening the patient presented to the emergency room, he admitted that he had never had this pain or discharge before, and he denied any history of periumbilical trauma or abdominal surgery. He also denied dysuria and hematuria but conceded that he had not had a bowel movement in 2 days. The patient reported no associated nausea, vomiting, diarrhea, rash, or fever. A review of systems was completely unremarkable.

Key Point

Inflammation in the umbilical region confers high risk to the patient if pyogenic bacteria were to spread hematogenously or extend to the liver or peritoneum. It must be worked up as early as possible.

Physical Examination

The physical examination revealed a well-developed, well-nourished adolescent male with the following vital signs: oral temperature, 37.2°C (98.9°F); heart rate, 78 bpm; respiratory rate, 15 breaths/min; blood pressure, 120/84 mm Hg. His weight was at the 50th percentile and height at the 25th percentile for his age. The patient did not appear toxic or in acute distress. He was able to ambulate with minimal discomfort but preferred lying on his back. Examination of the head and neck was unremarkable. Auscultation of the chest revealed clear symmetric breath sounds and distinct S_1 and S_2 heart sounds without the presence of a murmur, rub, or gallop. A thick, yellow, purulent discharge was noted pooling around the umbilicus. No signs of traumatic injury to the skin were noted, and there was minimal erythema at the site. He had normoactive bowel sounds. He grimaced when the umbilical area was palpated, but there was no evidence of rebound tenderness. No umbilical fluctuance or lower quadrant tenderness was noted. The remainder of the examination was normal.

Key Point

The absence of rebound tenderness or other peritoneal signs is reassuring that the infection remains localized. The vital signs indicate no systemic inflammatory response, which suggests that the infection is either very acute or is localized.

Laboratory and Imaging Studies

The results of the laboratory studies are shown in **Table 1**. The adolescent was sent for an abdominal computed tomography (CT) scan (**Figure 1**). The scan showed a midline thick-walled cystic structure 3 cm in diameter, filled with fluid extending toward the upper pelvis but not contiguous with the bladder or bowel wall.

Dr. Martin is a resident in pediatrics and Dr. Lembo is an associate professor of clinical pediatrics and director of medical education, Department of Pediatrics; both are at New York University School of Medicine, New York, NY.

Table 1. Laboratory Values of Case Patient

Variable	Result	Normal Values
Blood/serum		
Leukocyte count (× 10^3/mm^3)	12.2	7.4 (4.5–11.0)
Differential count (%)		
Neutrophils	65	40–60
Lymphocytes	23	20–40
Monocytes	10	2–8
Eosinophils	1	1–4
Platelet count (× 10^3/mm^3)	291	150–350
Hemoglobin (g/dL)	15.1	15.5 (13.5)
Erythrocyte sedimentation rate (mm/h)	8	0–10
Urinalysis		
pH	6.0	4.6–8.0
Specific gravity	1.013	1.006–1.030
Nitrites	Negative	Negative
Leukocyte esterase	Negative	Negative
Erythrocytes	Negative	Negative
Leukocytes	Negative	Negative

Key Point

Despite a normal erythrocyte sedimentation rate, a moderately elevated leukocyte count, and the failure of the patient to mount a fever, the cystic structure was clearly infected, as demonstrated by umbilical pain and purulent discharge. Clinical signs in this case were more informative than the laboratory values. The clinical findings can be explained by the walled-off nature of the lesion that eventually ruptured, presumably due to increased pressure within the cavity.

- **What is the differential diagnosis for an adolescent or child with discharge from the umbilicus?**

DIFFERENTIAL DIAGNOSIS

Discharge at the umbilicus generates a narrow but important differential diagnosis. **Table 2** summarizes the differential diagnosis by usual age of presentation.

An infectious etiology for this patient's acute presentation is clear considering the presence of pus, but the more important question is why and what became infected. The contents of a discharge involving the umbilicus may include pus, urine, mucus, and/or fecal matter, depending on what lies at the end of the communicating lesion.

Figure 1. Computed tomographic scan of the case patient at presentation. A cystic, fluid-filled structure is visible at the midline (*arrow*).

The presence of feculent, bilious, seropurulent, or serous discharge at the umbilicus may indicate that the underlying defect is either an omphalomesenteric (vitelline) duct or an intestinal umbilical fistula. An omphalomesenteric duct represents the failure of the embryonic midgut to involute and break contact with the yolk sac. Such a duct may persist in nearly 2% of infants and may take the form of a Meckel diverticulum; omphalomesenteric cyst; or an umbilical fistula, polyp, or cyst. In rare cases, the duct is so large as to allow prolapse of the bowel. A study of 217 children with vitelline duct anomalies demonstrated that approximately 40% of these lesions were symptomatic, and of these, more than 80% were symptomatic within the first 2 years of life.[1] The case patient's age alone makes this diagnosis highly unlikely. In this case, the abdominal CT clearly demonstrated no communication with the bowel, but in cases in which communication with the bowel cannot be ruled out, injection of contrast agent into the umbilical orifice followed by radiography can be highly informative.

If urine is present in the discharge, a communication with the bladder is likely. This would be consistent with a urachal remnant. If this relationship is unclear, contrast radiography can be employed to better define the lesion.

In the case of this patient, pus was clearly expressed from the wound. If there had been a communication with the bladder, leukocytes, leukocyte esterase, or organisms would have been present in the patient's urine. This was not the case, and the abdominal CT scan

Table 2. Differential Diagnosis of Umbilical Discharge

Etiology	Presenting Age	Diagnostic Clues
Omphalitis	Newborn	Purulent discharge Periumbilical edema and erythema
Umbilical granuloma	Newborn	Homogenous gray mass Resolves with topical silver nitrate
Patent omphalomesenteric duct	Newborn	Feculent or bilious discharge Presence of second lumen in umbilical cord
Patent urachus	Newborn	Urine in discharge Presence of second lumen in umbilical cord
Urachal cyst	Older child/ adolescent	Purulent discharge Tender mass
Urachal carcinoma	Adult (40–70 y)	Clinically silent Nontender mass
Umbilical hernia ulceration	Any age	Skin breakdown and purulent discharge ± feculent material
Abdominal abscess	Any age	Often more lateral to umbilicus

further supported the absence of communication with the bladder. Not all urachal anomalies maintain patency with the bladder, however, and thus the diagnosis of a urachal anomaly could not be ruled out.

Although typically not seen until middle age, urachal carcinomas likewise can present with umbilical discharge and a mass. This constellation of findings would necessitate either a biopsy or surgical excision with histologic analysis for confirmatory purposes.

The differential diagnosis of purulent umbilical discharge includes omphalitis, umbilical granuloma, and abdominal abscess. Omphalitis is an inflammation of the umbilicus and surrounding skin in neonates that results from inadequate hygiene and cord care. During the delivery process, bacteria from the mother's genital tract and the environment colonize the cord stump. Umbilical granulomas represent persistence of exuberant granulation tissue at the base of the umbilicus. These lesions often express a seropurulent secretion. Both of these conditions are unique to the neonate and are not seen later in life. This review will focus, therefore, on umbilical discharge appearing later in life. The reader interested in a review of umbilical discharge in the newborn period is referred to the review by O'Donnell et al.[2]

Abdominal abscesses may occur at any age and can present throughout a person's life as a complication of a number of illnesses, including postsurgical complications or appendicitis. The patient's history makes this diagnosis unlikely, but it could not have been ruled out prior to imaging.

Figure 2. Computed tomographic scan of the case patient on hospital day 7.

Key Point

Of urachal anomalies, the urachal cyst is the most common to present later in life.

CLINICAL COURSE

The patient was admitted to the hospital with a presumptive diagnosis of an infected urachal remnant. The initial management was administration of broad-spectrum intravenous antibiotic therapy, including metronidazole, ampicillin, and gentamicin, until an adequate culture of the purulent material could be obtained, an organism or organisms identified, and

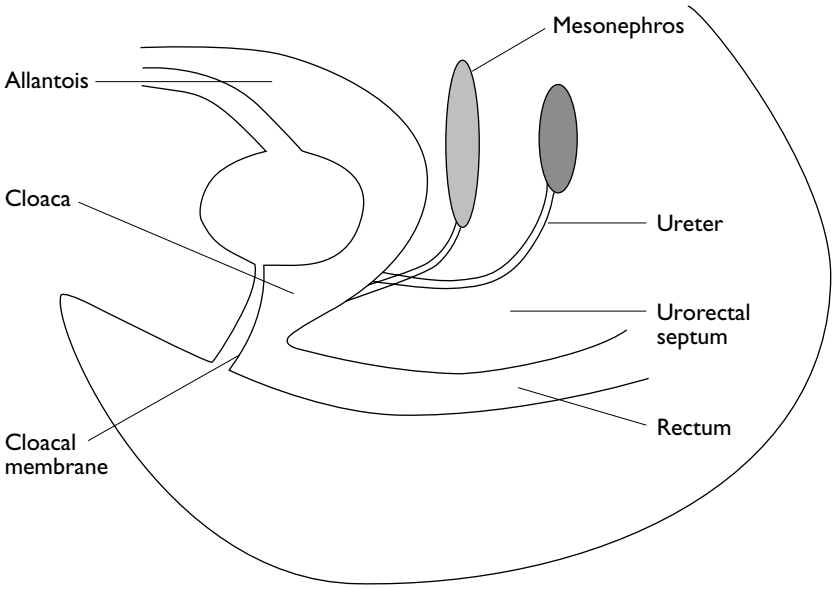

Figure 3. Embryologic precursors of the urachus and omphalomesenteric duct. The urachus forms from the involution of the allantoic duct and the ventral cloaca. (Adapted with permission from Yu JS, Kim KW, Lee HJ, et al. Urachal remnant diseases: spectrum of CT and US findings. RadioGraphics 2001;21:452.)

antibiotic sensitivities defined. Broad-spectrum antimicrobial coverage was chosen initially because a number of organisms could be responsible for the infection. A cotton swab was inserted into the opening of the wound to obtain the innermost material and was sent for culture and organism identification. The patient remained afebrile and the Gram stain demonstrated gram-positive cocci.

On hospital day 2, the culture demonstrated mixed bacterial flora with predominant growth of *Staphylococcus aureus*. Broad-spectrum therapy was continued pending final identification of the organisms and their corresponding sensitivity profiles. Throughout the course of the next week of therapy, the patient remained afebrile with relative improvement in pain and a gradual decrease in the amount of discharge. A repeat abdominal CT scan obtained on hospital day 7 demonstrated that the cystic structure remained ventral to the posterior fascia and communicated with the umbilicus (**Figure 2**). Of note, the repeat imaging study demonstrated an increase in edema, which may have sealed off the point of external drainage of the lesion and accounted for the large amount of fluid that now appeared inside the structure. After surgical consultation, the decision was made to incise and drain the wound while continuing medical management.

During the incision procedure, multiple cultures were obtained that again demonstrated the predominant growth of *S. aureus*. The patient was then switched to cefazolin based on culture sensitivities for an additional week, at which time a follow-up CT scan demonstrated resolution of the fluid accumulation. The patient was then discharged home with a later surgical appointment for excision of the most likely lesion, a urachal cyst.

URACHAL REMNANTS

Because many urachal anomalies do not cause symptoms and thus fail to come to the clinician's attention, their discovery often is incidental. For this reason, urachal anomalies may be more common in the general population than we recognize. Only one third of urachal cysts that become clinically apparent do so in infancy or childhood.[3] Understanding the anatomy and embryology of urachal cysts and remnants is critical in making the correct diagnosis and choosing an effective management strategy, which can avoid the complications of intraperitoneal rupture or subsequent malignancy.

Embryology

The urachus is a fibrous cord located in the extraperitoneal tissues of the anterior abdominal wall. It develops from the cloaca, which ultimately becomes the bladder, and the allantois, an outpouching of the yolk sac that appears around the 16th fetal day of life (**Figure 3**). The bladder opens into the allantois at the level of the umbilicus in the first months of life, thus forming what is to become the urachus. Unlike the omphalomesenteric duct, which disappears sometime between the 5th and the 9th fetal week, the urachus evolves into a fibromuscular band connecting the bladder and allantois. Following birth, this structure is termed the *median umbilical ligament*. It lies between the transverse fascia and the

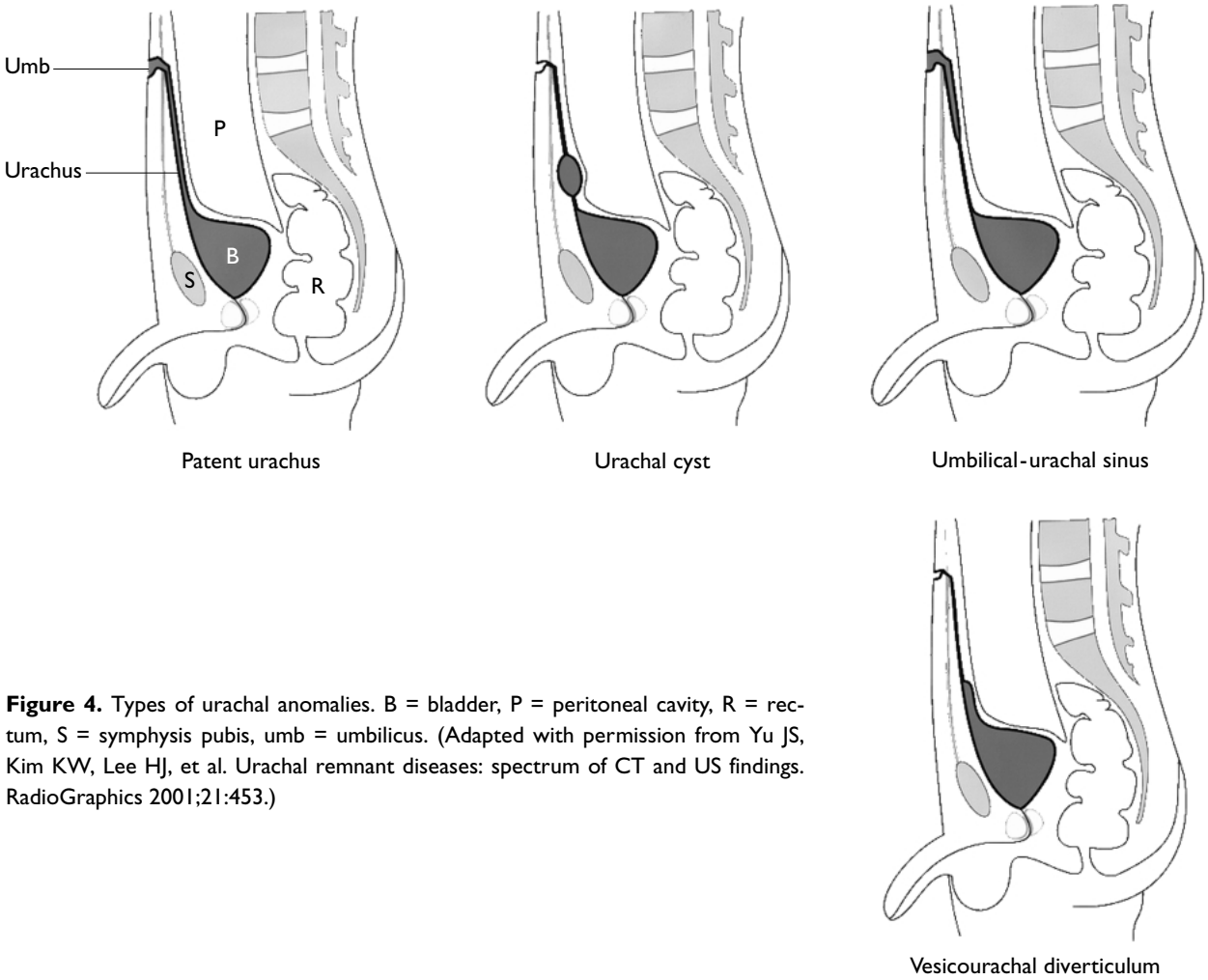

Figure 4. Types of urachal anomalies. B = bladder, P = peritoneal cavity, R = rectum, S = symphysis pubis, umb = umbilicus. (Adapted with permission from Yu JS, Kim KW, Lee HJ, et al. Urachal remnant diseases: spectrum of CT and US findings. RadioGraphics 2001;21:453.)

parietal peritoneum, where it is compartmentalized by the umbilicovesical fascia. It is unclear when during the postpartum period the urachus becomes nonpatent. In up to one third of adults, some evidence exists that constriction of the urachus is not complete, and microscopically, the urachus remains patent.[4]

Clinical Manifestations

If the urachus fails to regress, 4 distinct types of urachal anomalies may arise (**Figure 4**). In order of frequency, they are a patent urachus (50%), a urachal cyst (30%), an umbilical-urachal sinus (15%), and a vesicourachal diverticulum (3%–5%).[5]

A patent urachus represents a persistent communication between the bladder and the umbilicus. It usually is discovered in infancy owing to urine leakage from the umbilicus. The first clue is often a giant umbilical cord, which represents swelling of Wharton's jelly resulting from absorption of hypotonic fetal urine. One third of these cases are associated with posterior urethral valves or urethral atresia.

A urachal cyst is a noncommunicating dilatation from the umbilicus that presents to the clinician when complicated by infection, as was the case for this patient. Infection may take many years to develop, usually as an abscess that ultimately drains spontaneously through the umbilicus. In rare cases, it ruptures into the peritoneal cavity. Cysts usually occur in the lower third of the urachus. The overall incidence of urachal cysts is estimated at 1 case per 5000 births, with a male:female ratio of 2–3:1.[6,7] Infection of urachal cysts usually develops from retrograde bacterial migration via the umbilicus but also can occur via the urinary tract or by lymphatic or hematogenous spread.

An umbilical-urachal sinus is a blind tract ending at the umbilicus. Not infrequently, the sinus becomes infected. Signs of infection include generalized pain, fever, periumbilical pain, erythema, and drainage.

The vesicourachal diverticulum represents a distal dilatation of the bladder extending towards the umbilicus but not communicating with it. Its discovery is almost always incidental with no clinical significance. It becomes symptomatic only in the rare case when it contains stagnant urine predisposing to chronic infection.

Imaging Modalities

Urachal pathology may not be definitively diagnosed until surgical excision, but this is rare. More commonly, the diagnosis is made preoperatively by a number of different radiographic modalities, including ultrasound, CT, and sinography. No large scale studies exist comparing the various imaging techniques, but smaller scale studies are suggestive of the advantages of each.

Two studies found that ultrasound was slightly more accurate than sinography in diagnosing urachal cysts, whereas sinography proved more accurate than ultrasound in the diagnosis of urachal sinuses.[3,8] These studies also suggest that ultrasound is more effective in diagnosing fluid-filled masses, while sinography is more effective in diagnosing an already patent sinus tract.

Abdominal CT is emerging as an important adjunctive modality when more precise definition of the abdominal wall is required. Recent experience suggests that abdominal CT scans are more sensitive than ultrasonography or sinography in diagnosing all types of urachal anomalies.[9,10] The choice of imaging modality thus largely depends on what is readily available in the clinical setting and on the skills of the radiologist interpreting the test results. An open dialogue with the radiologist should be pursued prior to ordering a specific imaging modality in order to assure an accurate anatomic diagnosis.

Treatment

The effective treatment of infected urachal cysts consists of a course of intravenous antibiotics to allow more rapid resolution of the adjacent inflammatory process and to limit the spread of pathogens. This treatment ultimately reduces the later surgical risk of wound infection. If antibiotics prove ineffective in resolving the infection, as was the case in this patient, the cyst may be drained extraperitoneally. Antibiotics should be tailored to the organism(s) isolated from a wound culture. The culture may be obtained by insertion of a swab into the wound when discharge is present; percutaneous aspiration provides an alternative method of directly obtaining material for culture. This method potentially minimizes the risk of contaminating the culture specimen with skin flora. Because infection of a urachal anomaly usually is caused by bacterial migration from either the urinary tract or the umbilicus, the organisms involved reflect pathogens usually encountered at these sites. The most common of these organisms are *S. aureus*, *Escherichia coli*, *Enterococcus* species, *Citrobacter* species, and *Proteus* species.[11]

Excision of the cyst following resolution of the acute infection is the treatment of choice. The surgery generally is a staged process. The tissue contained with the umbilicovesical fascia (including the urachus, medial umbilical ligaments, the adjacent peritoneum, and a cuff of the bladder wall) is resected in a surgical technique termed *partial cystectomy*. The dome of the bladder is included in the resection to provide a wide surgical margin and guarantee complete resection of the urachal tissue. This procedure can be performed laparoscopically in adults and increasingly in children.[11,12] Without resection, a 30% reinfection rate has been observed.[5] The risk of urachal tissue transforming into a carcinoma also weighs heavily in the decision to excise the lesion.

The management of those cysts discovered incidentally pose a clinical challenge. Traditionally, resection has not been advocated; but in light of the increased risk of urachal carcinoma, which has a poor prognosis, it is a tenuous argument.[13] The risk of reinfection alone provides adequate reason to perform an excision of the urachal cyst. The complications of these infections can include acute hemorrhage, intraperitoneal rupture, systemic sepsis, and even death.[14–19] Once the abscess ruptures, the clinical symptoms may mimic an acute appendicitis, pelvic inflammatory disease, or inflammatory bowel disease. This differential diagnosis often warrants an unnecessary exploratory laparotomy.

Prognosis

In addition to a 30% reinfection rate, failure to completely remove a urachal cyst that has become infected confers a number of other risks to the patient. Reported complications include progressive enlargement of the cyst, stone formation, acute hemorrhage, and either fistula or abscess formation. Fortunately, these complications are exceedingly rare and are documented by only a handful of cases in the literature.[14,20–22]

Of more concern is the malignant potential of primitive urachal tissue. The development of malignant neoplasms is rare and accounts for less than 0.5% of all bladder cancers.[23] Neoplasms developing within urachal cysts are even rarer, with only several cases reported in the literature. These cancers are predominantly adenocarcinomas, although only 34% of bladder adenocarcinomas are of urachal origin.[24] These are

silent tumors that go undetected until they have already metastasized. The overall 5-year survival rate with such neoplasms is only 10%.[24] Despite their rarity, therefore, prevention through surgical removal of the urachal tissue is a compelling management strategy.

CONCLUSION

Umbilical discharge in any age patient should be swiftly evaluated. Failure to make the right diagnosis may result in a poor outcome, including septic shock and death. As this case demonstrates, urachal anomalies always should be included in the differential diagnosis of umbilical discharge at any age. Urachal anomalies generally are identified either when a patient presents due to infection or as an incidental finding on abdominal imaging studies.

The history and laboratory studies may not enable the clinician to completely narrow the differential, and imaging may be fundamental to securing a timely diagnosis. Ultrasound and abdominal CT scans are very sensitive in detecting urachal remnants, but sinography maintains a pivotal role in many workups when a sinus tract is a possibility.

Most infected urachal cysts are not excised immediately; a prolonged course of preoperative antibiotics is required to reduce the risk of complications of surgery. A staged approach to partial cystectomy usually is chosen, and such an approach carries an excellent prognosis. **HP**

REFERENCES

1. Vane DW, West KW, Grosfeld JL. Vitelline duct anomalies. Experience with 217 childhood cases. Arch Surg 1987;122:542–7.
2. O'Donnell KA, Glick PL, Caty MG. Pediatric umbilical problems. Pediatr Clin North Am 1998;45:791–9.
3. Mesrobian HG, Zacharias A, Balcom AH, Cohen RD. Ten years of experience with isolated urachal anomalies in children. J Urol 1997;158(3 Pt 2):1316–8.
4. Schubert GE, Pavkovic MB, Bethke-Bedurftig BA. Tubular urachal remnants in adult bladders. J Urol 1982;127: 40–2.
5. Goldman IL, Caldamone AA, Gauderer M, et al. Infected urachal cysts: a review of 10 cases. J Urol 1988;140: 375–8.
6. Rubin A, editor. Handbook of congenital malformations. Philadelphia: W. B. Saunders; 1967.
7. Friedland GW, Devries PA, Matilde NM, et al. Congenital anomalies of the urinary tract. In: Pollack HM, editor. Clinical urography: an atlas and textbook of urological imaging. Philadelphia: WB Saunders; 1990:559–787.
8. Cilento BG Jr, Bauer SB, Retik AB, et al. Urachal anomalies: defining the best diagnostic modality. Urology 1998;52:120–2.
9. Yu JS, Kim KW, Lee HJ, et al. Urachal remnant diseases: spectrum of CT and US findings. RadioGraphics 2001;21: 451–61.
10. Iuchtman M, Rahav S, Zer M, et al. Management of urachal anomalies in children and adults. Urology 1993; 42:426–30.
11. Cadeddu JA, Boyle KE, Fabrizio, MD, et al. Laparoscopic management of urachal cysts in adulthood. J Urol 2000;164:1526–8.
12. Khurana S, Borzi PA. Laparoscopic management of complicated urachal disease in children. J Urol 2002; 168(4 Pt 1):1526–8.
13. Minevich E, Wacksman J, Lewis AG, et al. The infected urachal cyst: primary excision versus a staged approach. J Urol 1997;157:1869–72.
14. Davidson BR, Brown NJ, Neoptolemos JP. Haemorrhage into a urachal cyst presenting as an 'acute abdomen.' Postgrad Med J 1987;63:493–4.
15. Pesce C, Costa L, Musi L, et al. Relevance of infection in children with urachal cysts. Eur Urol 2000;38:457–60.
16. Akintan B, Adekunle A. A fatal case of ruptured infected urachal cyst. Int Urol Nephrol 1985;17:133–8.
17. Chen TF, Collier DS. Intraperitoneal rupture of an infected urachal cyst in an infant. Eur J Surg 1991;157:67–8.
18. Yoshimura K, Toki K, Koide T, et al. Infantile granulomatous urachal abscess with acute localized peritonitis and appendicitis. Int J Urol 1994;1:352–4.
19. Ogbevoen JO, Jaffe DM, Langer JC. Intraperitoneal rupture of an infected urachal cyst: a rare cause of peritonitis in children. Pediatr Emerg Care 1996;12:41–3.
20. Diehl K. A rare case of urachal calculus. Br J Urol 1991; 67:327–8.
21. Agatstein EH, Stabile BE. Peritonitis due to intraperitoneal perforation of infected urachal cysts. Arch Surg 1984;119:1269–73.
22. Valda V, Conn MJ. Spontaneous rupture of a noninfected urachal cyst. J Pediatr Surg 1991;26:747–8.
23. Sheldon CA, Clayman RV, Gonzalez R, et al. Malignant urachal lesions. J Urol 1984;131:1–8.
24. Ravi R, Shrivastava BR, Chandrasekar GM, et al. Adenocarcinoma of the urachus. J Surg Oncol 1992;50:201–3.

Copyright 2004 by Turner White Communications Inc., Wayne, PA. All rights reserved.