Lung Abscess and Empyema: Review Questions

Madhuri M. Sopirala, MD

QUESTIONS

Choose the single best answer for each question.

Questions 1 and 2 refer to the following case.

A 56-year-old man presents to the emergency department (ED) complaining of blood-tinged sputum. The patient reports a 15-lb weight loss and productive cough with foul-smelling sputum over the last 2 months. He has had subjective fever and has awakened almost every night drenched in sweat. He drinks 10 beers every day. On physical examination, the patient has a blood pressure of 134/92 mm Hg, heart rate of 102 bpm, respiratory rate of 22 breaths/min, and temperature of 100°F. The patient has gingivitis and digital clubbing, and lung examination reveals coarse inspiratory crackles predominantly in the lower lobe of the right lung. Laboratory testing reveals a leukocyte count of 16,000 cells/µL with 93% polymorphonuclear neutrophils. Gram stain of a sputum specimen reveals numerous polymorphonuclear leukocytes with a mixture of gram-positive cocci in chains and gram-negative bacilli. Blood culture shows no growth of microorganisms. Chest radiograph is unremarkable, and a computed tomography scan shows a right-sided cavitary lung lesion (**Figure 1**).

1. **What is the most appropriate initial step in the management of this patient?**
   (A) Clindamycin
   (B) Parenteral penicillin
   (C) Surgical drainage
   (D) Surgical drainage and clindamycin
   (E) Surgical drainage and penicillin

2. **Which of the following is the most likely cause of this patient's lung abscess?**
   (A) *Fusobacterium* species and microaerophilic *Streptococcus* species
   (B) *Nocardia* species
   (C) *Pseudomonas aeruginosa*
   (D) *Staphylococcus aureus*
   (E) *Streptococcus pneumoniae*

Figure 1. Computed tomography scan of the patient described in questions 1 and 2.

Questions 3 and 4 refer to the following case.

A 68-year-old woman with a history of cerebrovascular accident with no residual loss of motor function and chronic bronchitis presents to the ED with shortness of breath, which has been progressively worsening for the last 4 months. She was treated with a 5-day course of azithromycin at least twice during the course of her illness without clinical improvement. A recent chest radiograph showed a cavitary lung lesion in the middle of a consolidative area in the left lower lobe. At this visit, bronchoscopy reveals granulomatous lesions and obstruction of the left lower lobe bronchus by a yellowish-white foreign body that looked like worn out popcorn when removed. Further history reveals that the patient likes to eat popcorn leaning towards her left side on her couch while watching television. Pathologic evaluation of the foreign body reveals vegetable matter. Gram stain of the biopsy specimen obtained during bronchoscopy reveals filamentous elements of gram-positive rods that are negative by acid-fast and partially acid-fast

Dr. Sopirala is an assistant professor of infectious diseases and assistant medical director of clinical epidemiology, Ohio State University Medical Center, Columbus, OH.

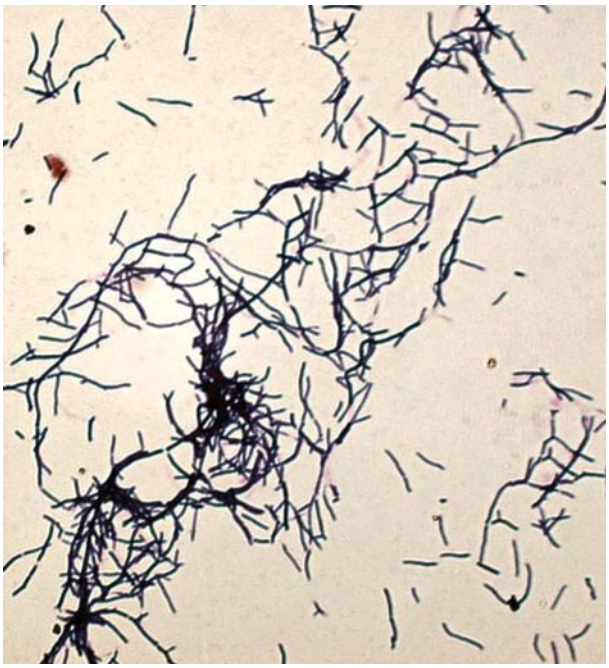

Figure 2. Gram stain of the specimen obtained from the patient described in questions 3 and 4 showing filamentous gram-positive bacilli.

techniques (**Figure 2**). Aerobic culture shows no growth of microorganisms.

3. **Which organism is most likely the cause of this patient's disease?**
   (A) *Actinomyces* species
   (B) *Clostridium* species
   (C) *Klebsiella pneumoniae*
   (D) *Nocardia* species
   (E) *Streptococcus pneumoniae*

4. **What is the most appropriate initial step in this patient's management?**
   (A) Ciprofloxacin
   (B) Ciprofloxacin and surgical drainage
   (C) Penicillin
   (D) Penicillin and surgical drainage
   (E) Tetracycline

5. **A 68-year-old man who recovered from the flu 2 weeks ago presents to the ED with progressive shortness of breath and pleuritic chest pain on the right side. He was released from prison 3 months ago. The patient reports having a productive cough, fever up to 104°F, chills, and night sweats for the last 4 days. He attempted to alleviate his symptoms with over-the-counter medications, but symptoms persisted. Lung examination is significant for dullness to percussion and absent breath sounds in the right lower lobe. A chest radiograph shows a large free-flowing right-sided pleural effusion. Thoracentesis reveals a pleural fluid with a pH of 7.1, glucose level of 36 mg/dL, and lactate dehydrogenase level of 800 U/L. Gram stain of the pleural fluid shows numerous polymorphonuclear leukocytes with intracellular gram-positive cocci in groups. What is the next best step in the management of this patient?**
   (A) Chest tube placement and intravenous (IV) ampicillin/sulbactam
   (B) Chest tube placement and IV vancomycin
   (C) IV vancomycin
   (D) Surgical decortication
   (E) Surgical decortication and IV vancomycin

ANSWERS AND EXPLANATIONS

1. **(A) Clindamycin.** This patient has aspirated and developed a lung abscess. Risk factors for aspiration include periodontal disease, alcoholism, and seizure disorder. Patients with an anaerobic lung abscess present with an indolent clinical course of low-grade fever, productive cough with foul-smelling sputum, anorexia, and weight loss that evolves over a period of weeks to months. Anaerobes are recovered in up to 89% of patients with lung abscesses, with the most common being *Peptostreptococcus, Bacteroides*, and *Fusobacterium* species and microaerophilic *Streptococcus* species.[1] Standard treatment for an anaerobic lung abscess is a prolonged course of clindamycin (4–6 wk or until resolution of the lung abscess or stabilization of the abscess into a small lesion).[1] Although penicillin is effective against most oropharyngeal anaerobes, it is ineffective against β-lactamase–producing anaerobes such as *Fusobacterium* and *Bacteroides*.[2] Most patients with primary lung abscess improve with antibiotics, with cure rates of 90% to 95%.[3] Surgical drainage of the lung abscess is indicated when antibiotic therapy has failed.

2. **(A) *Fusobacterium* species and microaerophilic *Streptococcus* species.** *Fusobacterium* species and microaerophilic *Streptococcus* species are more frequently identified as causes of lung abscess as compared with other microorganisms such as *Nocardia* species, *P. aeruginosa*, *Staphylococcus aureus*, and *Streptococcus pneumoniae*.[1] This patient's clinical history and aerobic culture showing no growth of microorganisms on Gram stain also support this diagnosis. If aspiration

occurs while the patient is in the hospital, *Staphylococcus aureus, P. aeruginosa*, and *Enterobacter* species should be considered as potential pathogens.

3. **(A) *Actinomyces* species.** *Actinomyces* species can cause a subacute to chronic suppurative granulomatous infection in the lungs, usually after aspiration of oropharyngeal secretions. *Actinomyces* are filamentous, gram-positive, non–acid-fast anaerobic to microaerophilic bacteria. They typically resemble *Nocardia* species on Gram stain, but *Nocardia* is aerobic and will yield positive results on partially acid-fast staining.[4] *K. pneumoniae*, *Streptococcus pneumoniae*, and *Clostridium* species do not match the description of the organism found on Gram stain.

4. **(C) Penicillin.** Penicillin G is the drug of choice for treating an infection caused by *Actinomyces* species. Most clinicians administer penicillin for 6 to 12 months depending on clinical improvement.[5] Surgical drainage is not necessary in most cases, and attempts should be made to treat even extensive disease with antibiotic drugs.[6] Tetracycline and ciprofloxacin are ineffective against *Actinomyces*.[7]

5. **(B) Chest tube placement and IV vancomycin.** This patient had an empyema most likely secondary to methicillin-resistant *Staphylococcus aureus* (MRSA). He is at risk for MRSA infection since he has been incarcerated in the recent past and had the flu.[8,9] In this case, chest tube placement and drainage is indicated along with initiation of appropriate antibiotic treatment. Indications for drainage of an empyema are as follows: pleural fluid pH less than 7.20, glucose level less than 60 mg/dL, lactate dehydrogenase level greater than 600 U/L, and bacteria on Gram stain.[10] Empiric treatment with an antibiotic, such as IV vancomycin, with a spectrum that covers MRSA is appropriate.[11] Final therapy decisions should be based on results of cultures and antimicrobial susceptibility testing.[11] Ampicillin/sulbactam has no activity against MRSA.[11] Surgical intervention is indicated for effusions with multiple loculations or those that have not responded to catheter drainage and for empyema at the organizing stage.

REFERENCES

1. Bartlett JG, Gorbach SL, Tally FP, Finegold SM. Bacteriology and treatment of primary lung abscess. Am Rev Respir Dis 1974;109:510–8.
2. Appelbaum PC, Spangler SK, Jacobs MR. Beta-lactamase production and susceptibilities to amoxicillin, amoxicillin-clavulanate, ticarcillin, ticarcillin-clavulanate, cefoxitin, imipenem, and metronidazole of 320 non-*Bacteroides fragilis Bacteroides* isolates and 129 fusobacteria from 28 U.S. centers. Antimicrob Agents Chemother 1990;34:1546–50.
3. Bartlett JG. HIV infection and surgeons. Curr Probl Surg 1992;29:197–280.
4. Hsieh MJ, Liu HP, Chang JP, Chang CH. Thoracic actinomycosis. Chest 1993; 104:366–70.
5. Choi J, Koh WJ, Kim TS, et al. Optimal duration of IV and oral antibiotics in the treatment of thoracic actinomycosis. Chest 2005;128:2211–7.
6. Endo S, Murayama F, Yamaguchi T, et al. Surgical considerations for pulmonary actinomycosis. Ann Thorac Surg 2002;74:185–90.
7. Smith AJ, Hall V, Thakker B, Gemmell CG. Antimicrobial susceptibility testing of *Actinomyces* species with 12 antimicrobial agents. J Antimicrob Chemother 2005;56:407–9.
8. Hageman JC, Uyeki TM, Francis JS, et al. Severe community-acquired pneumonia due to *Staphylococcus aureus*, 2003–04 influenza season. Emerg Infect Dis 2006;12:894–9.
9. Naimi TS, LeDell KH, Como-Sabetti K, et al. Comparison of community- and health care–associated methicillin-resistant *Staphylococcus aureus* infection. JAMA 2003;290:2976–84.
10. Colice GL, Curtis A, Deslauriers J, et al. Medical and surgical treatment of parapneumonic effusions: an evidence-based guideline [published erratum appears in Chest 2001;119:319]. Chest 2000;118:1158–71.
11. Gorwitz RJ, Jernigan DB, Powers JH, Jernigan JA. Strategies for clinical management of MRSA in the community: summary of an experts' meeting convened by the Centers for Disease Control and Prevention. 2006. Available at www.cdc.gov/ncidod/dhqp/pdf/ar/CAMRSA_ExpMtgStrategies.pdf. Accessed 21 Jan 2009.

Copyright 2009 by Turner White Communications Inc., Wayne, PA. All rights reserved.