A 60-Year-Old Man with Generalized Weakness, Weight Loss, and Right-Sided Flank Pain

Dmitri Souzdalnitski, MD, PhD
Nicolai Mejevoi, MD, PhD
David Weisman, DO

CASE PRESENTATION

History

A 60-year-old man presented to the emergency department complaining of fever, chills, and generalized weakness. Approximately 1 month prior to presentation, he developed fever and malaise, followed by chills, cough with a small amount of sputum, and constant, dull right-sided flank pain; he developed nausea, vomiting, hiccups, and diarrhea on the day prior to presentation. He also reported a 10-lb weight loss over the previous month. He denied any past medical history or recent travel abroad.

Patient Evaluation

On physical examination, the patient was an ill-appearing man with a fever of 102.1°F. Pertinent examination findings included decreased breath sounds at both lung bases, which was more pronounced on the right side, and mild tenderness and guarding in the right upper quadrant of the abdomen. His white blood cell count was $16.0 \times 10^3/\mu L$, and he had a microcytic anemia with a hemoglobin of 10.4 g/dL (normal, 14.0–17.5 g/dL) and mean corpuscular volume of 79 fL (normal, 80–96 fL). Electrolytes and glucose levels were normal. Liver function tests showed an elevated alkaline phosphatase to 157 U/L (normal, 38–126 U/L) but were otherwise normal. A chest radiograph showed bibasilar atelectasis. An abdominal ultrasound scan was performed to rule out acute cholecystitis. It showed a 10 × 9-cm cystic liver mass with low-grade flow through the mass and no gallstones (**Figure 1**). The presence of a mass was confirmed by computed tomography (CT; **Figure 2**).

Figure 1. Ultrasound image showing a 10 × 9-cm cystic liver mass and no gallstones.

WHAT IS YOUR DIAGNOSIS?

(A) Cavernous hemangioma
(B) Hepatic adenoma
(C) Inflammatory pseudotumor
(D) Pyogenic liver abscess
(E) Nodular regenerative hyperplasia
(F) Echinococcal cysts

Dr. Souzdalnitski is an internal medicine resident, Dr. Mejevoi is chief resident of the internal medicine program, and Dr. Weisman is an assistant program director of internal medicine; all are at the Good Samaritan Hospital of Baltimore, Baltimore, MD.

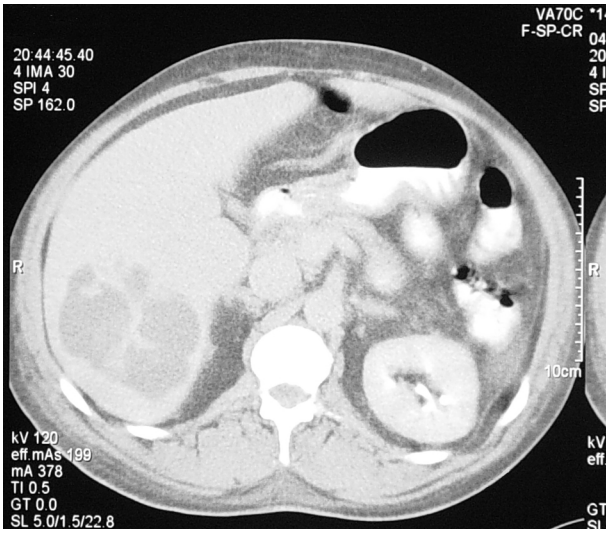

Figure 2. Abdominal computed tomography scan of the case patient demonstrating a liver mass.

ANSWER

The correct answer is (D), pyogenic liver abscess (PLA).

DISCUSSION

Cavernous hemangioma is the most common benign tumor of the liver. The usual clinical presentation of this condition is an incidental finding during ultrasonographic examination of the abdomen for unrelated reasons. Hemangiomas typically measure less than 5 cm and are asymptomatic[1]; therefore, hemangioma is unlikely to have caused the patient's general clinical symptoms of fever, chills, weight loss, and malaise. Hepatic adenoma is a benign epithelial tumor that is most commonly seen in women older than 30 years, with most patients having used oral contraceptives for more than 2 years prior to diagnosis[1]; some patients may present with catastrophic intra-abdominal bleeding due to rupture of the adenoma. The mass found in the patient's liver showed low-grade blood flow, which is not a feature of a solid liver mass such as hepatic adenoma.[2]

Inflammatory pseudotumor is a rare benign tumor composed of proliferating fibrous tissue infiltrated by inflammatory cells. This lesion frequently occurs in association with a systemic chronic disease and typically does not show signs of blood flow. Nodular regenerative hyperplasia is a condition wherein multiple foci of proliferating hepatocytes form nodules throughout the liver.[2] This condition is commonly associated with a systemic autoimmune disease and occurs more frequently among the elderly. Patients may develop presinusoidal portal hypertension, which may be complicated by variceal bleeding.[1]

Echinococcal (hydatid) cysts of the liver are caused by the larval form of *Echinococcus granulosus,* which is usually acquired from infected dogs. Most patients are asymptomatic, but some may present with abdominal pain, fever, and hepatomegaly.[1] These cysts are fluid-filled structures limited by a parasite-derived membrane that contains germinal epithelium.[3] On radiologic imaging, hydatid cysts appear as well-defined lesions with distinguishable walls, sometimes with calcified rims and intracystic septations, and daughter cysts. A peripheral eosinophilia is usually present.[1] Serologic testing can be helpful in making the diagnosis of hydatid cysts. The clinical and radiographic presentation in this patient is not consistent with hydatid disease.

Another diagnostic consideration in the evaluation of a liver mass is hepatoma, which is classically found in patients with hepatitis B or C. Alpha fetoprotein testing and, ultimately, liver biopsy are necessary for the diagnosis of this condition. The patient presented here did not have a history of viral hepatitis. PLA was suggested by the gradual onset of fever, chills, malaise, and weight loss, right upper tenderness on examination, along with leukocytosis and the presence of a typical lesion in the liver on imaging studies. The diagnosis was confirmed by ultrasound-guided percutaneous liver drainage.

PYOGENIC LIVER ABSCESS

Epidemiology

PLA has an annual incidence in North America of 2.3 cases per 100,000 persons without an associated seasonal trend. In the first half of the 20th century, liver abscess was described as a condition affecting predominantly young men in the setting of an intra-abdominal infection.[4] Currently, most patients with PLA are elderly men. Patients aged 65 years and older are 10 times more likely to acquire a PLA as compared with younger individuals.[5] Men are at a 2.6-fold increased risk of acquiring a PLA compared with women regardless of age. Liver transplantation, diabetes, alcoholism, and history of a malignancy were identified as significant risk factors for developing PLA.[5]

Etiology and Pathogenesis

Most PLAs are polymicrobial, with various anaerobic bacteria identified in the abscess. Historically, *Escherichia coli* has been the predominant pathogen. Recently, *Klebsiella* species surpassed *E. coli* as the most common single isolate from patients with PLA in some countries.[6] Pyogenic abscess associated with recurrent pyogenic cholangitis may be caused by *Salmonella typhi, Clostridium*

species, and *Actinomyces* species. PLAs caused by *Staphylococcus aureus* are most common in children and patients with septicemia or impaired host resistance. PLAs are cryptogenic in more than half of cases; approximately one quarter are biliary in origin. Colonic and hematogenic sources of PLAs are also common. Rare causes are gastrointestinal tract perforation, traumatic liver injury, and colon cancer or colon surgery.[7]

Clinical Presentation

In the past, patients with a PLA typically presented with high fever and right upper quadrant pain; in many cases, shock was also present. Since the introduction of antibiotics, the presentation of PLA has become less acute, often insidious. Clinical symptoms are nonspecific and may be present for more than 1 month before the diagnosis is made. In a large population-based study in North America, the median time to presentation was 7 days, whereas the median time to diagnosis was 11 days. Clinical features in these patients included fever (73%), chills (45%), right upper quadrant pain (38%), nausea (30%), and fatigue (24%).[5]

Diagnostic Studies

A thorough history and physical examination are crucial for establishing the diagnoses of PLA. Laboratory findings include anemia, leukocytosis, an elevated erythrocyte sedimentation rate, and abnormal liver biochemical tests, especially an elevated serum alkaline phosphatase level. Blood culture may identify the causative organism in 22% to 50% of cases.[4] Abdominal ultrasound is the simplest way to diagnose any liver lesion.[8] Seventy percent of abscesses are found in the right lobe of the liver, and 77% are solitary lesions.[4] Single or multiple abscesses may be present, and ultrasound may also help identify the original source of the sepsis, such as an obstructed biliary tree. Smaller abscesses not detected on ultrasound may be visible on CT scan or endoscopic retrograde cholangiopancreatography.[9] Aspiration of purulent material usually leads to the definitive diagnosis. This material should be sent for full microbiologic and pathologic studies. Cultures are positive in 63% of cases, and the results guide antibiotic therapy.[5] Cytologic examination of the aspirate is important to exclude an underlying malignancy or benign neoplasm.

Treatment

Because untreated PLA is almost uniformly fatal,[10] early diagnosis and treatment are crucial. The optimal treatment of PLA is intravenous broad-spectrum antibiotics with activity against gram-negative aerobic and anaerobic bacteria and percutaneous drainage. If the abscess is thought to be the result of biliary sepsis, antibiotics that achieve good concentration in the bile should be selected. After culture results and sensitivity profiles have been obtained, antibiotic therapy directed against the specific organism(s) should be administered intravenously for 2 weeks and then orally for an additional 6 weeks.[11]

Conservative treatment with antibiotics alone may be an option in selected patients, especially those who have smaller abscesses and are clinically stable. The preferred approach, however, is drainage via fine-needle aspiration under ultrasound guidance, which may need to be repeated, particularly if there are multiple lesions. Percutaneous catheter drainage is another approach but is generally only practical if there is 1 large accessible abscess. Fine-needle aspiration should be considered as a first-line drainage approach because of procedure simplicity, patient comfort, and lower cost.[12] Surgical drainage of a PLA may be necessary in patients with a large abscess, incomplete percutaneous drainage, unresolved jaundice, renal impairment, a multiloculated abscess, or a ruptured abscess.[13] In cases where medical therapy has failed, laparoscopy with intravenous antibiotics is a safe alternative for patients requiring surgical drainage.[14]

Prognosis

PLA-related mortality has improved in recent years, decreasing from 31% to between 2.5% and 8% over the past 2 decades.[4] A worse prognosis is associated with a delay in diagnosis, multiple organisms cultured from blood, a fungal abscess, jaundice, hypoalbuminemia, pleural effusion, an underlying biliary malignancy, and multiorgan dysfunction. Complications of PLA include empyema, pleuropericardial effusion, portal or splenic vein thrombosis, rupture into the pericardium, thoracic and abdominal fistula formation, and sepsis. Lack of clinical awareness and failure to diagnose PLA rather than inadequate therapy are responsible for the mortality rate.[15]

CLINICAL COURSE OF CASE PATIENT

A CT scan of the abdomen and pelvis and ultrasound of the right upper quadrant did not show biliary or colon pathology. Therefore, the etiology of the PLA in the patient remained unknown. The patient was started on piperacillin/tazobactam and metronidazole. Ultrasound-guided drainage was carried out with immediate evacuation of 170 mL of frank pus, and a drain was left in place. The abscess culture grew *K. pneumoniae*, and blood cultures remained negative. A repeat CT scan 12 days after

initial treatment showed a significant decrease in the abscess size, and the drain was removed. Oral antibiotics were continued for 4 more weeks. **HP**

REFERENCES

1. Choi BY, Nguyen MH. The diagnosis and management of benign hepatic tumors. J Clin Gastroenterol 2005;39: 401–12.
2. Chen JH, Chen WP, Huang CL, Shen WC. Dynamic helical CT as a novel technique for diagnosing hepatic perfusion disorders. Hepatogastroenterology 1999;46:303–7.
3. Haddad MC, Birjawi GA, Khouzami RA, et al. Unilocular hepatic echinococcal cysts: sonography and computed tomography findings. Clin Radiol 2001;56:746–50.
4. Rahimian J, Wilson T, Oram V, Holzman RS. Pyogenic liver abscess: recent trends in etiology and mortality. Clin Infect Dis 2004;39:1654–9.
5. Kaplan GG, Gregson DB, Laupland KB. Population-based study of the epidemiology of and the risk factors for pyogenic liver abscess. Clin Gastroenterol Hepatol 2004;2:1032–8.
6. Lederman ER, Crum NF. Pyogenic liver abscess with a focus on *Klebsiella pneumoniae* as a primary pathogen: an emerging disease with unique clinical characteristics. Am J Gastroenterol 2005;100:322–31.
7. Baden LR, Elliott DD. Case records of the Massachusetts General Hospital. Weekly Clinicopathological exercises. Case 4–2003. A 42-year-old woman with cough, fever, and abnormalities on thoracoabdominal computed tomography. N Engl J Med 2003;348:447–55.
8. Kim KW, Choi BI, Park SH, et al. Pyogenic hepatic abscesses: distinctive features from hypovascular hepatic malignancies on contrast-enhanced ultrasound with SH U 508A; early experience. Ultrasound Med Biol 2004; 30:725–33.
9. Lam YH, Wong SK, Lee DW, et al. ERCP and pyogenic liver abscess. Gastrointest Endosc 1999;50:340–4.
10. Johannsen EC, Sifri CD, Madoff LC. Pyogenic liver abscesses. Infect Dis Clin North Am 2000;14:547–63, vii.
11. Kurland JE, Brann OS. Pyogenic and amebic liver abscesses. Curr Gastroenterol Rep 2004;6:273–9.
12. Yu SC, Ho SS, Lau WY, et al. Treatment of pyogenic liver abscess: prospective randomized comparison of catheter drainage and needle aspiration. Hepatology 2004;39: 932–8.
13. Tan YM, Chung AY, Chow PK, et al. An appraisal of surgical and percutaneous drainage for pyogenic liver abscesses larger than 5 cm. Ann Surg 2005;241:485–90.
14. Wang W, Lee WJ, Wei PL, et al. Laparoscopic drainage of pyogenic liver abscesses. Surg Today 2004;34:323–5.
15. Sandford NL, Bradbear RA, Powell LW. Pyogenic liver abscess—a neglected diagnosis. Aust N Z J Med 1984; 14:597–9.

Copyright 2006 by Turner White Communications Inc., Wayne, PA. All rights reserved.