Clostridium perfringens: A Rare Cause of Infective Endocarditis and Aortic Root Abscess

Ramanna Merla, MD, MPH
Nischita K. Reddy, MD, MPH
Yochai Birnbaum, MD
Suimin Qiu, MD, PhD
Masood Ahmad, MD
Shaul Atar, MD

Endocarditis caused by anaerobes and microaerophilic bacteria accounts for 7% to 10% of all cases of infective endocarditis; however, if anaerobic streptococcal endocarditis is excluded, this number decreases to 1.3%.[1] Anaerobic organisms that can cause endocarditis include *Streptococcus*, *Bacteroides*, *Fusobacterium*, *Clostridium*, and *Propionibacterium* species.[1] Isolating *Clostridium* species with blood cultures can be difficult, and the majority of positive cultures are obtained postsurgically or postmortem from tissue specimens. Thus, physicians must maintain a high index of suspicion even if cultures are negative, utilize modalities such as transthoracic and transesophageal echocardiography to further delineate complications of endocarditis, and promptly initiate appropriate antibiotic treatment if anaerobic endocarditis is suspected. This article presents the case of a woman who, despite numerous negative aerobic and anaerobic blood cultures, was found to have infective endocarditis caused by *C. perfringens* after culture of aortic valve tissue obtained from emergent aortic root and valve replacement returned positive.

CASE PRESENTATION

Initial Presentation and History

A 48-year-old woman with idiopathic pulmonary arterial hypertension undergoing treatment with oral bosentan and warfarin and intravenous (IV) epoprostenol administered through a right internal jugular Hickman catheter presented to the emergency department with a 10-day history of progressive shortness of breath and diarrhea. Past medical history was unremarkable except for total abdominal hysterectomy for nonmalignant reasons 8 years ago.

Physical Examination

The patient was febrile (101.5°F) with a blood pressure of 109/51 mm Hg. On examination, a pronounced pulmonary component of the second heart sound and bibasilar crackles with rhonchi were noted. Rectal examination revealed brown guaiac-positive stool. No stigmata of endocarditis, such as Janeway's lesions, Osler's nodes, or Roth's spots, were noted. Laboratory testing revealed a white blood cell count of 12,100 cells/μL with a left shift, hemoglobin level of 9.4 g/dL, serum creatinine level of 2.29 mg/dL, fractional excretion of sodium of less than 1%, and an international normalized ratio of 9.7. Chest radiograph revealed interstitial edema with cardiomegaly. A ventilation-perfusion scan indicated a low probability of pulmonary embolism. A transthoracic echocardiogram (TTE) showed thickened aortic valve leaflets and moderate to severe aortic regurgitation. Stool samples were negative for *C. difficile* toxin, ova, parasites, and presence of leukocytes. Stool cultures were also negative. Urinalysis was unremarkable, and urine culture was negative. Warfarin was discontinued, and the patient was given IV hydration for prerenal azotemia. IV vancomycin, ceftriaxone, and gentamicin were initiated for suspected infective endocarditis.

Clinical Course

The following day, the patient remained febrile and

Drs. Merla and Reddy are residents in internal medicine, Department of Internal Medicine; Dr. Birnbaum is a professor of medicine, biochemistry, and molecular biology; Dr. Qiu is an assistant professor, Department of Pathology; Dr. Ahmad is a professor of medicine; and Dr. Atar is an associate professor of medicine; all are at the University of Texas Medical Branch at Galveston, Galveston, TX.

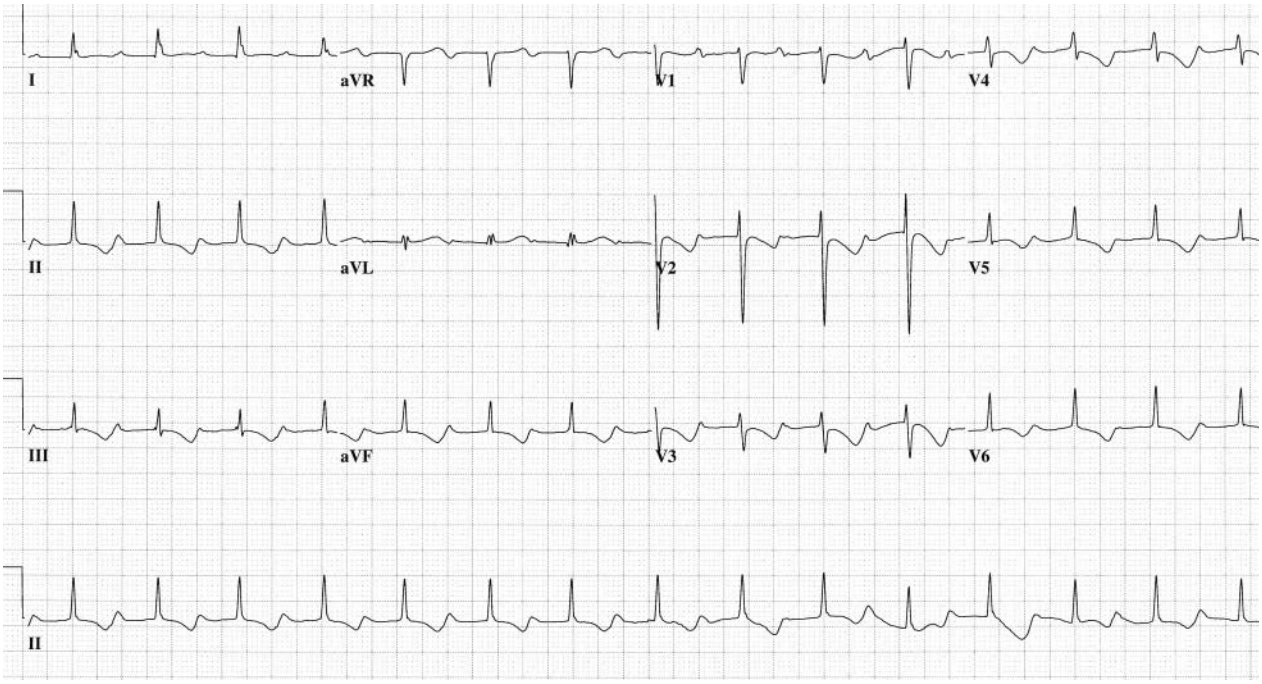

Figure 1. Electrocardiogram demonstrating first-degree atrioventricular block and T-wave inversion in the inferolateral leads.

developed acute hypoxia and hypotension, and her hemoglobin dropped to 7.9 g/dL. New holodiastolic and midsystolic ejection murmurs were heard over the aortic area. The patient was given noninvasive oxygen supplementation and aggressive fluid resuscitation, transfused with packed red blood cells, and placed on vasopressor therapy. She had no evidence of overt gastrointestinal bleeding. Schistocytes and polychromasia were seen on peripheral blood smear. Because aerobic and anaerobic blood cultures performed prior to the initiation of antibiotics and 3 sets performed later in the clinical course were negative, antibiotic coverage for culture-negative endocarditis was continued. Wide pulse pressures of 100–150/38–45 mm Hg and a first-degree atrioventricular block with T-wave inversion in the inferolateral leads developed (**Figure 1**). Cultures for slow-growing fastidious species such as *Hemophilus*, *Actinobacillus*, *Cardiobacterium*, *Eikenella*, and *Kingella* and serologic testing for *Brucella*, *Bartonella*, *Coxiella*, and *Legionella* species were negative.

A transesophageal echocardiogram (TEE) demonstrated a 3-leaflet aortic valve with detachment of the noncoronary cusp from the aortic wall (**Figure 2**). The cusp was protruding into the aortic outflow tract. Color Doppler interrogation revealed severe aortic regurgitation with a jet emerging behind the noncoronary cusp. The posterior wall of the ascending aorta immediately above the aortic annulus was echolucent. The finding of a detached aortic valve and severe aortic regurgitation raised the possibility of acute aortic dissection.

Emergent surgery revealed large vegetation and a perforated noncoronary cusp. An aortic root abscess that extended underneath the detached cusp was partially elevating the cusp from the aortic wall (Figure 2). Homograft aortic root replacement and coronary artery bypass grafting of a saphenous vein to the left anterior descending artery was performed. The patient's Hickman catheter was removed. A Gram stain of the aortic valve leaflet showed gram-positive coccobacillary organisms with inflammatory exudates (**Figure 3**). To cover for invasive nocardiosis, IV trimethoprim/sulfamethoxazole was started. Aerobic cultures from valvular tissue as well as from the Hickman catheter tip failed to show any growth; however, anaerobic cultures of valvular tissue grew *C. perfringens* (Figure 3C). The patient was treated with IV metronidazole and imipenem/cilastin for 5 weeks, and all other antibiotics were discontinued. TTE performed prior to discharge showed a left ventricular ejection fraction of 45% to 50%, with a normally functioning homograft aortic valve. The patient continued to do well 1 year postsurgery.

DISCUSSION

In all cases of suspected infective endocarditis, the initial assessment should include a thorough history

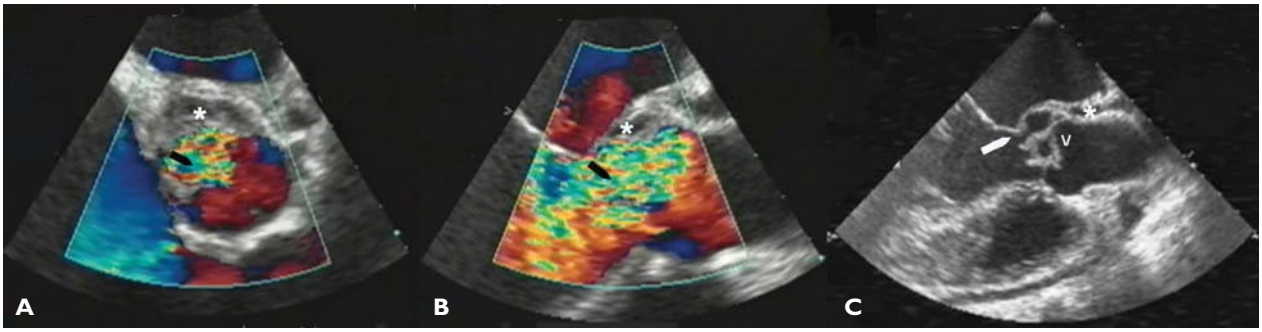

Figure 2. A transesophageal echocardiogram performed in the case patient, with (**A**) a short-axis view of the aortic valve showing a severe diastolic jet of aortic regurgitation (*arrow*) and a posteriorly located aortic root abscess (*asterisk*); (**B**) a long-axis view of the aortic root and left ventricular outflow, showing severe aortic regurgitation (*arrow*) with a portion of the aortic root abscess (*asterisk*) at the base of the noncoronary aortic cusp; and (**C**) a long-axis view of the aortic root and left ventricular outflow, showing an aortic root abscess (*asterisk*) and large vegetation (V) with perforation of the noncoronary cusp (*arrow*). The large abscess cavity partially elevates the noncoronary cusp from the underlying aortic wall.

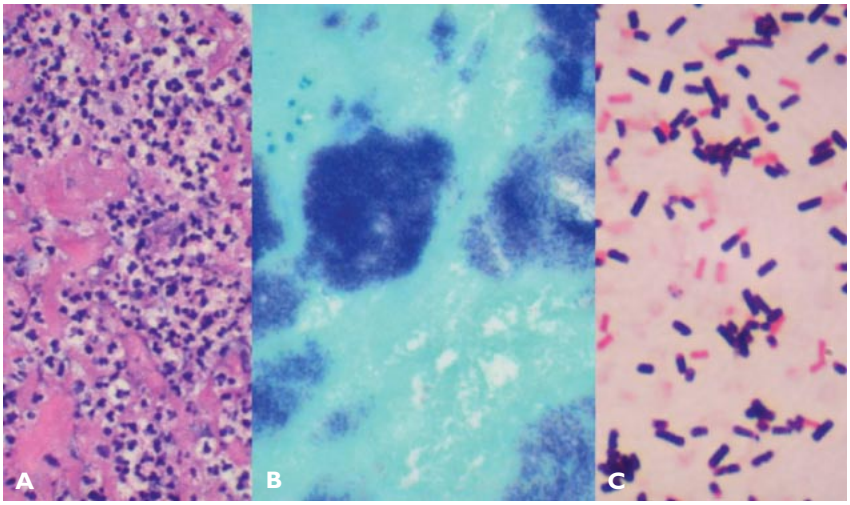

Figure 3. (**A**) Hematoxylin and eosin stain demonstrating distortion of the valvular architecture by inflammatory vegetations, which contain fibrinous exudates and platelets and collections of polymorphonuclear neutrophils. (**B**) Tissue Gram stain showing gram-positive bacterial colonies with inflammatory exudates on the surface of the infected valve. (**C**) Colony Gram stain showing *Clostridium perfringens*, which appears as gram-positive bacilli with heterogeneous incorporation of the stain into the spores.

and physical examination, including a history of prior cardiac lesions, a search for potential sources of bacteremia (eg, indwelling catheter, IV drug use), and a careful cardiac evaluation. Modified Duke criteria for diagnosis of infective endocarditis are outlined in **Table 1** and **Table 2**. The case patient met 2 major clinical criteria, specifically new-onset murmur and a finding of valvular vegetation on echocardiography. Additionally, infective endocarditis was confirmed by the positive histologic examination and culture of valvular tissue. In this case, we suspect that the indwelling Hickman catheter may have been the portal of entry of *C. perfringens*. The patient had possible signs of clostridial sepsis, including fever, shock (which required vasopressors for circulatory support), and schistocytes on peripheral blood smear (which may have indicated intravascular hemolysis). Gastrointestinal and urinary sources of infection were ruled out with cultures. This case underscores the importance of using TEE in the diagnosis of infective endocarditis, as it is superior to TTE for detecting valvular vegetations, valvular perforation, and perivalvular abscess.[2–4] Empiric treatment for culture-negative endocarditis was started and then tapered to metronidazole and imipenem/cilastin once *C. perfringens* was confirmed as the cause.

CULTURE-NEGATIVE ENDOCARDITIS

Culture-negative endocarditis constitutes less than 5% to 12% of all cases of endocarditis.[5,6] Factors influencing negative blood cultures include antibiotic administration prior to obtaining cultures, a slow-growing fastidious bacteria or fungi that has limited proliferation in conventional blood cultures, and the presence of right-sided endocarditis or permanent pacemakers.[5,7]

Table 1. Modified Duke Criteria for Diagnosis of Infective Endocarditis

Definite infective endocarditis

Pathologic criteria

(1) Microorganisms demonstrated by culture or histologic examination of a vegetation, a vegetation that has embolized, or an intracardiac abscess specimen; or

(2) Pathologic lesions; vegetation or intracardiac abscess confirmed by histologic examination showing active endocarditis

Clinical criteria*

(1) 2 major criteria; or

(2) 1 major criterion and 3 minor criteria; or

(3) 5 minor criteria

Possible infective endocarditis

(1) 1 major criterion and 1 minor criterion; or

(2) 3 minor criteria

Rejected

(1) Firm alternate diagnosis explaining evidence of infective endocarditis; or

(2) Resolution of infective endocarditis syndrome with antibiotic therapy for ≤ 4 days; or

(3) No pathologic evidence of infective endocarditis at surgery or autopsy with antibiotic therapy for ≤ 4 days; or

(4) Does not meet criteria for possible infective endocarditis, as above

Adapted with permission from Li JS, Sexton DJ, Mick N, et al. Proposed modifications to the Duke criteria for the diagnosis of infective endocarditis. Clin Infect Dis 2000;30:636. © 2000 The University of Chicago Press.

*See Table 2 for definitions of major and minor criteria.

In patients who meet modified Duke criteria for infective endocarditis but have negative blood cultures, it is imperative to evaluate for unusual organisms using a combination of serologic tests, specialized cultures, histopathology, and polymerase chain reaction.[5,6] Organisms identified with these additional tests in blood culture–negative infective endocarditis include *Coxiella burnetii*, *Bartonella* species, *Tropheryma whippelii*, *Abiotrophia elegans*, *Mycoplasma hominis*, *L. pneumophila*, *S. bovis*, *Rhodococcus* species, and *Histoplasma* species.[5,6] With the use of these methods, effective cases of culture-negative endocarditis can be decreased to 1%.[5]

Clostridial Endocarditis

C. perfringens is a rare cause of infective endocarditis. Only 21 cases of clostridial endocarditis have been reported in the literature, predominantly caused by *C. perfringens*.[8–10] Likely portals of entry include the skin, oropharynx, and gastrointestinal and genitourinary

Table 2. Definitions of Major and Minor Criteria in the Modified Duke Criteria for Diagnosis of Infective Endocarditis (IE)

Major criteria

Blood culture positive for IE

Typical microorganisms consistent with IE from 2 separate blood cultures:

Viridans streptococci, *Streptococcus bovis*, HACEK group, *Staphylococcus aureus*; or

Community-acquired enterococci, in the absence of a primary focus; or

Microorganisms consistent with IE from persistently positive blood cultures, defined as follows:

At least 2 positive cultures of blood samples drawn > 12 h apart; or

All of 3 or a majority of ≥ 4 separate cultures of blood (with first and last sample drawn at least 1 h apart)

Single positive blood culture for *Coxiella burnetii* or antiphase I IgG antibody titer > 1:800

Evidence of endocardial involvement

Echocardiogram positive for IE (TEE recommended in patients with prosthetic valves, rating of at least "possible IE" by clinical criteria, or complicated IE [paravalvular abscess]; TTE is first test in other patients), defined as follows:

Oscillating intracardiac mass on valve or supporting structures, in the path of regurgitant jets, or on implanted material in the absence of an alternative anatomic explanation; or

Abscess; or

New partial dehiscence of prosthetic valve

New valvular regurgitation (worsening or changing of preexisting murmur not sufficient)

Minor criteria

Predisposition, predisposing heart condition, or injection drug use

Fever, temperature > 38°C (100.4°F)

Vascular phenomena, major arterial emboli, septic pulmonary infarcts, mycotic aneurysm, intracranial hemorrhage, conjunctival hemorrhages, and Janeway's lesions

Immunologic phenomena: glomerulonephritis, Osler's nodes, Roth's spots, and rheumatoid factor

Microbiologic evidence: positive blood culture but does not meet a major criterion as noted above* or serologic evidence of active infection with organism consistent with IE

Echocardiographic minor criteria eliminated

Adapted with permission from Li JS, Sexton DJ, Mick N, et al. Proposed modifications to the Duke criteria for the diagnosis of infective endocarditis. Clin Infect Dis 2000;30:637. © 2000 The University of Chicago Press.

HACEK = *Haemophilus parainfluenzae, H. influenzae*, *H. aphrophilus*, *H. paraphrophilus*, *Actinobacillus actinomycetemcomitans*, *Cardiobacterium hominis*, *Eikenella corrodens*, and *Kingella* species; TEE = transesophageal echocardiography; TTE = transthoracic echocardiography.

*Excludes single positive cultures for coagulase-negative staphylococci and organisms that do not cause endocarditis.

systems.[11] Although some studies have found no predisposing factors for the development of infective endocarditis,[8] patients with IV drug use,[12] carcinoma of the colon or cervix, and preexisting valvular disease, including those with prosthetic valves and rheumatic heart disease, may be at increased risk.[11] Valvular disease is present in approximately 50% of patients with clostridial endocarditis.[9,11] Nkoua et al[13] isolated *C. perfringens* from a patient with postpartum infective endocarditis and a patient with illicit postabortive infective endocarditis. Clostridial endocarditis has also been reported after penetrating cardiac trauma.[14]

Diagnosis of clostridial endocarditis is similar to that of endocarditis caused by other organisms and involves demonstration of a valvular lesion on echocardiography. Fever is a presenting symptom in the majority of patients with infective endocarditis, and embolic phenomena occur in approximately 50% of cases.[11] A spectrum of shock, intravascular hemolysis, and jaundice (known as "clostridial sepsis") has been observed in one third of patients with clostridial endocarditis.[11]

Clostridia are not frequently isolated from blood cultures. Use of aerobic and anaerobic culture methods may increase the yield of detection of clostridial or culture-negative endocarditis.[15] Clostridia have been predominantly cultured from endovascular tissue specimens obtained either postsurgically or at autopsy.

Anaerobic endocarditis appears to cause large vegetations, as was the case in our patient. In 14 cases with a well-documented clinical history, 4 involved prosthetic valves, while others involved the tricuspid valve, the aortic and mitral valves, the aortic wall at the junction with Dacron prosthesis, and the left ventricular wall below the mitral annulus.[15]

Empiric treatment for culture-negative endocarditis includes vancomycin, fluoroquinolone/ceftriaxone, and gentamicin.[1,16] IV penicillin G is the treatment of choice for clostridial endocarditis, but metronidazole has been considered for prolonged bacteremia or in treatment failures. Mortality rates have been reported to be as high as 47% despite appropriate antibiotic treatment.[10]

SUMMARY

It is imperative to perform blood cultures prior to the initiation of antibiotics in patients with suspected endocarditis. When blood cultures are negative and the probability of infective endocarditis is still high, specialized cultures, serologic testing, polymerase chain reaction, and tissue histopathology and culture can be performed to identify a causative organism, which subsequently allows for targeted antibiotic therapy. Despite a sound diagnostic approach and numerous cultures to identify the causative organism, in some cases the organism cannot be isolated and broad-spectrum antibiotic coverage then becomes important. **HP**

Corresponding author: Yochai Birnbaum, MD, Division of Cardiology, The University of Texas Medical Branch, 5.106 John Sealy Annex, 301 University Boulevard, Galveston, TX 77555-0553; e-mail: yobirnba@utmb.edu.

REFERENCES

1. Fowler VG, Scheld MW, Bayer AS. Endocarditis and intravascular infections. In: Mandell GL, Douglas RG, Bennett JE, Dolin R, editors. Mandell, Douglas, and Bennett's principles and practice of infectious diseases. 6th ed. New York: Elsevier/Churchill Livingstone; 2005:975–1022.
2. Shapiro SM, Young E, De Guzman S, et al. Transesophageal echocardiography in diagnosis of infective endocarditis. Chest 1994;105:377–82.
3. Schulz R, Werner GS, Fuchs JB, et al. Clinical outcome and echocardiographic findings of native and prosthetic valve endocarditis in the 1990's. Eur Heart J 1996;17:281–8.
4. Daniel WG, Mügge A, Martin RP, et al. Improvement in the diagnosis of abscesses associated with endocarditis by transesophageal echocardiography. N Engl J Med 1991;324:795–800.
5. Houpikian P, Raoult D. Blood culture–negative endocarditis in a reference center: etiologic diagnosis of 348 cases. Medicine (Baltimore) 2005;84: 162–73.
6. Lamas CC, Eykyn SJ. Blood culture negative endocarditis: analysis of 63 cases presenting over 25 years. Heart 2003;89:258–62.
7. Naber CK, Erbel R. Diagnosis of culture negative endocarditis: novel strategies to prove the suspect guilty. Heart 2003;89:241–3.
8. Kolander SA, Cosgrove EM, Molavi A. Clostridial endocarditis. Report of a case caused by *Clostridium bifermentans* and review of the literature. Arch Intern Med 1989;149:455–6.
9. Alvarez-Elcoro S, Sifuentes-Osorio J. *Clostridium perfringens* bacteremia in prosthetic valve endocarditis. Diagnosis by peripheral blood smear. Arch Intern Med 1984;144:849–50.
10. Cutrona AF, Waranakunakorn C, Schaub C, Jagetia A. *Clostridium innocuum* endocarditis. Clin Infect Dis 1995;21:1306–7.
11. Brouqui P, Raoult D. Endocarditis due to rare and fastidious bacteria. Clin Microbiol Rev 2001;14:177–207.
12. Moyano R, Gomez-Mateos JM, Lozano de Leon F, et al. *Clostridium bifermentans*: an exceptional agent of endocarditis [letter]. Clin Infect Dis 1994; 18:837.
13. Nkoua JL, Kimbally-Kaky G, Ekoba J, et al. [Infectious endocarditis of gyneco-obstetric origin. Apropos of 15 cases.] [Article in French.] J Gynecol Obstet Biol Reprod (Paris) 1993;22:425–8.
14. Holland F 2nd, Fernandez L, Jacobs J, Bolooki H. Clostridial endocarditis following penetrating cardiac trauma. Clin Infect Dis 1997;24:87–9.
15. Durmaz B, Agel HE, Sonmez E, et al. Infective endocarditis due to *Clostridium histolyticum* [letter]. Clin Microbiol Infect 2000;6:561–3.
16. Baddour LM, Wilson WR, Bayer AS, et al; Committee on Rheumatic Fever, Endocarditis, and Kawasaki Disease; Council on Cardiovascular Disease in the Young; Councils on Clinical Cardiology, Stroke, and Cardiovascular Surgery and Anesthesia; American Heart Association; Infection Diseases Society of America. Infective endocarditis: diagnosis, antimicrobial therapy, and management of complications: a statement for healthcare professionals from the Committee on Rheumatic Fever, Endocarditis, and Kawasaki Disease, Council on Cardiovascular Disease in the Young, and the Councils on Clinical Cardiology, Stroke, and Cardiovascular Surgery and Anesthesia, American Heart Association: endorsed by the Infectious Diseases Society of America [published errata appear in Circulation 2005;112:2373 and 2007;115:e408]. Circulation 2005;111:e394–434.

Copyright 2008 by Turner White Communications Inc., Wayne, PA. All rights reserved.