Pediatric Trauma: Review Questions

Brett R. Levine, MD, MS

QUESTIONS

Choose the single best answer for each question.

Questions 1 and 2 refer to the following case.

A 13-year-old boy presents to the emergency department with left ankle pain after a fall that occurred while he was playing football. After the injury, he was unable to bear weight and ambulate on the left ankle. Physical examination reveals significant edema around the ankle and tenderness to palpation medially and laterally. Motor and sensory function is intact distally, and there are no abrasions or wounds to the skin. Plain radiographs and a computed tomography (CT) scan of the left ankle are obtained (**Figure 1**).

1. What is this patient's diagnosis?

(A) Maisonneuve fracture
(B) Salter-Harris type V fracture of the distal tibia
(C) Thurston-Holland fracture
(D) Tillaux fracture
(E) Triplane fracture

2. How should this patient be treated?

(A) Closed reduction and long leg cast
(B) Closed reduction and short leg cast
(C) Open reduction and internal fixation with a distal tibial locking plate
(D) Open reduction and screw fixation
(E) Placement of an external fixator

3. A 7-year-old girl presents with a left wrist injury after a fall onto an outstretched hand. She undergoes closed reduction and splinting in the emergency department. At follow-up 2 weeks later, radiographs are obtained (Figure 2). Based on results of radiography, definitive management should now include which of the following?

(A) Accept the current reduction and convert to a long arm cast
(B) Assess distal-radial-ulnar joint stability and re-splint in supination
(C) Closed reduction and intramedullary fixation
(D) Open reduction and internal fixation using a distal radius locking plate
(E) Repeat closed reduction and splinting

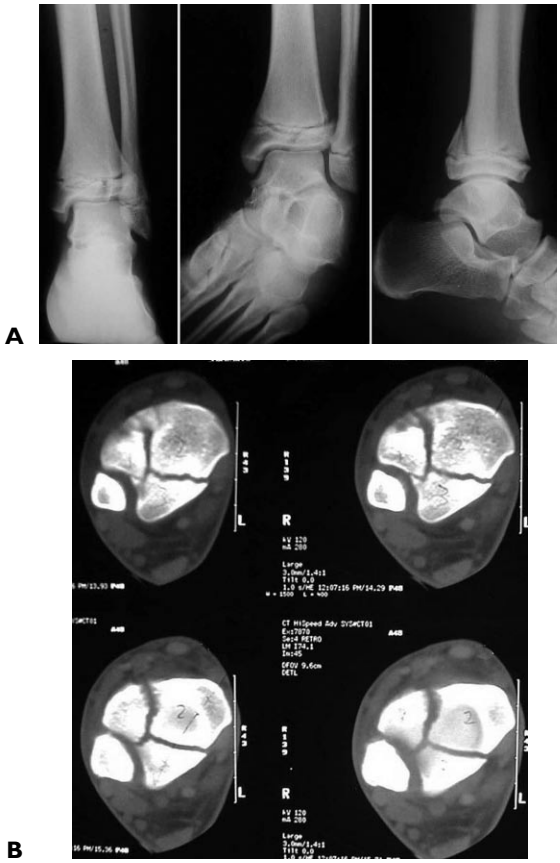

Figure 1. (**A**) Radiograph and (**B**) computed tomography scans of the left ankle of the patient described in questions 1 and 2.

Questions 4 and 5 refer to the following case.

A 6-year-old boy complains of right elbow pain after a fall from a trampoline onto his outstretched upper extremity. The patient has a gross deformity of the right elbow but is able to move his fingers without difficulty or limitation. Capillary refill to the fingers is less than 2 seconds, and the right hand is warm and supple. The radial artery pulse is difficult to palpate, and there are no open wounds associated with the injury. Anteroposterior and lateral radiographs are obtained (**Figure 3**).

Dr. Levine is an assistant professor, Rush University Medical Center, Chicago, IL.

Figure 2. (**A**) Anteroposterior and (**B**) lateral radiographs of the left wrist of the patient described in question 3.

4. **How should this patient's fracture be treated?**
   (A) Closed reduction and casting
   (B) Closed reduction and lateral percutaneous pinning of the olecranon
   (C) Closed reduction and lateral pinning of the distal humerus
   (D) Closed reduction and screw fixation of the distal humerus
   (E) Open reduction and plating of the distal humerus

5. **What is the most common complication associated with this type of fracture?**
   (A) Chronic pain
   (B) Cubitus varus
   (C) Elbow stiffness
   (D) Posttraumatic arthritis
   (E) Radial nerve palsy

6. **A 7-year-old boy sustains a transverse mid-shaft femur fracture after a high-speed motor vehicle collision and undergoes operative management using flexible intramedullary nails without complication. Compared with casting with or without traction, which of the following is associated with the use of flexible nails?**
   (A) Higher rate of fracture malunion
   (B) Higher rate of fracture nonunion
   (C) Increased risk of leg length discrepancy
   (D) Increased risk of osteonecrosis of the femoral head
   (E) Lower rate of fracture malunion

Figure 3. (**A**) Anteroposterior and (**B**) lateral radiographs of the right elbow of the patient described in questions 4 and 5.

7. **A 10-year-old boy is brought to the ED after a skateboarding injury and diagnosed with a closed mid-shaft tibia fracture. The patient receives conscious sedation and closed reduction and casting are performed. What is the acceptable alignment for this patient's fracture?**
   (A) 0 degrees of varus, 3 degrees of sagittal deformity, and 2 cm of shortening
   (B) 0 degrees of varus, 10 degrees of sagittal deformity, and 1 cm of shortening
   (C) 5 degrees of valgus, 3 degrees of sagittal deformity, and 1 cm of shortening
   (D) 5 degrees of valgus, 10 degrees of sagittal deformity and 0 cm of shortening
   (E) 10 degrees of varus, 3 degrees sagittal deformity, and 2 cm of shortening

ANSWERS AND EXPLANATIONS

1. **(E) Triplane fracture.** This patient's ankle fracture is a translational injury, which typically occurs during the 18 months in which the distal tibial physis undergoes asymmetric closure.[1] Triplane fractures often present in children aged 12 to 15 years, with a slightly higher incidence in males than females. There are multiple variations of the triplane fracture, and they represent 5% to 10% of pediatric intra-articular ankle injuries.[1] Closure of the distal tibial physis occurs in an asymmetric pattern, starting centrally, then anteromedially, and then posteromedially; the lateral portion of the physeal plate is the final area of closure. Figure 1 shows a 3-part triplane ankle fracture, best described as a Salter-Harris type III fracture on the anteroposterior radiograph and a Salter-Harris type II fracture on the lateral radiograph (with a metaphyseal spike posteriorly). Axial CT images clearly demonstrate 3 fracture fragments. A Thurston-Holland fracture is not a type of

ankle fracture but rather a description of a coronal plane fracture fragment. A Salter-Harris type V injury is a crush injury to the growth plate, often diagnosed when a leg length discrepancy or growth disturbance is found several years after the injury is sustained.[2] Tillaux fractures involve the anterolateral aspect of the distal tibia and are found in children slightly older than those who experience triplane fractures. A Tillaux fracture is indicative of an avulsion of the anterior inferior tibiofibular ligament during the time of asymmetric closure of the distal tibial physis.[2] Maisonneuve fractures are injuries to the syndesmosis, typically associated with a high fibula fracture and asymmetry of the medial ankle mortise.

2. **(D) Open reduction and screw fixation.** Preoperative CT scans are useful in planning surgical management of triplane fractures. Fractures with gapping or articular displacement of more than 2 mm require operative fixation.[1] In this case, closed reduction and casting is inadequate based on the extent of fracture displacement. The use of locking plates in osteosynthesis of a triplane fracture may result in growth disturbance and requires more hardware than necessary for stable fixation. Placement of an external fixator would not allow for anatomic reduction of the articular surface and is not recommended. Surgical reduction is performed via an anterolateral or anteromedial approach depending on the fracture fragment orientation. The typical order of treatment for triplane fractures is: (1) address the anterolateral fracture, (2) reduce the posteromedial fracture with dorsiflexion and inversion of the foot, (3) reduce and fix the fibula if a fracture is present, and (4) secure the anterolateral fragment. Initially reducing the posteromedial fragment is thought to be crucial to fixation of triplane fractures. Regardless of the pattern of reduction, anatomic alignment of the articular surface is essential to the long-term success of treatment, and screws are sufficient for rigid internal fixation of fracture fragments.

3. **(A) Accept the current reduction and convert to a long arm cast.** Fractures of the distal radius typically occur after a fall onto an outstretched hand, resulting in apex-volar angulation of the fracture. Anatomic reduction is not always necessary for pediatric fractures due to the significant potential for remodeling as bones continue to grow. This remodeling potential is accentuated in distal fractures and in children younger than age 10 years.[3] Distal radius locking plates are not used to fix pediatric fractures, as they may lead to premature closure of the distal radius physis. Similarly, intramedullary fixation of distal radius fractures is not commonly used because it is difficult to maintain good fracture stability and may also lead to early physeal closure. Repeat closed reduction to improve fracture alignment would be difficult at this point after the injury. The fracture pattern as seen in Figure 2 typically does not affect the distal-radial-ulnar joint in pediatric patients and resplinting in supination is not necessary. In patients younger than 9 years, complete displacement (bayonet apposition), 15 degrees of angulation, and 45 degrees of malrotation are acceptable (fracture position in Figure 2 is within these limits), and casting for 4 to 6 weeks remains the best option.[3]

4. **(C) Closed reduction and lateral pinning of the distal humerus.** This patient has a type III (completely displaced) fracture of the supracondylar humerus. Supracondylar humerus fractures represent 50% to 70% of elbow fractures in children, commonly occurring between age 3 and 10 years.[4] The mechanism of injury is a fall onto an outstretched hand, often during sporting activities and falls from playground equipment, resulting in an extension-type injury (95%).[4] Because the olecranon is not fractured in this case, closed reduction and lateral percutaneous pinning of the olecranon is not appropriate. Open reduction and plating of the distal humerus is incorrect because plating is more extensive than what is necessary to stabilize the fracture. Violation of multiple growth plates around the distal humerus and early physeal closure will likely occur with plate and screw fixation of a pediatric elbow fracture. Closed reduction and casting is not sufficient for treating this unstable fracture pattern. Without secure fixation, type III supracondylar humerus fractures will displace, as anatomic alignment is difficult to achieve and maintain in a cast. Closed reduction with percutaneous fixation using smooth pins, not screws, is the most appropriate treatment to decrease the risk of premature physeal closure and growth disturbance.[4] Two lateral pins placed divergently have been shown to provide adequate fracture stability for healing with relatively minimal neurovascular risk.[4]

5. **(B) Cubitus varus.** Radial nerve palsy, elbow stiffness, posttraumatic osteoarthritis of the elbow, and chronic pain are rare complications of supracondylar humerus fractures. Cubitus varus (gunstock deformity) is the most common form of malunion after a displaced supracondylar humerus fracture.[4] The deformity is indicative of a rotational malposition of the fracture and

is primarily cosmetic in nature with minimal associated functional deficits.[4] Unlike many other pediatric fractures, the distal humerus harbors very little remodeling potential. Therefore, accurate reduction at the time of fixation is crucial to preventing malunion.

6. **(E) Lower rate of fracture malunion.** Treatment of femoral shaft fractures in children aged older than 6 years remains a controversial topic. A systematic review of 2422 femoral shaft fractures found a significantly lower number of malunions, leg length discrepancies, and total adverse events with intramedullary fixation as compared with casting and external fixation.[5] Flexible nails are typically used in patients with open proximal femoral growth plates and mid-shaft femur fractures with minimal comminution. Use of flexible nails allows for early mobilization, and thus patients can meet recovery milestones earlier.[6] Higher rates of fracture malunion or nonunion and increased risk of leg length discrepancy are all linked to casting and nonoperative treatment of pediatric femoral shaft fractures. Osteonecrosis of the femoral head is not associated with flexible nailing of femoral shaft fractures but has been found in conjunction with antegrade femoral nails with piriformis entry in children.

7. **(C) 5 degrees of valgus, 3 degrees of sagittal deformity, and 1 cm of shortening.** Tibial shaft fractures are common pediatric injuries, and treatment is individualized based on patient age, concomitant injuries, fracture pattern, and surgeon preference. Fracture healing usually occurs within 10 weeks of injury, and nonunion occurs in less than 2% of patients.[7] Closed reduction and casting is the most common mode of treatment for stable pediatric tibial shaft fractures. Typically, a long leg cast is used for 4 to 6 weeks, followed by a short leg cast for another 4 to 6 weeks. Acceptable alignment for closed reduction is up to 5 degrees of varus/valgus angulation, less than 5 degrees of sagittal plane deformity, and up to 1 cm of shortening. Up to 50% translation is acceptable in adolescents and older children.[7]

REFERENCES

1. Schnetzler KA, Hoernschemeyer D. The pediatric triplane ankle fracture. J Am Acad Orthop Surg 2007;15:738–47.
2. Kay RM, Matthys GA. Pediatric ankle fractures: evaluation and treatment. J Am Acad Orthop Surg 2001;9:268–78.
3. Noonan KJ, Price CT. Forearm and distal radius fractures in children. J Am Acad Orthop Surg 1998;6:146–56.
4. Shrader MW. Pediatric supracondylar fractures and pediatric physeal elbow fractures. Orthop Clin North Am 2008;39:163–71, v.
5. Poolman RW, Kocher MS, Bhandari M. Pediatric femoral fractures: a systematic review of 2422 cases. J Orthop Trauma 2006;20:648–54.
6. Flynn JM, Schwend RM. Management of pediatric femoral shaft fractures. J Am Acad Orthop Surg 2004;12:347–59.
7. Mashru RP, Herman MJ, Pizzutillo PD. Tibial shaft fractures in children and adolescents. J Am Acad Orthop Surg 2005;13:345–52.

Copyright 2009 by Turner White Communications Inc., Wayne, PA. All rights reserved.