Series Editor: Mark A. Perazella, MD

Cerebral Toxoplasmosis in Adult Patients with HIV Infection

Suriya Jayawardena, MD
Shantnu Singh, MD
Olga Burzyantseva, MD
Hillary Clarke, MD

A 38-year-old woman presented to the emergency department with headache, a 5-day history of dizziness, and a 2- to 3-day history of nausea/vomiting. The patient denied fever, photophobia, and neck stiffness. Past medical history was significant for HIV infection diagnosed 7 years ago and AIDS onset 6 years ago with an episode of *Pneumocystis jiroveci* pneumonia. Baseline IgG and IgM levels for *Toxoplasma gondii* were 19.2 mg/dL and 0.25 mg/dL, respectively. The patient was noncompliant with both her antiretroviral regimen and prophylaxis regimen for *P. jiroveci* and *T. gondii* infections. On examination, the patient was febrile, alert, awake, and oriented. There were no signs of meningeal irritation. Examination of the fundus revealed bilateral papilledema. The remainder of the examination was normal. Complete blood count and serum electrolytes were normal. CD4+ count was 15 cells/μL, and the most recent viral load was approximately 300,000 copies/mL.

Computed tomography (CT) of the head without contrast showed a space-occupying lesion in the bilateral temporoparietal regions. CT of the head with contrast subsequently showed bilateral temporoparietal brain masses. Magnetic resonance imaging (MRI) of the brain with contrast demonstrated ring-enhancing lesions with adjacent edema in the bilateral temporoparietal regions (**Figure 1**). Laboratory testing revealed serum antitoxoplasma IgG and IgM antibody levels of 162.3 mg/dL and 0.3 mg/dL, respectively. Based on laboratory results and imaging studies, a presumptive diagnosis of cerebral toxoplasmosis due to reactivation of previous infection was made.

The patient received a 200-mg loading dose of pyrimethamine and was placed on a regimen containing pyrimethamine (75 mg/day), sulfadiazine (1500 mg 4 times daily), and leucovorin (10 mg/day). On day 2 of treatment, the patient's symptoms began to improve. After 5 days, she was completely asymptomatic and was discharged. Treatment was continued for 6 weeks, and the patient was subsequently prescribed pyrimethamine 50 mg/day, sulfadiazine 2 g/day, and leucovorin 10 mg/day orally for secondary prophylaxis against *Toxoplasma*. The patient was restarted on her antiretroviral regimen 2 weeks after discharge. Repeat MRI of the brain with contrast 1 month after the diagnosis showed that the lesion in the left temporoparietal lobe had resolved completely, while the lesion on the right side had decreased in size (**Figure 2**).

Toxoplasma gondii is an obligatory intracellular pathogen that infects a large proportion of the world population and is a well-recognized cause of illness among persons with AIDS.[1] *T. gondii* infection typically is latent and remains asymptomatic in both immunocompetent individuals and HIV-infected patients. However, patients with HIV are at risk for developing acute toxoplasmosis due to reactivation of the organism if their CD4+ T-cell count decreases below 100 cells/μL or if this level decreases below 200 cells/μL in the presence of concomitant opportunistic infection or malignancy.[1,2] Reactivation of latent *T. gondii* infection in patients with AIDS typically manifests as cerebral toxoplasmosis,[3] which can be life-threatening if not diagnosed and treated expeditiously. This article discusses the epidemiology, pathogenesis, diagnosis, and management of cerebral toxoplasmosis in adult patients with HIV infection.

EPIDEMIOLOGY

T. gondii infection has a worldwide distribution. In

Dr. Jayawardena is a cardiology fellow, Drs. Singh and Burzyantseva are residents, and Dr. Clarke is an attending neurology physician; all are at Coney Island Hospital, Brooklyn, NY.

TAKE HOME POINTS

- Empiric therapy for cerebral toxoplasmosis should be considered in all HIV-infected patients with ring-enhancing lesions found on magnetic resonance imaging and/or computed tomography.
- In most cases, negative serology for antitoxoplasma IgG antibodies should prompt the physician to consider diagnoses other than toxoplasmosis in HIV-infected patients. However, negative serology does not conclusively rule out acute toxoplasmosis.
- Most HIV-infected patients treated empirically for acute toxoplasmosis infection show clinical improvement within 2 weeks.
- In HIV-infected patients showing deterioration by the third day of empiric treatment for cerebral toxoplasmosis, an alternative diagnosis of lymphoma should be considered.
- All patients who are diagnosed with HIV infection should be screened for antitoxoplasma IgG antibodies to determine their risk for developing acute toxoplasmosis.
- Patient education should focus on preventing infection and medical prophylaxis. At-risk seropositive patients should receive primary or secondary prophylaxis, as appropriate.

the United States, 15% to 29.2% of the general population are seropositive for *T. gondii* infection, while seroprevalence rates in Europe and tropical countries can reach 90%.[4] In the United States, the prevalence of latent *T. gondii* infection among persons with HIV infection does not differ from that in the general population.[5] With the widespread use of highly active antiretroviral therapy (HAART), the incidence of central nervous system (CNS) toxoplasmosis has decreased.[6] In particular, the incidence of toxoplasmic encephalitis decreased from 3.9 cases per 100 person-years in the pre-HAART era to 1 case per 100 person-years following the introduction of HAART.[7] An estimated 10% to 20% of HIV-infected patients in the United States ultimately will develop toxoplasmic encephalitis.[8] In 1 study, the risk for developing acute toxoplasmosis among HIV-infected adults was 18% in those who were compliant with prophylaxis versus 30% in those who were not compliant.[9] In general, toxoplasmic encephalitis is a poor indicator of prognosis in AIDS patients, with 1 study attributing 23% of deaths in AIDS patients to this entity.[10]

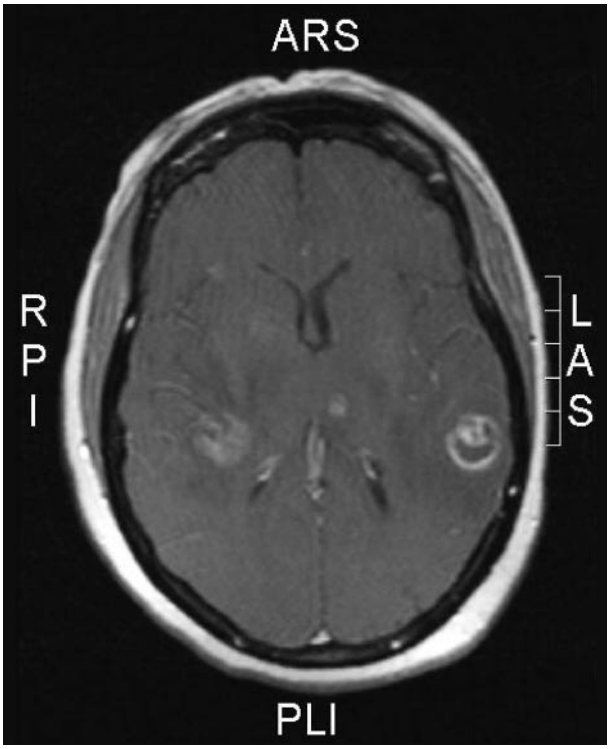

Figure 1. Magnetic resonance imaging of the brain showing ring-enhancing lesions with surrounding edema in the bilateral temporo-parietal lobes.

PATHOGENESIS

Toxoplasmosis is a zoonotic disease caused by the obligate intracellular protozoa *T. gondii*. Infection in humans usually occurs via the oral or transplacental route. Consumption of raw or undercooked meat containing viable cysts, water contaminated with oocysts from cat feces, and unwashed vegetables are the primary routes of oral transmission; improper handling of undercooked meat or contaminated soil also may lead to hand-to-mouth infection.[11] Transplacental infection with *T. gondii* is more likely to occur in HIV-infected women who are acutely infected with *T. gondii* during pregnancy compared with those with latent infection. In women with latent infection, there is an estimated 4% risk for transmission of the infection to the fetus.[12] The rate of congenital infection in women with acute infection ranges from 20% to 50% depending on which trimester the acute infection occurs in.[13] The outcome is more severe if the infection occurs early in the pregnancy, with first trimester infections causing spontaneous abortions or serious birth defects. Congenital toxoplasmosis is suggested by the classic triad of hydrocephalus, intracranial calcifications, and chorioretinitis, but the triad is not specific and is rare.[14]

Humans are the intermediate hosts for *T. gondii*, whereas cats are the definitive hosts. Infected cats spread disease when oocytes pass in their feces. When ingested by humans, these oocytes become tachyzoites, which undergo rapid replication. These tachyzoites penetrate nucleated cells and form vacuoles. When these cells die, tachyzoites continue to spread throughout the body and infect other tissue as well as cause an inflammatory response.[15] In the immunocompetent host, cell-mediated immunity controls the acute *Toxoplasma* infection as well as prevents disease reactivation.[16,17] The presence of tachyzoites in the blood activates CD4+ T cells to express CD154 (also called CD40 ligand). In turn, CD154 triggers dendritic cells and macrophages to secrete interleukin (IL)-12, which activates T-cell production of interferon gamma (IFN-γ).[17,18] IFN-γ stimulates macrophages and other nonphagocytic cells for an antitoxoplasmic response. Tumor necrosis factor-α (TNF-α) also has been shown to play an important role in controlling *T. gondii* by developing a strong T-cell response against this infection.[19] In response, the tachyzoites transform into bradyzoites, which are morphologically similar to tachyzoites but replicate more slowly. The bradyzoites form cysts that are retained in the brain, heart, and skeletal muscle of the host for the rest of their life. The result is a chronic phase infection characterized by tissue cysts. If the host becomes immunocompromised, these cysts can transform back into tachyzoites to infect other tissues in the host.[20,21]

In HIV-infected patients, expression of CD154 in response to *Toxoplasma* is impaired in CD4+ T cells.[22] This impairment correlates with the decreased production of IL-12 and IFN-γ in response to *T. gondii* in HIV-infected patients.[22] The cytotoxic T-lymphocyte activity is also impaired, thus decreasing the host defense against *T. gondii*.[23] Decreased host defense leads to reactivation of chronic *Toxoplasma* infection in HIV-infected patients, especially when the CD4+ count decreases below 100 cells/μL.

CLINICAL PRESENTATION

Typically, toxoplasmosis in HIV-infected patients occurs due to reactivation of chronic infection, and it usually presents as toxoplasmic encephalitis.[3] In AIDS patients, *T. gondii* is the most common opportunistic infection that causes focal brain lesions.[9] The initial presentation of toxoplasmic encephalitis in patients with AIDS may be subacute. Patients present with altered mental status (62%), headaches (59%), and fever (41%) associated with focal neurologic deficits.[2,24–26] Progression of the infection can lead to confusion, drowsiness, seizures, hemiparesis, hemianopsia, aphasia, ataxia, and cranial nerve palsies. Motor weakness and speech disturbance are seen as the disease progresses. If not treated promptly, patients may progress to coma within days to weeks.[9] Toxoplasmosis may rarely present as a rapidly fatal form of diffuse or global encephalitis with profound mental status changes, nausea, and vomiting, usually indicating elevated intracranial pressure.[25]

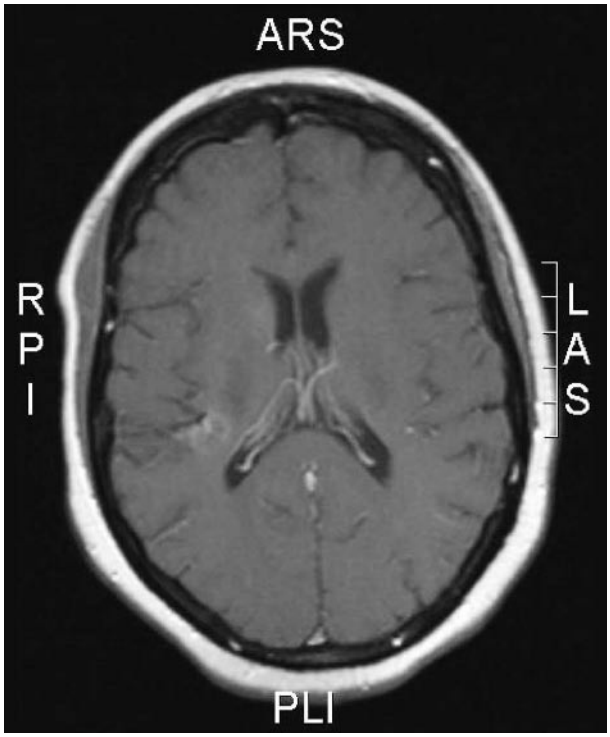

Figure 2. Magnetic resonance imaging of the brain demonstrating resolution of the edema and ring-enhancing lesion in the left temporoparietal region and a decrease in the size of the ring-enhancing lesion in the right temporoparietal lobe after 4 weeks of treatment.

The eyes and lungs are the most common sites of extracerebral manifestation of toxoplasmosis, and such manifestations may occur with or without concomitant encephalitis. Extracerebral manifestations occur less frequently than cerebral toxoplasmosis.[12] Toxoplasmic chorioretinitis (posterior uveitis) presents with eye pain and decreased visual acuity. It is indistinguishable from other ocular infections in HIV (especially cytomegalovirus retinitis) and rarely mimics acute retinal necrosis.[27] *Toxoplasma* pneumonitis presents with fever, dyspnea, and nonproductive cough. Chest radiograph typically shows reticulonodular infiltrates. The clinical picture may be indistinguishable from *Pneumocystis jiroveci* pneumonitis.[12] Other manifestations are rare, including involvement of the gastrointestinal tract, liver, musculoskeletal system, heart, bone marrow, bladder,

spinal cord, and testes.[12] Extracerebral toxoplasmosis is treated in the same manner as cerebral toxoplasmosis.

DIAGNOSTIC STUDIES

Serology assays, imaging, tissue biopsy, and polymerase chain reaction (PCR) assays are among the available modalities that can be used to diagnose toxoplasmosis. In patients with suspected toxoplasmosis, serology and imaging studies (either computed tomography [CT] or magnetic resonance imaging [MRI]) are typically used to make the diagnosis. Empiric therapy for cerebral toxoplasmosis should be considered for HIV-infected patients with ring-enhancing lesions on MRI or CT. Biopsy is reserved for uncertain diagnoses or for patients who fail empiric therapy. Other diagnostic modalities have a limited role.[28]

Serology

T. gondii infection is commonly detected by performing serologic studies for antitoxoplasma antibodies. The serum IgG antitoxoplasma titer peaks between 1 and 2 months after primary infection and typically remains detectable for the rest of the patient's life. In general, serum assays should not be used as the sole diagnostic study for acute toxoplasmosis, as these studies alone cannot distinguish active from latent infection.[29,30] However, in patients with known baseline antitoxoplasma IgG levels, an increase in the IgG level in the presence of clinical symptoms may indicate reactivation of *Toxoplasma* infection.[30] A negative serologic test for IgG makes the diagnosis of acute toxoplasmosis less likely, and other causes of focal neurologic deficits should be included in the differential diagnosis. However, negative IgG serology does not definitively exclude acute toxoplasmosis, as patients with advanced HIV infection may become seronegative;[30] in such instances, checking the patient's medical record (when available) may be helpful in determining their prior serostatus. False-negative results may occur in patients with recent infection or may occur due to insensitive assays.[30]

IgM antitoxoplasma antibody usually disappears within weeks to months after the primary infection but may remain elevated for more than 1 year. Therefore, elevated IgM levels do not always suggest recent infection.[31–33] Because antitoxoplasma IgM antibodies typically are absent in patients with reactivated disease and toxoplasmic encephalitis in HIV-infected patients is most often due to reactivated disease, the IgM antibody test is generally not useful in the workup for cerebral toxoplasmosis.[34] However, determining whether infection is recent is important in pregnant patients due to concerns for transplacental infection. In a pregnant woman with HIV infection, the interpretation of IgM serology becomes particularly challenging if it is unknown whether the woman was seropositive for *T. gondii* prior to pregnancy. In this case, serologic testing should be repeated 3 weeks after initial serologic testing is performed.[29] Positive and rising IgM levels can be interpreted as acute infection, recent infection, or a false-positive test result; however, positive IgM in the fetal blood is indicative of congenital infection.[29]

Imaging Studies

Contrast-enhanced MRI or CT of the brain is indicated when cerebral toxoplasmosis is suspected in HIV-infected patients. Imaging studies usually show multiple lesions located in the region of the cerebral cortex, corticomedullary junction, or basal ganglia, although a single lesion may sometimes be present.[35] The characteristic sign of cerebral toxoplasmosis is the asymmetric target sign, which represents a ring-enhancing abscess seen with both CT and MRI.[35,36] A noncontrast CT scan may reveal a hypodense lesion in the brain that can be mistaken for other types of focal brain lesions; however, a repeat CT scan with contrast will demonstrate the typical ring-enhancing sign.[36] On T1-weighted MRI, toxoplasmic lesions are typically hypointense in relation to the rest of the brain tissue. On T2-weighted MRI, the lesions are usually hyperintense.[37] As seen with CT with contrast, gadolinium-enhanced MRI usually demonstrates a ring-enhancing lesion with surrounding edema.[37] MRI is the modality of choice for diagnosing and monitoring the response to treatment of toxoplasmosis because it more sensitive than CT for detecting multiple lesions.[37] However, differentiating cerebral toxoplasmosis from CNS lymphoma can be difficult in the presence of surrounding edema and mass effect. In such cases, it is recommended that patients be treated for toxoplasmosis.[37]

Single photon emission computed tomography (SPECT) is an important tool for differentiating CNS lymphoma from toxoplasmic encephalitis. However, it is available only in specialized centers. Neuroimaging with ^{201}thallium SPECT shows increased uptake in AIDS patients with CNS lymphoma. In addition, SPECT has a sensitivity and specificity of 86% to 100% and 76% to 100%, respectively, for the diagnosis of CNS lymphoma.[38–41]

Cerebrospinal Fluid Analysis

Cerebrospinal fluid (CSF) analysis is rarely useful in the diagnosis of cerebral toxoplasmosis and is not performed routinely given the risk of increasing intracranial pressure with lumbar puncture. The case

patient did not undergo lumbar puncture due to the presence of bilateral papilledema and the CT findings of bitemporoparietal lesions, which suggested a space-occupying lesion and increased intracranial pressure. However, this procedure may be performed if the diagnosis of toxoplasmosis is not clear in a patient with altered mental status or features of meningitis.[42] CSF findings may include elevated protein, variable glucose levels, and mildly elevated white blood cell counts with a mononuclear predominance.[43] Identification of *T. gondii* nucleic acid using PCR may be helpful in establishing the diagnosis of toxoplasmic encephalitis, but this is not done routinely.[44]

Pathologic Evaluation

Pathologic examination of a brain biopsy specimen provides the definitive diagnosis of toxoplasmic encephalitis. Findings of tachyzoites or cysts surrounded by areas of inflammation are considered diagnostic. Reactivation can lead to brain abscesses with central avascular area. The surrounding brain tissue will show edema and inflammatory infiltrates by lymphocytes with perivascular cuffing. *Toxoplasma* cysts may appear as inflammatory solid or cystic granulomas secondary to glial mesenchymal reaction to necrotizing encephalitis, resulting in focal vasculitis.[22,45] The areas of CNS more frequently involved in toxoplasmosis are the brain stem, basal ganglia, pituitary gland, and corticomedullary junction.[45] Brain biopsy is not routinely used in the diagnosis of cerebral toxoplasmosis because noninvasive methods such as serology and imaging techniques can be used for making a presumptive diagnosis. Brain biopsy is very sensitive for diagnosing cerebral lesions but carries a significant risk of bleeding, damage to the surrounding tissue, and infection.[28] Biopsy is recommended when the diagnosis is doubtful or if the patient either does not respond to or worsens with empirical treatment.[46]

DIFFERENTIAL DIAGNOSIS

The differential diagnosis in HIV-positive patients who have multiple ring-enhancing lesions on CT or MRI is listed in **Table 1**.[47] The leading causes of CNS abnormality in patients with advanced HIV infection (< 50 cells/μL) include toxoplasmic encephalitis (19% of all brain lesions in AIDS patients),[48] primary CNS lymphoma (4%–7% of all brain lesions in AIDS patients),[47] progressive multifocal leukoencephalopathy, HIV encephalopathy, and cytomegalovirus encephalitis.[47] Other infectious etiologies to consider in patients with advanced HIV infection who have CNS abnormality include tuberculosis, *Staphylococcus, Streptococcus, Salmonella, Listeria, Nocardia, Rhodococcus,* cryptococcosis, histoplasmosis, candidiasis, coccidioidomycosis, aspergillosis, trypanosomiasis, herpetic meningoencephalitis, neurocysticercosis, meningovascular syphilis, and amebic abscesses.[49]

Table 1. Differential Diagnosis for Ring-Enhancing Lesions in HIV-Infected Patients

Acute toxoplasmosis
Primary central nervous system lymphoma
Primary brain tumors (rarely glioblastoma)
Brain metastasis
Demyelinating diseases (eg, multiple sclerosis, vasculitis)
Infections (eg, brain abscess, tuberculoma)
Multifocal infarcts
Inherited lesions (eg, hemangioblastoma associated with von Hippel-Lindau disease)
Arteriovenous malformation

TREATMENT

First-line therapy for acute toxoplasmosis in HIV-infected patients is pyrimethamine and sulfadiazine (**Table 2**). As this combination leads to the sequential inhibition of enzymes in the folic acid synthesis pathway, leucovorin must be added to avoid hematologic complications.[34] Treatment for pregnant women infected with *T. gondii* is the same as for nonpregnant adults, but the mother should be made aware that sulfadiazine can cause hyperbilirubinemia and kernicterus in the baby.[34] There are alternative treatment regimens for patients who cannot tolerate sulfadiazine or pyrimethamine (Table 2).[34,50–52] Skin rashes, a common adverse effect of sulfadiazine leading to discontinuation of therapy, can be palliated by simultaneously starting antihistamines.[34] Sulfadiazine also may cause crystal-induced nephropathy. In critically ill patients who are unable to take medication orally, intravenous trimethoprim (TMP) 10 mg/kg daily plus sulfamethoxazole (SMX) 50 mg/kg daily can be considered.[50,53]

Acute infections should be treated for a minimum of 3 weeks, but 6 weeks of therapy is preferred in patients who can tolerate it. Longer duration should be considered for patients who have persistent radiologic or clinical evidence of infection.[54] Approximately 65% to 90% of patients respond to treatment with pyrimethamine, leucovorin, and sulfadiazine.[2,51,55] Rapid clinical improvement should be seen after starting appropriate therapy for acute toxoplasmosis. By day 3, 51% of patients show neurologic improvement, with 91% of patients demonstrating neurologic improvement by day 14.[56] Radiologic

Table 2. Treatment Regimens for Acute Toxoplasmosis in Adult HIV Patients

Preferred Therapy and Duration	Alternative Regimens
Pyrimethamine (200-mg oral loading dose, followed by 50–75 mg/day orally), sulfadiazine (1000–1500 mg 4 times daily), and leucovorin (10–20 mg/day) for up to 6 weeks	Pyrimethamine (200-mg oral loading dose, followed by 50–75 mg/day orally) and clindamycin (600 mg intravenously [IV] or orally 4 times daily)
	TMP (5 mg/kg) and SMX (25 mg/kg) IV or orally twice daily
	Atovaquone* (1500 mg orally twice daily) plus pyrimethamine (50–75 mg/day) and leucovorin (10–20 mg/day)
	Atovaquone* (1500 mg orally twice daily) plus sulfadiazine (1000–1500 mg 4 times daily)
	Atovaquone* (1500 mg orally twice daily)
	Pyrimethamine (50–75 mg/day) and leucovorin (10–20 mg/day) plus azithromycin (900–1200 mg/day orally)
	For severely ill patients who cannot tolerate oral medications, TMP (10 mg/kg/day) and SMX (50 mg/kg/day) IV

Adapted from Benson CA, Kaplan JE, Masur H, et al. Treating opportunistic infections among HIV-infected adults and adolescents: recommendations from CDC, the National Institutes of Health, and the HIV Medicine Association/Infectious Diseases Society of America. Available at http://aidsinfo.nih.gov/contentfiles/TreatmentofOIAA.pdf. Accessed 28 May 2008.

TMP = trimethoprim; SMX = sulfamethoxazole.

*Atovaquone should be taken with meals or nutritional support.

improvement is seen by the third week of therapy.[2] In patients not responding to treatment within 10 to 14 days or showing clinical deterioration by day 3, biopsy should be considered to rule out lymphoma.[56]

There are no clear-cut guidelines as to when antiretroviral medications should be started or restarted in an HIV-infected patient with acute toxoplasmosis. The common consensus is that antiretroviral medication can be restarted at the physician's discretion once acute toxoplasmosis has been treated and after discussion with the patient.

Corticosteroid therapy should be considered in patients whose clinical condition deteriorates within the first 48 hours of treatment or who have radiologic evidence of midline shift or signs of increased intracranial pressure. Dexamethasone (4 mg every 6 hr) is the most commonly administered agent, and it is tapered over the next few days.[34] Steroids should be used carefully in patients with HIV infection, as these drugs may mask other opportunistic infections. Anticonvulsants should be started for patients with seizures but are not recommended for routine use.[34]

PROPHYLAXIS

Nonpharmacologic Measures

Screening for antitoxoplasma IgG antibodies should be performed once a patient is diagnosed with HIV in order to assess his or her risk for developing acute toxoplasmosis. Seronegative patients should be rescreened for *T. gondii* infection when their CD4+ levels decrease below 100 cells/μL to determine if they have seroconverted.[34] All patients with HIV infection should be instructed about proper food handling and preparation to avoid infection with *T. gondii* regardless of serostatus. Specifically, patients should be told to wash hands after touching uncooked or undercooked meat as well to wash vegetables and fruits before consumption and to eat only properly cooked meat.[34] In addition, patients should avoid contact with any material that could be contaminated with cat feces and use gloves when cleaning cat litter boxes or when gardening.[34,57] However, HIV-infected persons do not need to avoid contact with household cats entirely.[34] Finally, all patients diagnosed with HIV should be educated about primary and secondary medical prophylaxis for *T. gondii* infection.

Primary and Secondary Pharmacologic Prevention

In seropositive patients, primary prophylaxis is recommended for HIV patients with a CD4+ count below 100 cells/μL and in those with a CD4+ count below 200 cells/μL who have opportunistic infections or concurrent malignancy.[34] Prophylaxis against *T. gondii* with TMP-SMX in patients with CD4+ counts less than 100 cells/μL has been shown to reduce the risk for toxoplasmosis by 73%.[9] TMP-SMX is the preferred agent for primary prophylaxis, but there are alternate regimens for patients who cannot tolerate standard prophylaxis (**Table 3**).

HIV-infected patients who do not receive maintenance therapy after treatment of acute toxoplasmosis have a 50% to 80% relapse rate of toxoplasmic encephalitis.[58,59] Patients should receive secondary prophylaxis following 6 weeks of therapy for acute infection.[60,61] Alternative combination regimens should be considered

Table 3. Prophylaxis Regimens for *Toxoplasma gondii* Infection in Adult HIV Patients

Indication	Preferred Therapy	Alternative Regimens
Primary prophylaxis	1 double-strength TMP-SMX (160 mg TMP/800 mg SMX) tablet daily	1 single-strength TMP/SMX tablet daily
		Dapsone 50 mg daily plus pyrimethamine 50 mg weekly and leucovorin 25 mg weekly
		Atovaquone 1500 mg daily
Secondary prophylaxis	Sulfadiazine (500–1000 mg orally 4 times daily) plus pyrimethamine (25–50 mg/day orally) and leucovorin (10–25 mg/day orally)	Clindamycin (300–450 mg orally every 6–8 hr) plus pyrimethamine (25–50 mg/day orally) and leucovorin (10–25 mg/day orally)
		Atovaquone (750 mg every 6–12 hr) with or without pyrimethamine (25 mg/day orally) plus leucovorin (10 mg/day orally)

Adapted from Kaplan JE, Masur H, Holmes KK. Guidelines for the prevention of opportunistic infections among HIV-infected persons—2002. Recommendations of the U.S. Public Health Service and the Infectious Diseases Society of America. Available at http://aidsinfo.nih.gov/contentfiles/OIpreventionGL.pdf. Accessed 28 May 2008.

TMP = trimethoprim; SMX = sulfamethoxazole.

for patients who cannot tolerate sulfadiazine or pyrimethamine (Table 3).[34] Atovaquone as monotherapy can be considered for patients who cannot tolerate pyrimethamine, but the relapse rate is 26% during the first year of treatment.[62]

Immune Reconstitution

If the patient's CD4+ count increases to more than 200 cells/μL for 3 consecutive months, primary prophylaxis for both *P. jiroveci* pneumonia and toxoplasmosis can be safely discontinued.[63] According to current guidelines, secondary prophylaxis can be discontinued if the CD4+ counts increases to greater than 200 cells/μL and is sustained for more than 6 months.[34] Primary or secondary prophylaxis should be reinitiated if the CD4+ count declines below 200 cells/μL.[34]

CONCLUSION

Acute cerebral toxoplasmosis is the most common cause of focal neurologic disorder in AIDS patients. If not detected and treated promptly, cerebral toxoplasmosis may cause significant morbidity and mortality. Prophylaxis is key to preventing negative outcomes. All HIV-infected patients should be educated about nonpharmacologic and medical prophylaxis for *T. gondii* infection, and seropositive patients should receive either primary or secondary prophylaxis for toxoplasmosis. **HP**

Corresponding author: Suriya Jayawardena, MD, Coney Island Hospital, 260 Ocean Parkway, Brooklyn, NY11235; suriyakbrsj@yahoo.com.

REFERENCES

1. Porter SB, Sande MA. Toxoplasmosis of the central nervous system in the acquired immunodeficiency syndrome. N Engl J Med 1992;327:1643–8.
2. Renold C, Sugar A, Chave JP, et al. *Toxoplasma* encephalitis in patients with the acquired immunodeficiency syndrome. Medicine (Baltimore) 1992;71:224–39.
3. Jones JL, Hanson DL, Dworkin MS, et al. Surveillance for AIDS-defining opportunistic illnesses, 1992–1997. MMWR CDC Surveill Summ 1999;48:1–22.
4. Jones JL, Kruszon-Moran D, Wilson M, et al. *Toxoplasma gondii* infection in the United States: seroprevalence and risk factors. Am J Epidemiol 2001;154:357–65.
5. Falusi O, French AL, Seaberg EC, et al. Prevalence and predictors of *Toxoplasma* seropositivity in women with and at risk for human immunodeficiency virus infection. Clin Infect Dis 2002;35:1414–7.
6. Sacktor N, Lyles RH, Skolasky R, et al; Multicenter AIDS Cohort Study. HIV-associated neurologic disease incidence changes: Multicenter AIDS Cohort Study, 1990–1998. Neurology 2001;56:257–60.
7. Abgrall S, Rabaud C, Costagliola D; Clinical Epidemiology Group of the French Hospital Database on HIV. Incidence and risk factors for toxoplasmic encephalitis in human immunodeficiency virus-infected patients before and during the highly active antiretroviral therapy era. Clin Infect Dis 2001;33:1747–55.
8. Luft BJ, Remington JS. Toxoplasmic encephalitis in AIDS. Clin Infect Dis 1992;15:211–22.
9. San-Andres FJ, Rubio R, Castilla J, et al. Incidence of acquired immunodeficiency syndrome-associated opportunistic diseases and the effect of treatment on a cohort of 1115 patients infected with human immunodeficiency virus, 1989–1997. Clin Infect Dis 2003;36:1177–85.
10. Antinori A, Larussa D, Cingolani A, et al; Italian Registry Investigative NeuroAIDS. Prevalence, associated factors, and prognostic determinants of AIDS-related toxoplasmic encephalitis in the era of advanced highly active antiretroviral therapy. Clin Infect Dis 2004;39:1681–91.
11. Mead PS, Slutsker L, Dietz V, et al. Food-related illness and death in the United States. Emerg Infect Dis 1999;5:607–25.
12. Rabaud C, May T, Amiel C, et al. Extracerebral toxoplasmosis in patients infected with HIV. A French National Survey. Medicine (Baltimore) 1994;73:306–14.
13. Remington JS, McLeod R, Thulliez P, Desmonts G. Toxoplasmosis. In: Remington JS, Klein JO, editors. Infectious diseases of the fetus and newborn infant. 5th ed. Philadelphia: Saunders; 2001:205–346.
14. Jones J, Lopez A, Wilson M. Congenital toxoplasmosis. Am Fam Physician 2003;67:2131–8.
15. Black MW, Boothroyd JC. Lytic cycle of *Toxoplasma gondii*. Microbiol Mol Biol Rev 2000;64:607–23.
16. Gauchat JF, Henchoz S, Fattah D, et al. CD40 ligand is functionally expressed on human eosinophils. Eur J Immunol 1995;25:863–5.
17. Gazzinelli RT, Hakim FT, Hieny S, et al. Synergistic role of CD4+ and CD8+ T lymphocytes in IFN-gamma production and protective immunity induced by an attenuated *Toxoplasma gondii* vaccine. J Immunol 1991;146:286–92.
18. Subauste CS. CD154 and type-1 cytokine response: from hyper IgM syndrome to human immunodeficiency virus infection. J Infect Dis 2002;185 Suppl 1:S83–9.
19. Subauste CS, Remington JS. Immunity to *Toxoplasma gondii*. Curr Opin Immunol 1993;5:532–7.
20. Dubey JP, Lindsay DS, Speer CA. Structures of *Toxoplasma gondii* tachyzoites, bradyzoites, and sporozoites and biology and development of tissue cysts. Clin Microbiol Rev 1998;11:267–99.

21. Bhopale GM. Pathogenesis of toxoplasmosis. Comp Immunol Microbiol Infect Dis 2003;26:213–22.
22. Subauste CS, Wessendarp M, Portilllo JA, et al. Pathogen-specific induction of CD154 is impaired in CD4+ T cells from human immunodeficiency virus-infected patients. J Infect Dis 2004;189:61–70.
23. Denkers EY, Gazzinelli RT. Regulation and function of T-cell-mediated immunity during *Toxoplasma gondii* infection. Clin Microbiol Rev 1998;11:569–88.
24. Navia BA, Petito CK, Gold JW, et al. Cerebral toxoplasmosis complicating the acquired immune deficiency syndrome: clinical and neuropathological findings in 27 patients. Ann Neurol 1986;19:224–38.
25. Speirs G, Mijch AS, Lucas CR, et al; International Conference on AIDS. CNS toxoplasmosis in AIDS patients: a clinical, pathological, serological and radiological review of 39 cases [abstract]. Int Conf AIDS 1991;7:186.
26. Levy RM, Bredesen DE. Central nervous system dysfunction in acquired immunodeficiency syndrome. J Acquir Immune Defic Syndr 1988;1:41–64.
27. Moshfeghi DM, Dodds EM, Couto CA, et al. Diagnostic approaches to severe, atypical toxoplasmosis mimicking acute retinal necrosis. Ophthalmology 2004;111:716–25.
28. Hornef MW, Iten A, Maeder P, et al. Brain biopsy in patients with acquired immunodeficiency syndrome: diagnostic value, clinical performance, and survival time. Arch Intern Med 1999;1:2590–6.
29. Sensini A. *Toxoplasma gondii* infection in pregnancy: opportunities and pitfalls of serological diagnosis. Clin Microbiol Infect 2006;12:504–12.
30. Montoya JG. Laboratory diagnosis of *Toxoplasma gondii* infection and toxoplasmosis. J Infect Dis 2002;185 Suppl 1:S73–S82.
31. Sulzer AJ, Franco EL, Takafuji E, et al. An oocyst-transmitted outbreak of toxoplasmosis: patterns of immunoglobulin G and M over one year. Am J Trop Med Hyg 1986;35:290–6.
32. Brooks RG, McCabe RE, Remington JS. Role of serology in the diagnosis of toxoplasmic lymphadenopathy. Rev Infect Dis 1987;9:1055–62.
33. Hedman K, Lappalainen M, Söderlund M, Hedman L. Avidity of IgG in serodiagnosis of infectious diseases. Rev Med Microbiol 1993;4:123–9.
34. Benson CA, Kaplan JE, Masur H, et al; CDC; National Institutes of Health; Infectious Diseases Society of America. Treating opportunistic infections among HIV-infected adults and adolescents: recommendations from CDC, the National Institutes of Health, and the HIV Medicine Association/Infectious Diseases Society of America. [published erratum appears in MMWR Morb Mortal Wkly Rep 2005;54:311]. MMWR Recomm Rep 2004; 53:1–112.
35. Miguel J, Champalimaud JL, Borges A, et al. [Cerebral toxoplasmosis in AIDS patients, CT and MRI images and differential diagnostic problems.] [Article in Portuguese.] Acta Med Port 1996;9:29–36.
36. Post MJ, Sheldon JJ, Hensley GT, et al. Central nervous system disease in acquired immunodeficiency syndrome: prospective correlation using CT, MR imaging, and pathologic studies. Radiology 1986;158:141–8.
37. Dina TS. Primary central nervous system lymphoma versus toxoplamosis in AIDS. Radiology 1991;179:823–8.
38. O'Malley JP, Ziessman HA, Kumar PN, et al. Diagnosis of intracranial lymphoma in patients with AIDS: value of 201TI single-photon emission computed tomography. AJR Am J Roentgenol 1994;163:417–21.
39. Lorberboym M, Wallach F, Estok L, et al. Thallium-201 retention in focal intracranial lesions for differential diagnosis of primary lymphoma and nonmalignant lesions in AIDS patients. J Nucl Med 1998;39:1366–9.
40. Lorberboym M, Estok L, Machac J, et al. Rapid differential diagnosis of cerebral toxoplasmosis and primary central nervous system lymphoma by thallium-201 SPECT. J Nucl Med 1996;37:1150–4.
41. Skiest DJ, Erdman W, Chang WE, et al. SPECT thallium-201 combined with *Toxoplasma* serology for the presumptive diagnosis of focal central nervous system mass lesions in patients with AIDS. J Infect 2000;40:274–81.
42. Greelee JE. Approach to diagnosis of meningitis. Cerebrospinal fluid evaluation. Infect Dis Clin North Am 1990;4:583–98.
43. Machodo LR, Livramento JA, Spina-França A. Neurotoxoplasmosis and AIDS. Cerebrospinal fluid analysis in 96 patients. Arq Neuropsiquiatr 1992;50: 497–500.
44. Dupon M, Cazenave J, Pellegrin JL, el al. Detection of *Toxoplasma gondii* by PCR and tissue culture in cerebrospinal fluid and blood of human immunodeficiency virus-seropositive patients. J Clin Microbiol 1995;33:2421–6.
45. Farkash AE, Maccabee PJ, Sher JH, et al. CNS toxoplasmosis in acquired immune deficiency syndrome: a clinical-pathological-radiological review of 12 cases. J Neurol Neurosurg Psychiatry 1986;49:744–8.
46. Rosenblum ML, Bredesen DE, Levy RM. Algorithms for the treatment of AIDS patients with neurological disease. In: Berger JR, Levy R, editors. AIDS and the nervous system. New York: Raven Press; 1988:157–91.
47. Levy RM, Bredesen DE, Rosenblum ML. Neurological manifestations of the acquired immunodeficiency syndrome (AIDS): experience at UCSF and review of the literature. J Neurosurg 1985;62:475–95.
48. Ammassari A, Scoppettuolo G, Murri R, et al. Changing disease patterns in focal brain lesion-causing disorders in AIDS. J Acquir Immune Defic Syndr Hum Retrovirol 1998;18:365–71.
49. Skiest DJ. Focal neurological disease in patients with acquired immunodeficiency syndrome. Clin Infect Dis 2002;34:103–15.
50. Torre D, Casari S, Speranza F, et al. Randomized trial of trimethoprim-sulfamethoxazole versus pyrimethamine-sulfadiazine for therapy of toxoplasmic encephalitis in patients with AIDS. Italian Collaborative Study Group. Antimicrob Agents Chemother 1998;42:1346–9.
51. Dannemann B, McCutchan JA, Israelski D, et al. Treatment of toxoplasmic encephalitis in patients with AIDS. A randomized trial comparing pyrimethamine plus clindamycin to pyrimethamine plus sulfadiazine. The California Collaborative Treatment Group. Ann Intern Med 1992;116:33–43.
52. Katlama C, De Wit S, O'Doherty E, et al. Pyrimethamine-clindamycin vs. pyrimethamine-sulfadiazine as acute and long-term therapy for toxoplasmic encephalitis in patients with AIDS. Clin Infect Dis 1996;22:268–75.
53. Torre D, Speranza F, Martegani R, et al. A retrospective study of treatment of cerebral toxoplasmosis in AIDS patients with trimethoprim-sulphamethoxazole. J Infect 1998;37:15–8.
54. Luft BJ, Conley F, Remington JS, et al. Outbreak of central-nervous-system toxoplasmosis in western Europe and North America. Lancet 1983;1: 781–4.
55. Leport C, Raffi F, Matheron S, et al. Treatment of central nervous system toxoplasmosis with pyrimethamine/sulfadiazine combination in 35 patients with the acquired immunodeficiency syndrome. Efficacy of long-term continuous therapy. Am J Med 1988;84:94–100.
56. Luft BJ, Hafner R, Korzun AH, et al. Toxoplasmic encephalitis in patients with the acquired immunodeficiency syndrome. Members of the ACTG 077p/ANRS 009 Study Team. N Engl J Med 1993;329:995–1000.
57. 1999 USPHS/IDSA guidelines for the prevention of opportunistic infections in persons infected with human immunodeficiency virus. USPHS/IDSA Prevention of Opportunistic Infections Working Group. Infectious Diseases Society of America. Ann Intern Med 1999;131:873–908.
58. Pedrol E, Gonzalez-Clemente JM, Gatell JM, et al. Central nervous system toxoplasmosis in AIDS patients: efficacy of an intermittent maintenance therapy. AIDS 1990;4:511–7.
59. Haverkos HW. Assessment of therapy for *Toxoplasma* encephalitis. The TE Study Group. Am J Med 1987;82:907–14.
60. Podzamczer D, Miro JM, Bolao F, et al. Twice-weekly maintenance therapy with sulfadiazine-pyrimethamine to prevent recurrent toxoplasmic encephalitis in patients with AIDS. Ann Intern Med 1995;123:175–80.
61. Kirk O, Reiss P, Uberti-Foppa C, et al; European HIV Cohorts. Safe interruption of maintenance therapy against previous infection with four common HIV-associated opportunistic pathogens during potent antiretroviral therapy. Ann Intern Med 2002;137:239–50.
62. Katlama C, Mouthon B, Gourdon D, et al. Atovaquone as long-term suppressive therapy for toxoplasmic encephalitis in patients with AIDS and multiple drug intolerance. Atovaquone Expanded Access Group. AIDS 1996;10: 1107–12.
63. Furrer H, Opravil M, Bernasconi E, et al. Stopping primary prophylaxis in HIV-1-infected patients at high risk of *Toxoplasma* encephalitis. Swiss HIV Cohort Study. Lancet 2000;355:2217–8.

Copyright 2008 by Turner White Communications Inc., Wayne, PA. All rights reserved.