Necrotizing Inflammation of the Cecum in a Neutropenic Patient

Mikael Petrosyan, MD
Joaquin J. Estrada, MD
Rodney J. Mason, MD, PhD

Typhlitis, also called "ileocecal syndrome" and neutropenic enterocolitis, refers to inflammation of the cecum that is usually caused by an infectious agent. This condition is typically seen in immunocompromised patients (eg, HIV/AIDS, malignancy, aplastic anemia) and most frequently occurs in patients who have recently undergone chemotherapy.[1] As typhlitis represents a potentially life-threatening condition that is becoming increasingly more common in patients diagnosed with cancer, physicians should be familiar with its presentation and management. This article presents the case of a 32-year-old man who presented with right lower quadrant pain, fever, and diarrhea and was subsequently diagnosed with typhlitis.

CASE PRESENTATION

A 32-year-old man with newly diagnosed acute myelogenous leukemia (AML) presented to the emergency department with a 2-day history of bloody diarrhea and abdominal pain. The patient underwent outpatient induction chemotherapy with cytarabine and idarubicin for treatment of AML approximately 1 week prior to presentation. Associated symptoms included nausea, anorexia, high-grade fevers, and vomiting. He had never been hospitalized or undergone surgery.

Physical Examination

On examination, the patient appeared to be in mild distress. His vital signs were as follows: temperature, 101.2°F; blood pressure, 134/77 mm Hg; heart rate, 110 bpm; and respiratory rate, 22 breaths/min. Neurologic and lung examination were normal, but cardiac examination revealed sinus tachycardia. The patient had generalized abdominal pain, voluntary guarding, and significant tenderness to palpation in the lower abdominal region. Rectal examination was normal without any gross blood.

Laboratory and Imaging Studies

Laboratory studies ordered in the emergency department revealed a white blood cell count of 900 cells/μL (normal, 4500–10,500 cells/μL), hemoglobin of 9.5 g/dL (normal, 12–15 g/dL), hematocrit of 27.4% (normal, 35%–45%), and platelet count of 90,000 cells/μL (normal, 150,000–450,000 cells/μL). Serum liver function tests as well as amylase, lipase, and serum lactate levels were within normal limits. Blood and stool samples for culture were obtained and sent for laboratory analysis. Plain abdominal radiographs demonstrated a dilated colon. Chest radiograph was normal without pneumoperitoneum.

Diagnosis

Based on the presenting symptoms of abdominal pain, recent diagnosis of AML followed by induction chemotherapy, and the presence of neutropenia, a preliminary diagnosis of typhlitis was made. Computed tomography (CT) scan demonstrated mild cecal wall thickening, which also suggested the diagnosis of typhlitis. He was admitted to the hospital with administration of intravenous (IV) fluid resuscitation and broad-spectrum antibiotics (1-wk course of vancomycin 1 g IV every 12 hr, cefepime 2 g IV every 8 hr, amikacin 600 mg every 12 hr, and metronidazole 500 mg orally every 8 hr). On hospital day 2, the initial blood and stool cultures obtained before treatment with antibiotics were reported as negative. Stool sample testing for *Clostridium difficile* toxin was also negative. Over the next 72 hours, the patient remained febrile with worsening abdominal pain. Repeat CT scan revealed progression of intramural edema of the cecum and terminal ileum consistent with enterocolitis (**Figure 1**).

Drs. Petrosyan and Estrada are general surgery residents, Division of Emergency (Non-Trauma) Surgery, Los Angeles County and University of Southern California Medical Center, Los Angeles, CA. Dr. Mason is an associate professor of surgery, Department of Surgery, Keck School of Medicine of the University of Southern California, Los Angeles, CA; and chief, Division of Emergency (Non-Trauma) Surgery, Los Angeles County and University of Southern California Medical Center.

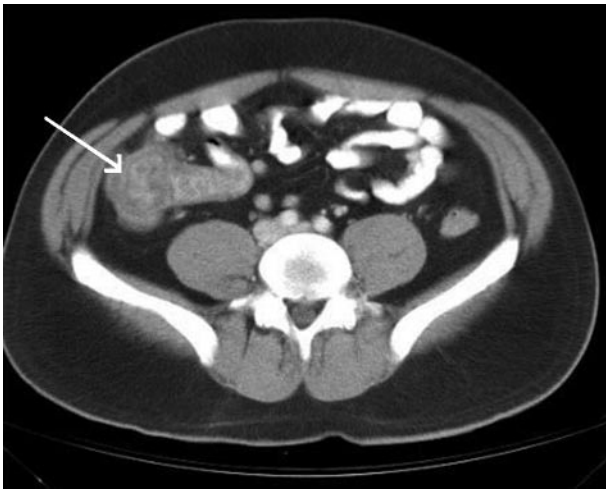

Figure 1. Computed tomography scan of the abdomen demonstrating extensive intramural edema and mucosal wall thickening of the cecum with terminal ileitis (*arrow*) consistent with enterocolitis.

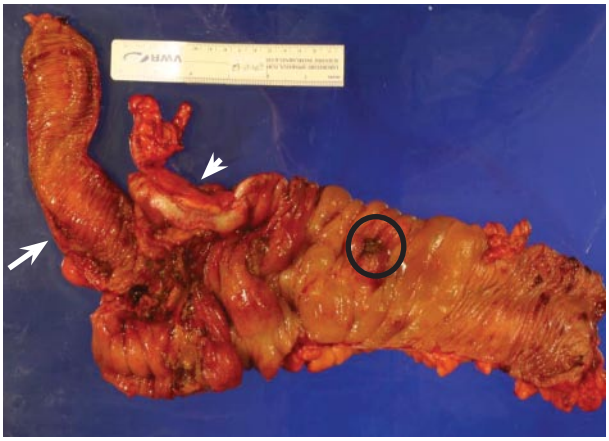

Figure 2. Gross pathologic specimen obtained from right hemicolectomy of the case patient demonstrating edema of the terminal ileum (*arrow*) and the cecum (*arrowhead*). Pathologic examination also revealed a necrotic ulcer (*circle*) located in the ascending colon.

Management

The patient's worsening clinical condition, the presence of peritoneal signs on repeat abdominal examination, and the new CT findings prompted exploratory laparotomy. Intraoperative findings included massive distention of the cecum with patchy areas of cecal wall necrosis without perforation. Terminal ileitis with free fluid in the pelvis was also noted. Right hemicolectomy and ileostomy were performed (**Figure 2**).

Pathologic examination of the cecum and ileocecal valve showed coagulative necrosis of the mucosa and submucosa due to thrombosis in the small vessels. Acute inflammation surrounding the area of necrosis and focal extensions into muscularis externa with microabscesses were noted (**Figure 3**). *Aspergillus* was also found in the necrotic areas with vascular invasion (**Figure 4**). Antifungal therapy (fluconazole 400 mg/day IV) was started following the pathologic diagnosis of infiltration with aspergillosis.

Postoperatively, the patient showed significant improvement, and his subsequent hospital course was uneventful. By the fifth postoperative day, he was tolerating diet and had normal ileostomy function. He was discharged home on postoperative day 7 after completing his full course of antibiotic and antifungal drugs. An ileostomy takedown and restoration of bowel continuity were planned once remission of his AML was achieved.

DISCUSSION

Typhlitis was first described as a treatment-related complication occurring in childhood leukemias but subsequently has been reported in adult patients.[2–5] In recent years, the incidence of typhlitis has increased in the adult population due to the utilization of new and more aggressive chemotherapy protocols.[6–10] Typhlitis most commonly occurs in patients with leukemia or lymphoma after induction chemotherapy and is a potentially life-threatening condition.[11–13]

Pathophysiology

The pathophysiology of typhlitis in patients diagnosed with cancer is not completely understood but is thought to be a multifactorial process that involves cecal mucosal injury caused by combination therapy with cytotoxic drugs, followed by mucosal invasion by various microorganisms. Mucosal invasion occurs due to the impaired innate host defense mechanism.[1] The host immune system may be compromised due to the cancer itself (eg, hematologic malignancies) or cytotoxic therapy. Significant neutropenia is an invariable finding.[1] Necrosis of the bowel secondary to mucosal ischemia and ulceration involving the cecum ensues. It may extend to involve the ascending colon and terminal ileum,[2] as was seen in this case. Inflammatory changes seen in neutropenic enterocolitis are usually localized to the cecum. It is thought that high distensibility, decreased vascularity, and the large lymphoid content predispose the cecum to injury.[2] Polymicrobial infections usually predominate. Various opportunistic pathogens are commonly involved, including *Pseudomonas,* clostridial species, and various fungal species, mainly *Candida albicans.*[14] In this case, the fungal species responsible for typhlitis was *Aspergillus.*

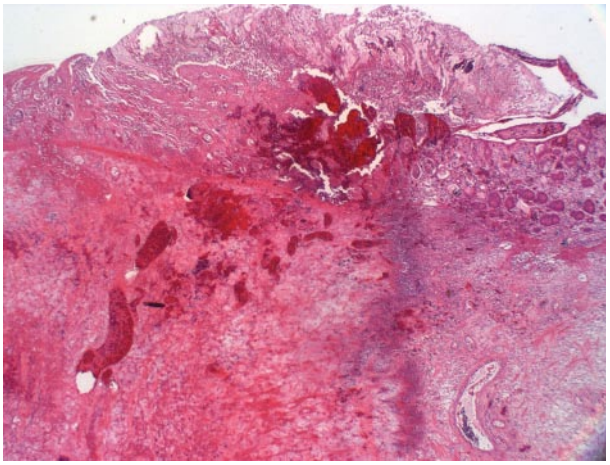

Figure 3. Histologic specimen demonstrating acute inflammation surrounding the necrotic lesions in the cecum and focal extensions into muscularis externa with microabscesses (hematoxylin and eosin stain, ×20).

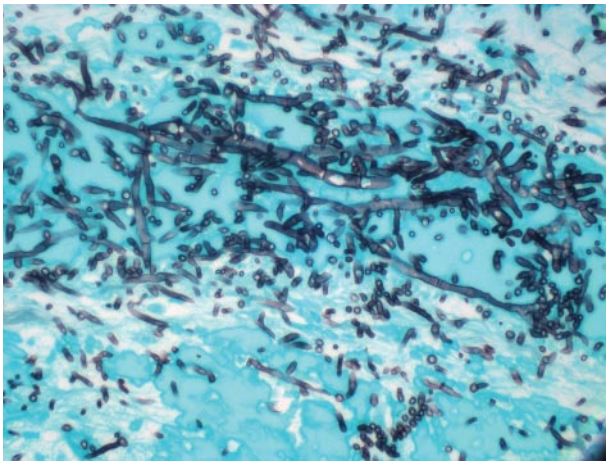

Figure 4. *Aspergillus* identified in the necrotic lesions of the case patient's colon (Gomori methenamine silver stain, ×400).

Diagnosis

Patients with typhlitis may present with generalized abdominal pain, nausea, emesis, diarrhea, and right lower quadrant pain.[4] Identifying typhlitis may be difficult in the early stages of this disease because the symptoms are nonspecific. The differential diagnosis includes gastroenteritis, constipation, acalculous cholecystitis, intestinal perforation, *C. difficile* colitis, pancreatitis, appendicitis, perforated ulcer, and necrotizing enterocolitis. Furthermore, some features of typhlitis may be mistaken for side effects of chemotherapy, such as those that occur with paclitaxel or doxorubicin.[8] Colonic perforation may occur as a late manifestation of typhlitis and is associated with a high mortality.[15] It is important to identify the cause of the patient's symptoms to ensure the correct therapy is instituted promptly. Clinicians should have a high index of suspicion for typhlitis in patients who present with significant neutropenia (absolute neutrophil count, < 500 cells/μL) and right lower abdominal pain,[11] particularly patients who recently have undergone chemotherapy such as the case patient.

Preferred imaging modalities for confirming the diagnosis of typhlitis are ultrasound and CT. CT tends to be favored over ultrasound as it has a lower false-negative rate (15% versus 23%).[4] Circumferential wall thickening, cecal distention, and presence of intramural edema are the usual findings of typhlitis seen on CT. Most complications such as pneumoperitoneum, fluid collections, abscesses, and pneumatosis coli may also be detected by CT.[16]

Treatment

There is some controversy in regards to how typhlitis should be managed,[1,17] as treatment approaches are derived from small case studies and recommendations range from conservative (medical) management[18] to immediate surgery[11] to individualizing care based on disease severity.[12,13] Medical management with intravenous fluids, nasogastric tube decompression, nutritional support, and intravenous antibiotics are often recommended.[18,19] Because concomitant invasion by several bacterial and fungal pathogens occur in this disease, broad-spectrum antibiotics along with antifungal agents[14] should be initiated when suspicion for typhlitis is high.[4,20] We believe that failure to start antifungal medications at the time of admission may have led to the clinical and radiologic deterioration observed in the case patient, prompting emergent surgical intervention. Hence, we recommend initiating antifungal agents such as amphotericin B or fluconazole in any neutropenic patient along with broad-spectrum antibiotics.[14]

Some authors recommend early surgery.[21] The 2 most recently published surgical series advocate selective surgical management of these patients, reserving surgical exploration only for patients with perforation, obstruction, abscess, and bleeding.[13,22] Potential surgical options include simple abscess drainage, cecostomy tube, colectomy with primary anastomosis, and colectomy with ileostomy. Simple drainage procedures may be considered if the patient is moribund and a poor surgical candidate. For most patients, a colectomy with ileostomy would be the most appropriate surgical option, especially in an immunocompromised patient. The case patient's recent concurrent diagnosis of AML

as well as the possibility of undergoing additional chemotherapy in the near future prompted us to perform a right hemicolectomy with end ileostomy. Poor wound healing and anastomotic breakdown associated with chemotherapy was avoided in this patient by performing a diverting ileostomy as opposed to a primary ileocolic anastomosis that usually would be performed in an immunocompetent patient.

CONCLUSION

Typhlitis is a life-threatening complication that occurs in patients undergoing chemotherapy. It is becoming increasingly common as aggressive chemotherapy regimens are being used more frequently. Awareness of the signs and symptoms of this disease is key to early diagnosis and aggressive medical management to avoid surgery and prevent potentially fatal complications. **HP**

Corresponding author: Rodney J. Mason, MD, PhD, LAC + USC Medical Center, 1200 North State Street, Room 10-850, Los Angeles, CA, 90033; rmason@surgery.usc.edu.

REFERENCES

1. Urbach DR, Rotstein OD. Typhlitis. Can J Surg 1999;42:415–9.
2. Katz JA, Wagner ML, Gresik MV, et al. Typhlitis: an 18-year experience and postmortem review. Cancer 1990;65:1041–7.
3. Moir DH, Bale PM. Necropsy findings in childhood leukaemia, emphasizing neutropenic enterocolitis and cerebral calcification. Pathology 1976;8:247–58.
4. Sloas MM, Flynn PM, Kaste SC, Patrick CC. Typhlitis in children with cancer: a 30-year experience. Clin Infect Dis 1993;17:484–90.
5. Wagner ML, Rosenberg HS, Fernbach DJ, Singleton EB. Typhlitis: a complication of leukemia in childhood. Am J Roentgenol Radium Ther Nucl Med 1970;109:341–50.
6. Del Fava RL, Cronin TG Jr. Typhlitis complicating leukemia in an adult: barium enema findings. AJR Am J Roentgenol 1977;129:347–8.
7. Harvey JS, Freeman R, Corbett PJ. A case of pneumococcal typhlitis. Arch Surg 1976;111:890.
8. Pestalozzi BC, Sotos GA, Choyke PL, et al. Typhlitis resulting from treatment with taxol and doxorubicin in patients with metastatic breast cancer. Cancer 1993;71:1797–800.
9. Pokorney BH, Jones JM, Shaikh BS, Aber RC. Typhlitis. A treatable cause of recurrent septicemia. JAMA 1980;243:682–3.
10. Starnes HF Jr, Moore FD, Mentzer S, et al. Abdominal pain in neutropenic cancer patients. Cancer 1986;57:616–21.
11. Avigan D, Richardson P, Elias A, et al. Neutropenic enterocolitis as a complication of high-dose chemotherapy with stem cell rescue in patients with solid tumors: a case series with a review of the literature. Cancer 1998;83:409–14.
12. Quigley MM, Bethel K, Nowacki M, et al. Neutropenic enterocolitis: a rare presenting complication of acute leukemia. Am J Hematol 2001;66:213–9.
13. Wade DS, Nava HR, Douglass HO Jr. Neutropenic enterocolitis. Clinical diagnosis and treatment. Cancer 1992;69:17–23.
14. Gorschlüter M, Mey U, Strehl J, et al. Invasive fungal infections in neutropenic enterocolitis: a systematic analysis of pathogens, incidence, treatment and mortality in adult patients. BMC Infect Dis 2006;6:35–45.
15. Ettinghausen SE. Collagenous colitis, eosinophilic colitis, and neutropenic colitis. Surg Clin North Am 1993;73:993–1016.
16. Frick MP, Maile CW, Crass JR, et al. Computed tomography of neutropenic colitis. AJR Am J Roentgenol 1984;143:763–5.
17. Williams N, Scott AD. Neutropenic colitis: a continuing surgical challenge. Br J Surg 1997;84:1200–5.
18. Shaked A, Shinar E, Freund H. Neutropenic typhlitis. A plea for conservatism. Dis Colon Rectum 1983;26:351–2.
19. Schlatter M, Snyder K, Freyer D. Successful nonoperative management of typhlitis in pediatric oncology patients. J Pediatr Surg 2002;37:1151–5.
20. Kaste SC, Flynn PM, Furman WL. Acute lymphoblastic leukemia presenting with typhlitis. Med Pediatr Oncol 1997;28:209–12.
21. Varki AP, Armitage JO, Feagler JR. Typhlitis in acute leukemia: successful treatment by early surgical intervention. Cancer 1979;43:695–7.
22. Moir CR, Scudamore CH, Benny WB. Typhlitis: selective surgical management. Am J Surg 1986;151:563–6.

Copyright 2008 by Turner White Communications Inc., Wayne, PA. All rights reserved.