Pancreatic Cholera Syndrome in a 42-Year-Old Woman

Bianca Afonso, MD
Bosede A. Afolabi, MD
Tolga Erim, DO
Elizabeth Stone, MD
Mariana Berho, MD

Pancreatic cholera syndrome, also known as Verner-Morrison syndrome[1] and WDHA syndrome, is a constellation of symptoms caused by VIPomas, a rare subtype of neuroendocrine tumor (NET) that typically originates in the pancreas. In this syndrome, excessive production of vasoactive intestinal polypeptide (VIP) provokes secretory diarrhea with associated electrolyte imbalance. VIPomas account for less than 1% of all pancreatic tumors and are usually solitary lesions larger than 3 cm, with 75% occurring in the tail of the pancreas. More than 60% of VIPomas metastasize by the time of diagnosis.[2] Diagnosis is dependent on confirming the presence of hormone hypersecretion and localizing the tumor using available imaging modalities. This article presents the case of a woman with the classic presentation of VIPoma who required multiple hospitalizations due to life-threatening hypokalemia. The approach to diagnosis of VIPoma and management of components of pancreatic cholera syndrome are also discussed.

CASE PRESENTATION

History and Physical Examination

A 42-year-old woman with no significant past medical history presented to her primary care physician with abdominal pain 15 days after an elective tubal ligation. Initially, the symptoms were thought to be related to the postoperative course and the patient was treated with opiates. However, symptoms persisted for 2 months and were associated with bouts of copious, watery, nonbloody diarrhea (occurring 3–4 times/day). She denied recent use of antibiotics or laxatives. Current medications were acetaminophen/oxycodone to control pain. She had no known drug allergies and denied a history of smoking or illicit drug use. Previous surgeries included the recent laparoscopic tubal ligation, cholecystectomy, breast augmentation, and tonsillectomy. Family history was noncontributory. The primary care physician ordered esophagogastroduodenoscopy and colonoscopy, both of which were unremarkable. Abdominal computed tomography (CT) performed 6 months prior as part of the preoperative evaluation for tubal ligation was also normal. The patient's symptoms worsened, with 8 to 10 bowel movements per day, generalized fatigue, and a 26-lb weight loss, leading to an emergency department (ED) visit.

In the ED, the patient's vital signs included a temperature of 99.8°F, blood pressure of 109/60 mm Hg, a regular heart rate of 98 bpm, respiratory rate of 20 breaths/min, and oxygen saturation of 99% on room air. Physical examination revealed abdominal distension, increased bowel sounds with no palpable masses or organomegaly, and a normal rectal examination.

Diagnostic Studies

Laboratory values on admission were notable for elevated alkaline phosphatase (348 U/L), aspartate aminotransferase (83 U/L), and alanine aminotransferase (49 U/L) levels. The potassium level was low at 2.4 mEq/L (normal, 3.5–5.0 mEq/L) and remained low despite daily oral potassium replacement. Stool cultures and samples for ovae, parasites, and *Clostridium difficile* toxin were negative.

Repeat abdominal, pelvic, and chest CT with intravenous contrast showed a 6.4 × 5.0-cm pancreatic mass, retroperitoneal and mediastinal adenopathy, and diffuse hepatic lesions suggestive of metastasis (**Figure 1**). An ultrasound-guided liver biopsy was performed and pathology revealed poorly differentiated carcinoma.

Drs. Afonso and Afolabi are residents, Department of Internal Medicine; Dr. Erim is a gastroenterology fellow, Department of Gastroenterology; Dr. Stone is an oncology attending, Department of Oncology; and Dr. Berho is a pathology attending, Department of Pathology; all are at the Cleveland Clinic Florida, Weston, FL.

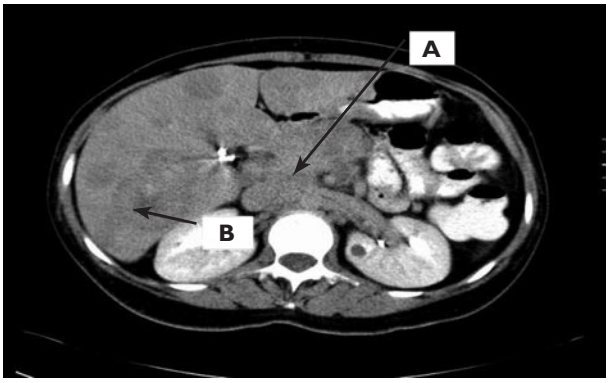

Figure 1. Computed tomography of the abdomen demonstrating a pancreatic mass (**A**) and hepatic metastasis (**B**).

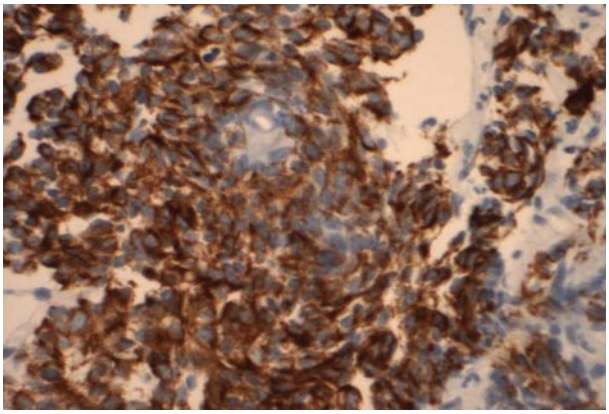

Figure 2. Synaptophysin stain of pancreatic tissue obtained by ultrasound-guided biopsy showing strong positivity in neoplastic cells.

Additional studies were requested, including immunoperoxidase stains for a suspected NET (**Figure 2**, **Figure 3**, and **Figure 4**). Immunoperoxidase stains came back strongly positive for synaptophysin and chromogranin (**Table**), suggestive of a NET. Additional laboratory testing revealed a markedly elevated VIP level (> 400 pg/mL; normal, 0–75 pg/mL), compatible with a diagnosis of VIPoma. Normal gastrin, insulin, and 5-hydroxyindoleacetic acid levels excluded gastrinoma, insulinoma, and carcinoid, respectively. Somatostatin receptor scintigraphy (octreotide scan) showed multiple areas of uptake in the liver and pancreatic bed, confirming metastatic spread of the tumor.

Treatment and Follow-up

The oncology department was consulted, and after extensive discussion with the patient, a decision was made to initiate chemotherapy considering the unusually aggressive disease course. The chemotherapeutic regimen consisted of alternate cycles of doxorubicin and dacarbazine followed by streptozocin and 5-fluorouracil (5-FU).[3] Hepatic artery chemoembolization was deferred given the rapid progression of symptoms, with the thought that it could be used in the future if the disease was better controlled.

The first cycle of doxorubicin and dacarbazine was started 10 days after initial diagnosis. Subcutaneous darbepoetin alfa and filgrastim were administered before each cycle of chemotherapy to prevent pancytopenia. The patient was hospitalized for the first cycle of chemotherapy due to low serum potassium levels. Diarrhea and hypokalemia persisted after completion of the first cycle, requiring longer hospitalization. Potassium levels were obtained twice daily, with levels persistently below 3.0 mEq/L, and potassium replacement up to 100 mEq/L/day was required. The gastroenterology department was consulted to help guide management of the patient's diarrhea. Daily subcutaneous injections of short-acting octreotide 50 µg every 8 hours were started, and gradually the patient's symptoms improved, with a decreased number of bowel movements per day and normalization of serum potassium. After 10 days, the patient was discharged home and long-acting octreotide (20 µg intramuscularly once monthly) was prescribed, with the first dose given in the hospital.

After the second cycle of chemotherapy, the patient was rehospitalized due to diarrhea, low potassium, and abdominal distention. Repeat abdominal and pelvic CT was unchanged from the previous hospitalization, and she was discharged home after 5 days. The third cycle of chemotherapy was completed as an outpatient.

At follow-up 2 months after starting chemotherapy, abdominal and pelvic CT showed a slight decrease in the size of the pancreatic tumor, but new metastasis to vertebrae and the left adrenal gland was evident.

DISCUSSION

The case patient presented with abdominal pain, diarrhea, and a pancreatic mass with liver metastases. A primary pancreatic malignancy (adenocarcinoma) was suspected; however, based on clinical presentation, carcinoid tumors and NET were part of the differential diagnosis. Positive synaptophysin and chromogranin stains confirmed a neuroendocrine cause, and further testing revealed elevated levels of VIP, establishing a diagnosis of VIPoma. Of note, the patient had a normal abdominal CT scan 6 months prior to onset of symptoms. However, CT with contrast may miss extensive hepatic disease if standard venous phase contrast is performed without arterial phase contrast.[4] Somatostatin analogues (eg, octreotide) are recommended to control symptoms

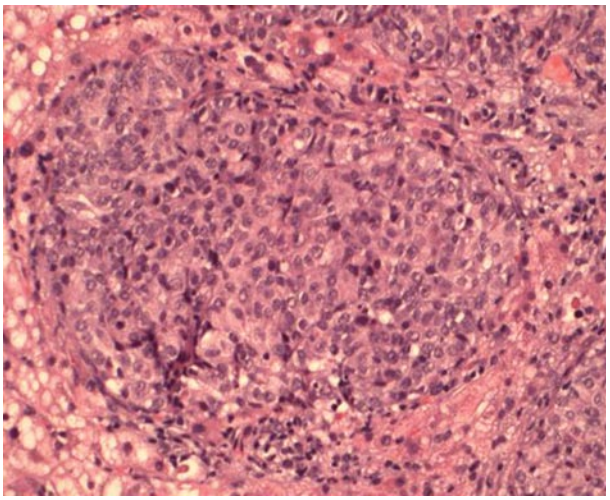

Figure 3. Hematoxylin-eosin stain of pancreatic tissue obtained by ultrasound-guided biopsy showing tumor cells arranged in cords and nests.

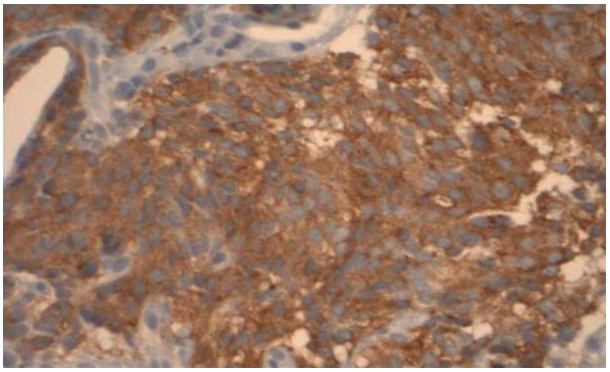

Figure 4. VIPoma-specific stain of pancreatic tissue obtained by ultrasound-guided biopsy showing strong positivity in neoplastic cells.

Table. Case Patient's Results of Histopathologic Staining

Synaptophysin	Positive
Chromogranin	Positive
Cytokeratin-7 receptor	Positive
Progestin receptor	Positive
Estrogen receptor	Negative
Cytokeratin-20	Negative
Carcinoembryonic antigen	Negative
Thyroid transcription factor-1	Negative

associated with secretory NET such as VIPomas. In this case, octreotide was initiated to control the refractory diarrhea and associated hypokalemia. With octreotide, tumor regression is seen in approximately 5% of patients.[5] However, the case patient had an aggressive variant of islet cell carcinoma with poorly differentiated pathology, which required chemotherapy. Treatment with 5-FU alone can provoke diarrhea (chemotherapy-induced diarrhea), and octreotide can also be used to manage this treatment side effect (maximum dose, 500 µg 3 times daily).

VIPOMAS

The majority (80%) of VIPomas are localized in the pancreas, usually the tail and body; however, VIPomas have also been found in the adrenal glands, retroperitoneum, mediastinum, lungs, and jejunum.[2,6] Men and women are equally affected, and the average age at diagnosis is 50 years. VIPomas can be multifocal in 4% of patients, and a small number (9%) are associated with multiple endocrine neoplasia type 1,[7] a hereditary disorder resulting in tumors of the pancreas and pituitary and parathyroid glands. Aggressive metastases are usually seen in the liver and are rarely found in the chest.[8] Other subtypes of NET include gastrinomas, insulinomas, carcinoid, glucagonomas, and somatostatinomas,[5,9] and most are associated with specific clinical syndromes and laboratory abnormalities (eg, gastrinomas with Zollinger-Ellison syndrome, insulinomas with hypoglycemia).[10]

Clinical Presentation

The main findings in VIPoma are components of pancreatic cholera syndrome—watery diarrhea, hypokalemia, and hypochlorhydria. In all patients, stool volume exceeds 700 mL/day, with some experiencing volumes of 3 L/day.[11–13] Stools are tea-colored in appearance, have no odor, persist with fasting, have a high sodium concentration, and have a low osmolal gap. Flushing is seen in approximately 20% of patients. Symptoms associated with hypokalemia and dehydration, including lethargy, nausea, vomiting, muscle weakness, and muscle cramps, may also be present. Approximately 75% of patients will have hypochlorhydria.

Diagnosis

Diagnosis of VIPoma is based on the presence of secretory diarrhea and elevated VIP levels (> 75 pg/mL) associated with a pancreatic mass found on imaging. An important differential diagnosis is carcinoid tumor,[14–16] which can be excluded with histopathologic staining. The challenges to diagnosis involve initially differentiating a primary lesion from a metastatic lesion after finding a pancreatic mass on imaging.

CT with contrast and magnetic resonance imaging are sensitive and specific for detecting VIPomas and associated metastases.[5,17] However, as mentioned previously,

initial CT may be inconclusive depending on the methods of contrast administration. Most VIPomas have low signal intensity on T1-weighted images and high signal intensity on T2-weighted images.[17]

Scintigraphy with ^{111}In-octreotide is one of the most important tools for diagnosing and staging VIPomas as well as for determining sensitivity to treatment with somatostatin analogues.[4,18] There is a general consensus that all patients should undergo scintigraphy with ^{111}In-octreotide during the course of the disease and treatment given its high sensitivity (75%–100%).[19]

Synaptophysin and chromogranin stains are highly sensitive and specific for NETs but cannot differentiate between subtypes.[20–22] Another helpful marker, serum chromogranin-A, is usually elevated in VIPomas but cannot differentiate between other NET subtypes.[23] Specific stains for VIP are not widely available and clinical correlation is mandatory.

Management

Surgery remains the treatment of choice and the only approach that can achieve cure in patients with VIPoma. However, most VIPomas are functioning aggressive tumors and present with metastasis upon diagnosis. Thus, the primary goal in the management of metastatic VIPomas is to regulate hypersecretion of VIP, which is usually achieved by initiating somatostatin analogue therapy, such as octreotide and lanreotide (available outside the United States). Since the introduction of somatostatin analogues, medical management of unresectable NETs has improved,[24] and most symptoms associated with VIPoma (ie, diarrhea) can be controlled with octreotide.[25] Octreotide is usually well-tolerated and is available in both short-acting (administered subcutaneously every 6–8 hr) and long-acting (administered once monthly) formulations. Short-acting formulations were the gold standard treatment for VIPomas; however, long-acting octreotide has the advantage of less frequent administration with similar effectiveness.[26–28] Main adverse effects are pain at the injection site, mild abdominal discomfort, and temporary elevation of total bilirubin (rare). Decreased tumor size has been reported in a small number of patients treated with octreotide.[29] Successful suppression of metastatic VIPoma has also been reported in an elderly patient on octeotride therapy without chemotherapy.[30]

Chemotherapy is considered for proliferating tumors. However, VIPomas (and all NETs) are not highly chemosensitive. Patients with a functioning NET respond better as compared with those with a nonfunctioning NET, but response rates with streptozocin and 5-FU are only 45%.[5,15]

Chemoembolization of liver metastases has been shown to produce regression of hormonal syndrome and is a possibility in selected cases.[31] Surgical debulking of multiple liver metastases can be used as a palliative intervention for some patients, although this is not curative.

Prognosis

In patients with VIPoma, the estimated 5- and 10-year survival is 88% and 25%, respectively. Small tumor size (< 4 cm), the absence of metastasis, and age 40 to 60 years is associated with a favorable prognosis, whereas prognosis is worse with larger tumor size and high rate of metastasis.[4] Survival is similar to that in patients with nonfunctioning tumors.

CONCLUSION

Most VIPomas are indolent and are usually diagnosed at a time when distant metastases are present. Treatment decisions should be individualized. Somatostatin analogues (ie, octreotide) have been shown to control symptoms associated with VIPoma, particularly secretory diarrhea. However, patients with more aggressive disease may benefit from chemotherapy. The standard guidelines of the National Comprehensive Cancer Center Network include treatment with streptozocin and doxorubicin with or without 5-FU.[3] Due to the complexity of managing patients with VIPoma, a multidisciplinary approach is strongly recommended. Referral to tertiary care centers with extensive experience in managing VIPoma can sometimes be a useful adjunct. **HP**

Corresponding author: Bosede A. Afolabi, MD, Department of Internal Medicine, 2950 Cleveland Clinic Boulevard, Weston, FL 33331; afolabb@ccf.org.

REFERENCES

1. Verner JV, Morrison AB. Islet cell tumor and a syndrome of refractory watery diarrhea and hypokalemia. Am J Med 1958;25:374–80.
2. Soga J, Yakuwa Y. Vipoma/diarrheogenic syndrome: a statistical evaluation of 241 reported cases. J Exp Clin Cancer Res 1998;17:389–400.
3. Moertel CG, Lefkopoulo M, Lipsitz S, et al. Streptozocin-doxorubicin, streptozocin-fluorouracil or chlorozotocin in the treatment of advanced islet-cell carcinoma. N Engl J Med 1992;326:519–23.
4. Nikou GC, Toubanakis C, Nikolaou P, et al. VIPomas: an update in diagnosis and management in a series of 11 patients. Hepatogastroenterology 2005;52:1259–65.
5. Kaltsas GA, Besser GM, Grossman AB. The diagnosis and medical management of advanced neuroendocrine tumors. Endocr Rev 2004;25:458–511.
6. Tomassetti P, Migliori M, Lalli S, et al. Epidemiology, clinical features and diagnosis of gastroenteropancreatic endocrine tumours. Ann Oncol 2001; 12(Suppl 2):S95–S99.
7. Akerstrom G, Hessman O, Hellman P, Skogseid B. Pancreatic tumours as part of the MEN-1 syndrome. Best Pract Res Clin Gastroenterol 2005;19:819–30.
8. Memon MA, Nelson H. Gastrointestinal carcinoid tumors: current management strategies. Dis Colon Rectum 1997;40:1101–18.
9. Rindi G, Villanacci V, Ubiali A, Scarpa A. Endocrine tumors of the digestive tract and pancreas: histogenesis, diagnosis and molecular basis. Expert Rev

Mol Diagn 2001;1:323–3.
10. Kloppel G. Classification of neuroendocrine tumors. Verh Dtsch Ges Pathol 1997;81:111–7.
11. Krejs GJ. VIPoma syndrome. Am J Med 1987;82:37–48.
12. Grier JF. WDHA (watery diarrhea, hypokalemia, achlorhydria) syndrome: clinical features, diagnosis, and treatment. South Med J 1995;88:22–4.
13. Mekhjian HS, O'Dorisio TM. VIPoma syndrome. Semin Oncol 1987;14:282–91.
14. Wick MR, Graeme-Cook FM. Pancreatic neuroendocrine neoplasms: a current summary of diagnostic, prognostic, and differential diagnostic information. Am J Clin Pathol 2001;115 Suppl:S28–45.
15. Moertel CG, Johnson CM, McKusick MA, et al. The management of patients with advanced carcinoid tumors and islet cell carcinomas. Ann Intern Med 1994;120:302–9.
16. Gumbs AA, Moore PS, Falconi M, et al. Review of the clinical, histological, and molecular aspects of pancreatic endocrine neoplasms. J Surg Oncol 2002;81:45–54.
17. Owen NJ, Sohaib SA, Peppercorn PD, et al. MRI of pancreatic neuroendocrine tumours. Br J Radiol 2001;74:968–73.
18. Rubello D, Rufini V, De Carlo E, et al. [New perspectives in diagnosis and therapy of endocrine gastroenteropancreatic (GEP) tumors with somatostatin analogues.] [Article in Italian.] Minerva Endocrinol 2003;28:259–96.
19. Balon HR, Goldsmith SJ, Siegel BA, et al; Society of Nuclear Medicine. Procedure guidelines for somatostatin receptor scintigraphy with ^{111}In-pentetreotide. J Nucl Med 2001;42:1134–8.
20. Solcia E, Kloppel G, Sobin LH. Histological typing of endocrine tumours. World Health Organization International Histological Classification of Tumours. 2nd ed. Heidelberg: Springer; 2000.
21. Rindi G, Villanacci V, Ubiali A. Biological and molecular aspects of gastroenteropancreatic neuroendocrine tumors. Digestion 2000;62:19–26.
22. Oberg K, Eriksson B. Endocrine tumours of the pancreas. Best Pract Res Clin Gastroenterol 2005;19:753–81.
23. Nikou GC, Lygidakis NJ, Toubanakis C, et al. Current diagnosis and treatment of gastrointestinal carcinoids in a series of 101 patients: the significance of serum chromogranin-A, somatostatin receptor scintigraphy and somatostatin analogues. Hepatogastroenterology 2005;52:731–41.
24. Schonfeld WH, Elkin EP, Woltering EA, et al. The cost-effectiveness of octreotide acetate in the treatment of carcinoid syndrome and VIPoma. Int J Technol Assess Health Care 1998;14:514–25.
25. Nguyen HN, Backes B, Lammert F, et al. Long-term survival after diagnosis of hepatic metastatic VIPoma: report of two cases with disparate courses and review of therapeutic options. Dig Dis Sci 1999;44:1148–55.
26. Major P, Figueredo A, Tandan V, et al. The role of octreotide in the management of patients with cancer. Systemic Treatment Disease Site Group. Toronto (ON): Cancer Care Ontario (CCO); 2004. Available at www.guideline.gov/summary/summary.aspx?ss=15&doc_id=6312&nbr=4042. Accessed 20 May 2008.
27. Wymenga AN, Eriksson B, Salmela PI, et al. Efficacy and safety of prolonged release lanreotide in patients with gastrointestinal neuroendocrine tumors and hormone-related symptoms. J Clin Oncol 1999;17:1111.
28. Rougier P, Mitry E. Chemotherapy in the treatment of neuroendocrine malignant tumors. Digestion 2000;62 Suppl 1:73–8.
29. O'Toole D, Ducreux M, Bommelaer G, et al. Treatment of carcinoid syndrome: a prospective crossover evaluation of lanreotide versus octreotide in terms of efficacy, patient acceptability, and tolerance. Cancer 2000;88:770–6.
30. Scheffold N, Arnold R, Cyran J. [Metastasizing pancreatic vipoma. Its diagnosis and therapy with the somatostatin analog octreotide.] [Article in German.] Dtsch Med Wochenschr 1995;120:1463–7.
31. Venook AP. Embolization and chemoembolization therapy for neuroendocrine tumors. Curr Opin Oncol 1999;11:38–41.

Copyright 2008 by Turner White Communications Inc., Wayne, PA. All rights reserved.