Wolff-Parkinson-White Syndrome: An Uncommon Cause of Palpitations

David E. Begleiter, MD
Joel Gernsheimer, MD
Muhammad Waseem, MD

Palpitations are a common presenting symptom in the emergency department (ED). Typically, the cause of palpitations is benign, especially in otherwise young, healthy patients. For example, premature atrial contractions, infrequent premature ventricular contractions, and sinus tachycardia may be caused by anxiety, stress, and excessive intake of stimulants such as caffeine. However, clinicians must be aware of and alert for more serious underlying conditions. In this article, we report the case of a young man who presented with palpitations and a wide complex tachycardia on electrocardiogram (ECG). The patient's symptoms were caused by atrial fibrillation with a rapid ventricular response due to underlying Wolff-Parkinson-White (WPW) syndrome.

WPW syndrome, which is classified among the paroxysmal supraventricular tachycardias (PSVTs), is a relatively uncommon cardiac conduction disorder that occasionally may cause early excitation (preexcitation) of the ventricles due to antegrade atrioventricular (AV) conduction through an accessory pathway. Patients with WPW syndrome may present with preexcited atrial fibrillation. ECG tracings of patients who have WPW syndrome typically reveal a narrow QRS complex, but WPW syndrome associated with preexcited atrial fibrillation may produce a wide QRS complex on ECG. These ECG findings are commonly confused with other causes of wide QRS complex tachycardia, such as ventricular tachycardia.

Atrial fibrillation can lead to congestive heart failure (CHF), cardiogenic shock, and even sudden cardiac death unless it is correctly and expeditiously diagnosed and treated. In patients with WPW syndrome, prompt recognition of the underlying mechanism is essential so that appropriate therapy targeting the accessory pathway can be initiated. This article highlights the challenges of diagnosing preexcited atrial fibrillation and reviews its acute management as well as discusses important causes of PSVT.

CASE PRESENTATION

Initial Presentation and History

A 25-year-old man presented to the ED with shortness of breath and palpitations. He stated that he first noticed the palpitations and difficulty in breathing when he was taking a shower about 1 hour prior to his arrival at the ED. He had no fever, chest pain, nausea, vomiting, or diaphoresis. He also denied any recent chest trauma. The patient reported a hospital admission for an episode of "rapid heart beat" that occurred 4 years ago. At that time, he was discharged against medical advice. Since then, he had no other episodes of palpitations until the current presentation. He was not taking any medications and denied any other medical problems. His social history was significant for a 5 pack-year tobacco history, occasional alcohol use, and no use of any illicit drugs.

Physical Examination and ECG Monitoring

On physical examination, the patient was uncomfortable and was clutching his chest. Pulse was well over 200 bpm but still palpable. Blood pressure was 119/58 mm Hg and respiratory rate was 20 breaths/min. On auscultation, his chest was clear and air entry was equal on both sides. There was no murmur. The remainder of his physical examination was unremarkable. A 12-lead ECG showed a heart rate of 240 bpm with wide QRS complexes (**Figure 1**). The working diagnosis at this point was PSVT with aberrant conduction.

At the time of submission, Dr. Begleiter was a senior resident, Department of Emergency Medicine, Lincoln Medical and Mental Health Center, Bronx, NY. He is now a fellow in emergency ultrasound, Jacobi Medical Center, Bronx, NY. Dr. Gernsheimer is a clinical associate professor, Weill Medical College of Cornell University, New York, NY; and an attending physician, Department of Emergency Medicine, Lincoln Medical and Mental Health Center. Dr. Waseem is a clinical assistant professor, Weill Medical College of Cornell University; and an attending physician, Department of Emergency Medicine, Lincoln Medical and Mental Health Center.

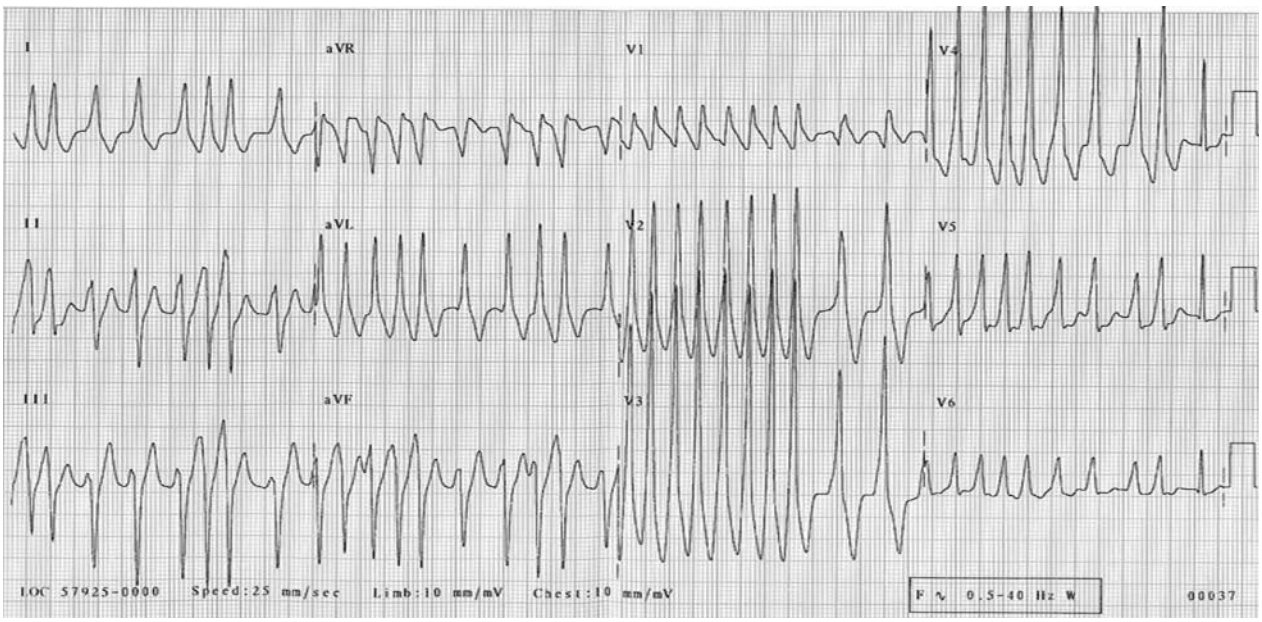

Figure 1. A 12-lead electrocardiogram showing a heart rate of 240 bpm and wide QRS complex tachycardia.

Diagnosis and Management

The patient remained alert and awake with stable blood pressure. Carotid sinus massage did not affect his ventricular rate, making the diagnosis of PSVT less likely but not completely ruling out this possibility. As PSVT with aberrant conduction still appeared to be the most likely etiology, rapidly delivered intravenous (IV) adenosine was administered initially at 6 mg and then 12 mg in an effort to convert the rhythm, but it did not slow the heart rate. This failure to respond to adenosine made the diagnosis of PSVT much less likely and made other causes of wide complex tachycardia, such as ventricular tachycardia, more likely. The patient was then given an IV dose of 150 mg amiodarone over 10 minutes followed by an infusion of amiodarone at 1 mg/min, which slowed his ventricular rate somewhat but did not convert his rhythm. He was admitted to the intensive care unit.

Because the patient became hypotensive with signs of poor perfusion, he underwent synchronized cardioversion, which successfully converted his tachydysrhythmia to sinus rhythm. Repeat ECG following cardioversion showed a shortened PR interval with a distinct slurring of the QRS complex (**Figure 2**), which is diagnostic for the WPW syndrome. The original ECG (Figure 1) was subsequently reviewed and interpreted as a wide complex preexcited atrial fibrillation due to underlying WPW syndrome. The patient was started on oral amiodarone therapy (200 mg/day) and was closely monitored for 2 days. He did not experience any recurrence of dysrhythmia while hospitalized. On discharge, the patient was referred to a cardiology clinic, where he underwent successful ablation therapy. Subsequent follow-up revealed that the patient was doing well without any recurrence of dysrhythmia.

DISCUSSION

The case patient's ECG shows a rapid, wide QRS complex tachycardia (Figure 1), which is defined as tachycardia having a QRS duration greater than 120 msec (0.12 sec). Wide complex tachycardias are often caused by ventricular tachycardia and should usually be considered as such until proven otherwise.[1,2] As this case illustrates, other causes of wide complex tachycardia that must be considered in the differential diagnosis are PSVT with underlying bundle branch block or aberrancy and preexcitation syndromes with antegrade conduction through an accessory pathway, such as WPW syndrome.[3–5] Distinguishing among these conditions is important because an incorrect diagnosis can lead to inappropriate treatment and poor outcome.[6,7]

The typical ECG pattern of preexcited atrial fibrillation can be confused with ventricular tachycardia as they both have very fast ventricular rates and wide QRS complexes. A clue to the correct diagnosis in this patient's ECG (Figure 1) is the extreme irregularity of the QRS complex, making ventricular tachycardia and other PSVTs unlikely diagnoses. Rarely, ventricular tachycardia can be irregular (eg, polymorphous

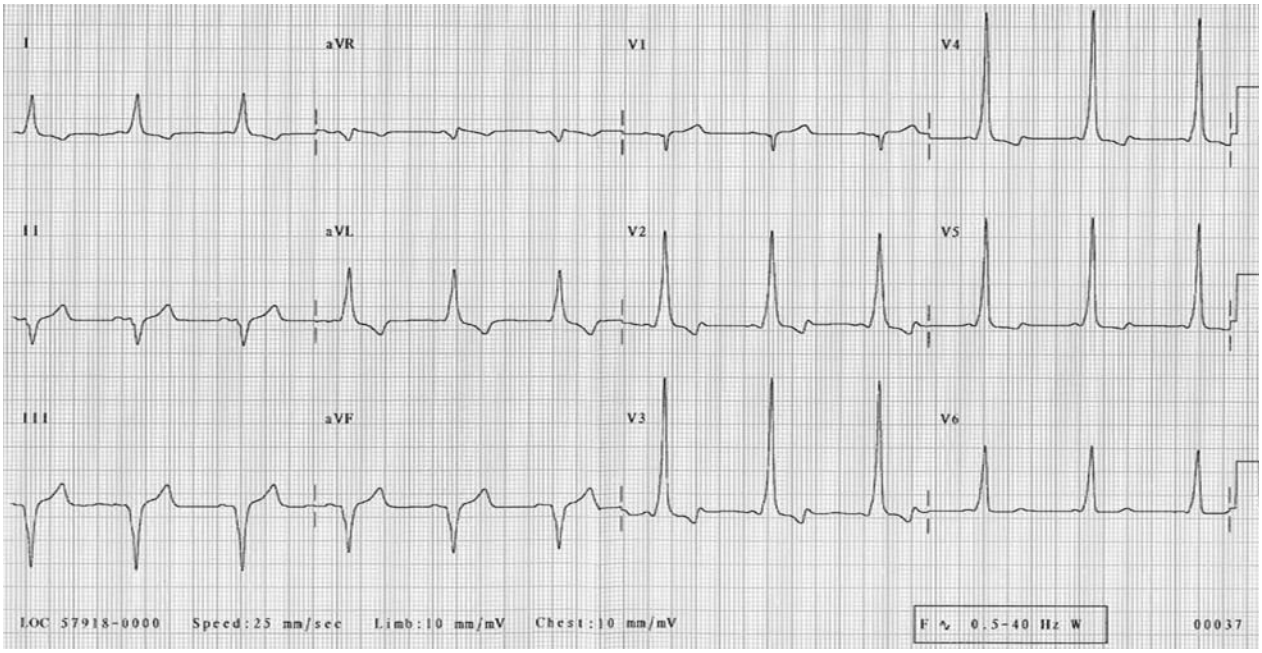

Figure 2. A postconversion electrocardiogram showing slurring of the wide QRS complex and shortened PR interval consistent with the diagnosis of Wolf-Parkinson-White syndrome.

ventricular tachycardia); however, when these rhythms are sustained, the patient rapidly deteriorates and requires defibrillation. It is important to note that irregularity in the rhythm can be difficult to detect at extremely rapid heart rates. In this case, the ECG obtained after the patient underwent cardioversion (Figure 2) revealed evidence of a preexcitation syndrome (short PR interval and a slurred upstroke of the initial portion of the wide QRS complex, the delta wave).

This patient's heart rate also suggests that ventricular tachycardia is less likely. Some of the cycles in this patient's ECG tracing show a heart rate that exceeds 300 bpm, while the heart rate in ventricular tachycardia is typically between 140 and 200 bpm. This tracing is therefore more likely due to antegrade accessory pathway conduction. Although there are other etiologies besides WPW syndrome that can cause extremely rapid tachycardia (eg, Lown-Ganong-Levine syndrome, polymorphous ventricular tachycardia), any tachycardia in an adult greater than 200 bpm with a wide QRS complex should raise the possibility of a preexcitation syndrome with antegrade conduction down an accessory pathway.

WOLFF-PARKINSON-WHITE SYNDROME

The normal conduction system of the heart confines movement of electrical impulses from the atrium to the ventricles to a single pathway through the AV node. The AV node limits the electrical impulses that are conducted to the ventricles and slows down individual impulses, resulting in a delay in activation between the upper and lower chambers (as manifested electrocardiographically by the PR interval). Patients with WPW syndrome have an accessory electrical conduction pathway that directly connects the atria and ventricles, bypassing the normal route of conduction through the AV node. Accessory pathways usually do not have a significant conduction delay, and an impulse conducted through such a pathway will activate the ventricle earlier than an impulse conducted through the AV node.[8] Rapid transmission across an accessory pathway during atrial fibrillation may result in ventricular fibrillation and sudden death.

WPW syndrome is considered to be the classic form of ventricular preexcitation. The prevalence of the WPW ECG tracing is 0.1 to 3 cases per 1000 persons, and it has a male predominance.[8] The clinical hallmark of WPW syndrome is paroxysmal tachycardia at a rate of 150 to 300 bpm; this rate is the direct result of the loss of normal AV node conduction restraint. Patients often may report associated symptoms, such as palpitations, shortness of breath, dizziness, and chest pain. Although WPW syndrome usually presents with a narrow QRS complex, the classic ECG pattern seen in WPW syndrome with preexcitation is a short PR interval (< 0.12 sec), a delta wave (slurred upstroke of the initial portion of the QRS complex), and a wide QRS complex (≥ 0.12 sec; **Table**).[9] The

Table. Electrocardiogram Criteria for Wolff-Parkinson-White Syndrome

Short PR interval (< 0.12 sec)
Slurred slow rising onset of QRS complex (delta wave)
Prolonged QRS complex (> 0.12 sec)

Data from Al-Khatib SM, Pritchett EL. Clinical features of Wolff-Parkinson-White syndrome. Am Heart J 1999;138(3 Pt 1):403–13.

short PR interval reflects the decreased time between activation of the atria (P wave) and activation of the ventricles (QRS complex). Similarly, the delta wave occurs because of earlier activation of the ventricular myocardium by the impulse conducted through the accessory pathway followed by later activation by the impulse conducted through the AV node. The delta wave seen in the WPW syndrome may masquerade as an inferior wall myocardial infarction (MI) (seen as a QS pattern in leads II, III, and aVF) or as a posterior wall MI (seen as a large R wave in leads V_1–V_3). Apparent wide complex tachycardia after ST-segment elevation MI has been reported.[10] The short PR interval is evident in most leads, whereas the delta wave is usually best seen in the precordial leads. It is important to recognize this WPW pattern on ECG because the symptomatic patient with WPW syndrome has an increased risk of atrial fibrillation and a small but significant risk of sudden cardiac death.[11–13]

Forms of Paroxysmal Supraventricular Tachycardia

The WPW syndrome may remain undetected until it manifests as PSVT.[14] The following section reviews tachycardias that may occur with or be confused with WPW syndrome. They can be characterized by whether the AV node, an accessory pathway, or both are involved in perpetuating the tachycardia.

Atrioventricular nodal reentrant tachycardia (AVNRT). In AVNRT, the electrical impulse is conducted into the ventricle via the normal conduction system and is perpetuated by "reentering" the conduction system via pathways in the AV node or perinodal atrial tissue. This type of reentry tachycardia is considered to be the most common form of PSVT, accounting for approximately half of the PSVTs that are referred for diagnostic electrophysiologic studies.[15] AVNRT is not a form of WPW syndrome as an accessory pathway is not required for the tachycardia to occur, although AVNRT may coexist with WPW syndrome. In AVNRT, the rhythm is very fast (150–220 bpm) and regular, and the QRS complex is narrow unless an underlying bundle branch block or aberrancy is present.

Atrioventricular reentrant or reciprocating tachycardia (AVRT). AVRT is a reentrant tachycardia that occurs in WPW syndrome. In AVRT, the normal AV node and an accessory pathway along with the atria and ventricles form a circuit that allows reentry of impulses. There are 2 forms of AVRT: orthodromic and antidromic. In orthodromic AVRT, the atrial impulse is conducted to the ventricles via the normal AV node route (ie, orthodromic conduction) and is conducted retrogradely via an accessory pathway; this retrograde conduction allows the impulse to reenter the conduction system and perpetuate the tachycardia.

Orthodromic conduction occurs in most symptomatic patients (~ 90%) with WPW syndrome.[8,15,16] The rate in orthodromic AVRT is very fast (150 to > 250 bpm), the rhythm is regular, and the QRS complex will usually be narrow. Although the classic finding for diagnosing WPW syndrome is a short PR interval and delta wave with a wide QRS complex, the most common dysrhythmia is a narrow QRS complex ventricular tachycardia. Usually, it is not possible to differentiate PSVT caused by AVNRT from PSVT caused by orthodromic AVRT because they are both rapid, narrow QRS complex tachycardias. Clues that a PSVT is caused by orthodromic AVRT are ST-segment depression and a beat-to-beat oscillation in QRS amplitude. When the normal rhythm is restored, the short PR interval and delta wave may be seen. However, it is not necessary to distinguish PSVT due to AVNRT from PSVT due to orthodromic AVRT, as they are both treated with maneuvers or drugs that block the AV node.

In AVRT with antidromic conduction, the accessory pathway conducts the impulse antegradely, resulting in preexcitation of the ventricles, which is followed by retrograde conduction through the AV node. The QRS complex in antidromic AVRT is wide, which can make this form of AVRT difficult to distinguish from ventricular tachycardia and preexcited atrial fibrillation due to antegrade conduction through an accessory pathway. AVRT can be distinguished from preexcited atrial fibrillation by its rhythm, which is usually regular.

Preexcited atrial fibrillation. Atrial fibrillation can also occur in WPW syndrome and result in an extremely fast, very irregular wide complex tachycardia.[17,18] Atrial fibrillation is seen in approximately 10% to 30% of patients with WPW syndrome, which is higher than the prevalence of atrial fibrillation in the general population.[19,20] In patients with WPW syndrome, the accessory pathway provides a direct route for conduction of the atrial impulse to the ventricles, resulting in ventricular preexcitation. The refractory period of the accessory pathway determines the ventricular rate, and a rate as high as 300 bpm may occur in WPW patients with atrial

fibrillation and antegrade conduction through the accessory pathway.[21,22] Rapid transmission of impulses across an accessory pathway during atrial fibrillation may result in CHF, hypotension, ventricular fibrillation, and sudden cardiac death.[23]

The characteristic ECG findings of patients with preexcited atrial fibrillation are an irregular rhythm, usually with a very rapid ventricular rate, a bizarre and changing wide QRS morphology, and QRS complexes often appearing to be "clumped." These findings help distinguish this rhythm from other causes of a wide complex tachycardia. In cases of an extremely rapid ventricular rate, it sometimes may be difficult to make an exact diagnosis of a wide complex tachycardia, and consultation with a cardiologist may be needed.

Acute Treatment of WPW Syndrome

Acute treatment of patients with WPW syndrome presenting with a tachydysrhythmia differs depending upon the patient's clinical presentation. Unstable patients, regardless of the QRS duration or regularity, should receive immediate synchronized cardioversion. If time and the patient's clinical condition allow it, the patient may be sedated first. Electrical cardioversion also should be used if the patient is not responding to pharmacologic therapy and is showing any signs of clinical deterioration.

Stable patients who present with PSVT with a narrow QRS complex, due to either AVNRT or orthodromic AVRT, should be treated with vagal maneuvers initially. If these maneuvers fail, drugs that block the AV node should be administered. Adenosine, calcium channel blockers, β-adrenergic blockers, procainamide, and amiodarone are all suitable agents for treatment of these dysrhythmias. Although uncommon, antidromic AVRT should be treated with procainamide or amiodarone, as opposed to adenosine. Should the patient become hemodynamically unstable, synchronized cardioversion should be performed.[24,25]

Stable patients who present with a wide QRS complex tachycardia caused by preexcited atrial fibrillation must be monitored very carefully due to the increased risk of sudden death. Pharmacologic agents that block the AV node should not be used in patients with preexcited atrial fibrillation because the AV node is not causing or perpetuating the dysrhythmia, and these agents may actually worsen the patient's condition. Digoxin should not be used as it shortens the refractory period of the accessory pathway and can increase the ventricular rate and induce ventricular fibrillation.[26,27] Adenosine is also not considered a suitable agent in this situation, as it does not convert the atrial fibrillation, and deaths associated with its use in atrial flutter have been reported.[28,29] Administration of IV adenosine also can result in provocation of orthodromic AVRT.[30] Therefore, all AV nodal blocking drugs (especially calcium channel and β-blockers) are contraindicated in patients with preexcited atrial fibrillation.[31]

Acute treatment of preexcited atrial fibrillation requires a rapid acting drug that can be given intravenously and can slow conduction in the accessory pathway. Procainamide is considered to be the drug of choice for acute therapy of WPW syndrome complicated by preexcited atrial fibrillation.[24,25,32] However, procainamide has the potential for increasing the QT interval, thus causing torsades de pointes.[33] Another problem with procainamide is that it is a negative inotrope and can worsen CHF. Ibutilide also has been used successfully for treating preexcited atrial fibrillation.[34,35] However, ibutilide can cause polymorphic ventricular tachycardia and thus induce torsades de pointes.[36] Patients with impaired left ventricular function are at higher risk for life-threatening ventricular dysrhythmias when this drug is used.

All patients who present with WPW syndrome should be referred to cardiology for definitive treatment with radiofrequency catheter or surgical ablation therapy.[37] Until definitive treatment can be undertaken, these patients will require chronic pharmacologic therapy based on electrophysiologic testing. This drug therapy, which may include oral amiodarone, procainamide, or β-blockers, should be initiated by a cardiologist based on electrophysiologic studies.

CONCLUSION

Atrial fibrillation with a very rapid ventricular rate may be life threatening in patients with WPW syndrome. When confronted with a wide QRS tachycardia, physicians should always be concerned that this might represent preexcited tachycardia. A wide-complex irregular tachycardia at a rate of 250 bpm or greater is highly suggestive of atrial fibrillation and the WPW syndrome. Early recognition and correct treatment allows rapid restoration of normal sinus rhythm and may decrease morbidity and mortality. **HP**

Corresponding author: Joel Genrsheimer, MD, Lincoln Medical and Mental Health Center, 300 East 149th Street, Bronx, NY 10451; gernsh@aol.com.

REFERENCES

1. Brembilla-Perrot B, Beurrier D, Houriez P, et al. Wide QRS complex tachycardia. Rapid method of prognostic evaluation. Int J Cardiol 2004;97:83–8.

2. Reising S, Kusumoto F, Goldschlager N. Life-threatening arrhythmias in the intensive care unit. J Intensive Care Med 2007;22:3–13.
3. Hollowell H, Mattu A, Perron AD, et al. Wide-complex tachycardia: beyond the traditional differential diagnosis of ventricular tachycardia vs supraventricular tachycardia with aberrant conduction. Am J Emerg Med 2005;23: 876–89.
4. Gupta AK, Thakur RK. Wide QRS complex tachycardias. Med Clin North Am 2001;85:245–66, ix–x.
5. Nelson JA, Knowlton KU, Harrigan R, et al. Electrocardiographic manifestations: wide complex tachycardia due to accessory pathway. J Emerg Med 2003;24:295–301.
6. Buxton AE, Marchlinski FE, Doherty JU, et al. Hazards of intravenous verapamil for sustained ventricular tachycardia. Am J Cardiol 1987;59:1107–10.
7. Stewart RB, Bardy GH, Greene HL. Wide complex tachycardia: misdiagnosis and outcome after emergent therapy. Ann Intern Med 1986;104:766–71.
8. Rosner MH, Brady WJ Jr, Kefer MP, Martin ML. Electrocardiography in the patient with Wolff-Parkinson-White syndrome: diagnostic and initial therapeutic issues. Am J Emerg Med 1999;17:705–14.
9. Al-Khatib SM, Pritchett EL. Clinical features of Wolff-Parkinson-White syndrome. Am Heart J 1999;138(3 Pt 1): 403–13.
10. Barlotta KS, Holstege C, Brady WJ, Mattu A. Apparent wide complex tachycardia after ventricular fibrillation cardiac arrest in patients with ST-segment elevation myocardial infarction. Am J Emerg Med 2006;24:362–7.
11. Redfearn DP, Krahn AD, Skanes AC, et al. Use of medications in Wolff-Parkinson-White syndrome. Expert Opin Pharmacother 2005;6:955–63.
12. LeLorier P, Klein GJ, Krahn A, et al. Should patients with asymptomatic Wolff-Parkinson-White pattern undergo a catheter ablation? Curr Cardiol Rep 2001;3:301–4.
13. Brembilla-Perrot B. Electrophysiological evaluation of Wolff-Parkinson-White syndrome. Indian Pacing Electrophysiol J 2002;2:143–52.
14. Zimmers T, Patel H, Stephani R. Cases in electrocardiography. Am J Emerg Med 2004;22:118–9.
15. Ganz LI, Friedman PL. Supraventricular tachycardia. N Engl J Med 1995;332:162–73.
16. Hongo RH, Goldschlager N. Tachycardia. In: Rakel RE, Bope ET, editors. Conn's current therapy. 58th ed. Saunders; 2006.
17. Peinado R, Merino JL, Gnoatto M, Arias MA. Atrial fibrillation triggered by postinfarction ventricular premature beats in a patient with Wolff-Parkinson-White syndrome. Europace 2005;7:221–4.
18. Krahn AD, Klein GJ, Skanes AC, Yee R. Atrial fibrillation in patients with Wolff-Parkinson-White syndrome [editorial]. J Cardiovasc Electrophysiol 2002;13:230.
19. Szumowski L, Walczak F, Urbanek P, et al. [Risk factors of atrial fibrillation in patients with Wolff-Parkinson-White syndrome.] [Article in English, Polish.] Kardiol Pol 2004;60:206–17.
20. Robinson K, Rowland E, Krikler DM. Wolff-Parkinson-White syndrome: atrial fibrillation as the presenting arrhythmia. Br Heart J 1988;59:578–80.
21. Grant RP, Tomlinson FB, Van Buren JK. Ventricular activation in the pre-excitation syndrome (Wolff-Parkinson-White). Circulation 1958;18:355–66.
22. Exner DV, Muzyka T, Gillis AM. Proarrhythmia in patients with the Wolff-Parkinson-White syndrome after standard doses of intravenous adenosine. Ann Intern Med 1995;122:351–2.
23. Montoya PT, Brugada P, Smeets J, et al. Ventricular fibrillation in the Wolff-Parkinson-White syndrome. Eur Heart J 1991;12:144–50.
24. Testa A, Ojetti V, Migneco A, et al. Use of amiodarone in emergency. Eur Rev Med Pharmacol Sci 2005;9:183–90.
25. Sarkozy A, Dorian P. Advances in the acute pharmacologic management of cardiac arrhythmias. Curr Cardiol Rep 2003;5:387–94.
26. Gheorghiade M, van Veldhuisen DJ, Colucci WS. Contemporary use of digoxin in the management of cardiovascular disorders. Circulation 2006;113:2556–64.
27. Khan IA, Nair CK, Singh N, et al. Acute ventricular rate control in atrial fibrillation and atrial flutter. Int J Cardiol 2004;97:7–13
28. Nagappan R, Arora S, Winter C. Potential dangers of the Valsalva maneuver and adenosine in paroxysmal supraventricular tachycardia—beware preexcitation. Crit Care Resusc 2002;4:107–11.
29. Brodsky MA, Hwang C, Hunter D, et al. Life-threatening alterations in heart rate after the use of adenosine in atrial flutter. Am Heart J 1995;130(3 Pt 1):564–71.
30. Dougherty AH, Gilman JK, Wiggins S, et al. Provocation of atrioventricular reentry tachycardia: a paradoxical effect of adenosine. Pacing Clin Electrophysiol 1993;16:8–12.
31. Foo D, Ng KS. Electrocardiographical case. A case of wide complex tachycardia. Singapore Med J 2005;46:245–8.
32. Chew HC, Lim SH. Broad complex atrial fibrillation. Am J Emerg Med 2007;25:459–63.
33. Yap YG, Camm AJ. Drug induced QT prolongation and torsades de pointes. Heart 2003;89:1363–72.
34. Varriale P, Sedighi A, Mirzaietehrane M. Bobtailed for termination of atrial fibrillation in the Wolff-Parkinson-White syndrome. Pacing Clin Electrophysiol 1999;22:1267–9.
35. Glatter KA, Dorostkar PC, Yang Y, et al. Electrophysiological effects of ibutilide in patients with accessory pathways. Circulation 2001;104:1933–9.
36. Gowda RM, Punukollu G, Khan IA, et al. Ibutilide-induced long QT syndrome and torsades de pointes. Am J Ther 2002;9:527–9.
37. Deam AG, Burton ME, Walter PF, Langberg JJ. Wide complex tachycardia due to automaticity in an accessory pathway. Pacing Clin Electrophysiol 1995;18:2106–8.

Copyright 2007 by Turner White Communications Inc., Wayne, PA. All rights reserved.