A Blistering Eruption in an Immunocompromised Man

Katherine T. Steele, BA
Markus Boos, MD, PhD
Xiaowei Xu, MD, PhD
Carrie L. Kovarik, MD
Carmela C. Vittorio, MD
Karolyn A. Wanat, MD

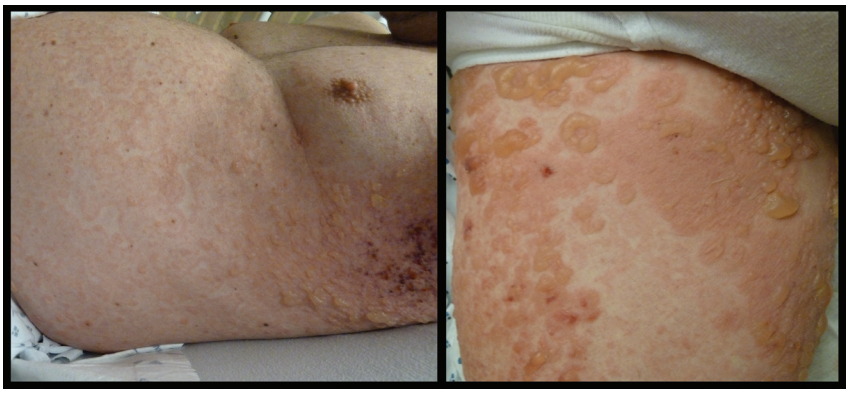

Figure 1. Erythematous annular thin papules and plaques with overlying tense and flaccid bullae. Note the circular arrangement of some bullae.

CASE PRESENTATION

Initial Presentation and History

A 51-year-old man with a history of thyroid cancer and stage IV peripheral T-cell lymphoma presented emergently to the hospital with a 1-week history of a diffuse, painful eruption. He had received 6 cycles of chemotherapy and 7 weeks prior had received an autologous stem cell transplant as treatment for his lymphoma and was started on fluconazole and acyclovir at that time. Three weeks prior to presentation, trimethoprim-sulfamethoxazole (TMP-SMX) 3 times weekly was added as *Pneumocystis jiroveci* prophylaxis. The eruption began on his dorsal hands and knees, then rapidly spread to involve his trunk and extremities with subsequent bullae formation. TMP-SMX was discontinued and prednisone was initiated, but he continued to have new areas of involvement, including his eyes and oral mucosa, prompting him to seek medical attention.

Physical Examination

Physical examination was notable for coalescing, erythematous, annular papules and plaques of the torso and extremities with tense and flaccid bullae (**Figure 1**), as well as painful vesicles and erosions. Over 50% of the total body surface area was involved. There was confluent erythema of his palms and soles. The mucosal exam was notable for vesicles and erosions of the tongue and hard palate. The patient also had erythema of his urethral meatus and left scleral injection with crusting.

Biopsy and Laboratory Testing

A biopsy of perilesional skin was performed (**Figure 2**). Comprehensive metabolic panel, complete blood count (CBC), and coagulation studies were within normal limits.

WHAT IS YOUR DIAGNOSIS?

(A) Bullous pemphigoid
(B) Bullous systemic lupus erythematosus
(C) Dermatitis herpetiformis

From the Department of Dermatology and the Department of Pathology and Laboratory Medicine, Perelman School of Medicine at the University of Pennsylvania, Philadelphia, PA.

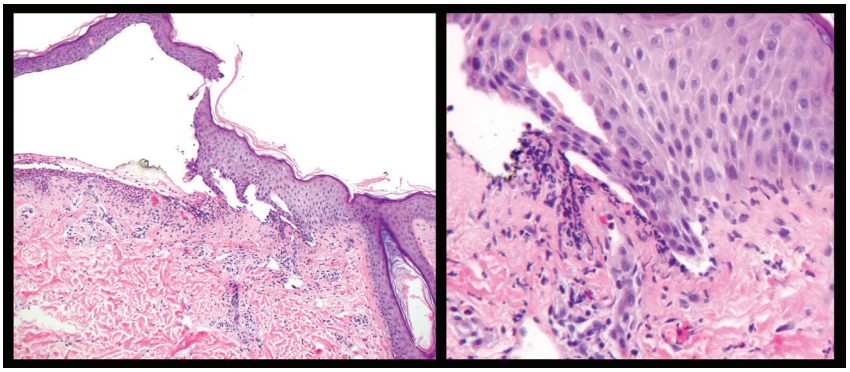

Figure 2. Hematoxylin and eosin staining at low (left panel) and high (right panel) magnification demonstrates a subepidermal bullae with a predominantly neutrophilic infiltrate along the dermal-epidermal junction.

(D) Linear immunoglobulin A bullous dermatosis
(E) Toxic epidermal necrolysis

ANSWER

The correct answer is (D), Linear immunoglobulin A bullous dermatosis (LABD).

DISCUSSION

The clinical presentations of the blistering disorders listed above may have some overlapping features, and therefore an accurate diagnosis requires histopathologic and immunologic confirmation. In the case presented, the biopsy of perilesional skin demonstrated subepidermal bullae with a predominantly neutrophilic infiltrate along the dermal-epidermal junction (Figure 2). Direct immunofluorescence (DIF) evaluation of perilesional skin demonstrated strong linear deposition of immunoglobulin (Ig) A with weak IgG at the dermal-epidermal junction, and minimal or no evidence of IgM, C3, or fibrinogen. These findings are consistent with LABD.[1]

Bullous pemphigoid is a blistering disorder that typically occurs spontaneously in middle-aged or elderly patients, and also can be drug-induced. Bullous pemphigoid is clinically characterized by tense vesicles and bullae and urticarial plaques arising in the groin and axilla, with oral mucosal involvement occurring in approximately one-third of cases. Histopathologically, bullous pemphigoid will often have eosinophilic predominance in the inflammatory infiltrate and DIF will demonstrate linear IgG and C3 staining as opposed to strong linear IgA staining.[2]

Given the widespread blistering of the body surface area (more than 30%) and the mucous membrane involvement, toxic epidermal necrolysis (TEN) was also in the differential diagnosis at the initial presentation. However, TEN is typically associated with a prodrome of fever and malaise and full epidermal necrosis on histopathologic evaluation, with negative DIF findings.[2]

Dermatitis herpetiformis, which has a strong association with celiac disease, often presents with pruritic papules and clustered vesicles emerging in a symmetric distribution on extensor surfaces with sparing of the palms and soles. The vesiculobullous eruption seen in bullous systemic lupus erythematosus (BSLE) may consist of erythematous plaques that evolve into either large, tense bullae, similar to bullous pemphigoid, or small, clustered vesicles as seen in dermatitis herpetiformis. BSLE occurs only in patients who meet criteria for diagnosis of systemic lupus erythematosus (SLE). LABD, dermatitis herpetiformis, and BSLE may all have a predominately neutrophilic infiltrate along the dermal-epidermal junction but differ in immunofluorescence staining. LABD will have strong linear IgA staining. Dermatitis herpetiformis will have granular IgA staining, and BSLE may have linear or granular staining with multiple antibodies, including IgG and C3 in all reported cases and IgM and IgA in others.[2] In BSLE, the clinical presentation and stigmata of lupus erythematosus and positive serologic testing for antinuclear antibody (ANA) also would confirm the diagnosis. Thus, direct and indirect immunofluorescence studies are key to differentiating these autoimmune blistering disorders.

CLINICAL COURSE OF THE PATIENT

This patient developed a LABD eruption within 3 weeks of initiating TMP-SMX that resolved after discontinuing the medication, making TMP-SMX–induced LABD the most likely diagnosis. However, a surveillance PET scan performed 10 weeks after his diagnosis of LABD showed several PET-avid lymph nodes suspicious for recurrence of his peripheral T cell lymphoma, raising the possibility that LABD also could represent a paraneoplastic phenomenon. In the absence of re-

challenge, we cannot prove that this patient's condition was induced by TMP-SMX with certainty.

Initially, TMP-SMX, fluconazole, and acyclovir were discontinued, and oral prednisone was started in conjunction with topical triamcinolone ointment and petrolatum. Artificial tears and lubricant eye ointment were used for ocular involvement. The patient was maintained on intravenous fluids for hydration and received intravenous pain control. After confirmation of the diagnosis and a normal glucose-6-phosphate dehydrogenase (G6PD) screening result, dapsone was added to treat his LABD and as *P. jiroveci* prophylaxis. He has not had recurrence of his LABD since he started dapsone therapy.

LINEAR IGA BULLOUS DERMATOSIS

LABD is a rare subepidermal blistering disorder caused by IgA autoantibodies directed against various target antigens in the lamina lucida of the basement membrane zone of skin and mucosa. There are 2 peaks in the age of onset: a childhood form, chronic bullous disease of childhood, typically occurs between 6 months and 6 years of age, and an adult form occurs at a mean age of 60 to 65 years.[1,3] Clinically, LABD is often characterized by a vesiculobullous eruption arising on normal skin or on an erythematous base with new vesicles and bullae appearing at the margins of older lesions, resulting in a "cluster of jewels" appearance.[1,4] Targetoid or urticarial plaques may also be seen.[3,4] Lesions usually appear on extensor surfaces as well as the trunk, buttocks, and perioral region. Mucous membrane involvement occurs, most commonly affecting the eyes and oral mucosa.[5,6] Since LABD may clinically resemble other blistering disorders, histopathologic and immunologic examination, including both direct and indirect immunofluorescence studies, are required for definitive diagnosis.

LABD is often characterized as either idiopathic or drug-induced. Vancomycin is the most commonly cited drug, but many others have also been implicated, including TMP-SMX, captopril, and phenytoin.[5] Drug-induced LABD is usually self-limited, and diagnosis is often based on a temporal relationship to drug administration. Specifically, LABD is most commonly reported to occur within 3 weeks of vancomycin administration, although the latency period to eruption for other agents has been reported to be up to 2 years in length.[5] LABD has also been associated with malignancies including non-Hodgkin lymphoma (NHL) and chronic lymphocytic leukemia (CLL).[7,8] In addition, there are case reports of LABD occurring after stem cell transplant in a patient with CLL and another with NHL.[9,10] Further investigation is required to determine the pathophysiologic mechanisms whereby drugs, malignancies, and other systemic diseases interact to precipitate LABD. In the interim, clinicians should be aware of these potential etiologic factors in patients presenting with LABD.

Drug-induced LABD usually resolves spontaneously within 3 to 5 weeks of withdrawal of the offending agent.[5] For idiopathic LABD and refractory cases of drug-induced LABD, both topical and systemic therapies may be effective. Topical corticosteroid therapy can be used as a sole agent in mild disease or as adjunctive therapy in more severe disease. In cases requiring systemic therapy, dapsone is considered the first-line agent.[1,3] Adverse effects of dapsone include hemolytic anemia, which can be severe in patients with G6PD deficiency, methemoglobinemia, hepatotoxicity, and rarely agranulocytosis.[11] Prior to dapsone initiation, patients should be screened with a baseline CBC, liver function tests, and G6PD screen. Sulfonamides, including sulphamethoxypyridazine and sulfasalazine, are second-line therapy.[1] Alternative therapies include immunosuppressive agents such as systemic corticosteroids and mycophenolate mofetil, intravenous immunoglobulin, and antibiotics such as erythromycin.[1,3,10] With significant mucosal involvement, a multidisciplinary approach to supportive care involving dermatology, gastroenterology, ophthalmology, and otolaryngology should be considered. Prompt diagnosis and treatment are crucial to avoid severe morbidity secondary to pain, poor nutrition, and scarring processes that can result in blindness or strictures within the aerodigestive tract.[12,13] **HP**

Corresponding author: Karolyn A. Wanat, MD; Department of Dermatology, University of Pennsylvania, 3600 Spruce Street, Philadelphia, PA 19104; 215-662-2737; karolyn.wanat@uphs.upenn.edu

REFERENCES

1. Fortuna G, Marinkovich MP. Linear immunoglobulin A bullous dermatosis. Clin Dermatol 2012;30:38–50.
2. Elder DE, Elenitsas RE, Johnson BL, at al. Lever's histopathology of the Skin. 10th ed. Philadelphia: Lippincott Williams & Wilkins; 2008.
3. Guide SV, Marinkovich MP. Linear IgA bullous dermatosis. Clin Dermatol 2001;19:719–27.
4. Egan CA, Zone JJ. Linear IgA bullous dermatosis. Int J Dermatol 1999;38:818–27.
5. Fortuna G, Salas-Alanis JC, Guidetti E, Marinkovich MP. A critical reappraisal of the current data on drug-induced linear immunoglobulin A bullous dermatosis: A real and separate nosological entity? J Am Acad Dermatol 2012;66:988–94.
6. Kelly SE, Frith PA, Millard PR, et al. A clinicopathological study of mucosal involvement in linear IgA disease. Br J Dermatol 1988;119:161–70.
7. McEvoy MT, Connolly SM. Linear IgA dermatosis: association with malignancy. J Am Acad Dermatol 1990;22:59–63.
8. Usmani N, Baxter KF, Child JA, Sheehan-Dare R. Linear IgA disease in association with chronic lymphocytic leukaemia. Br J Dermatol

2004;151:710–11.
9. Schultewolter T, Goos M, Dissemond J. Linear IgA dermatosis in an immunosuppressed patient after allogenic bone marrow transplantation. J Eur Acad Dermatol Venereol 2004;18:721–25.
10. Yhim HY, Kwon DH, Lee NR, et al. Linear IgA bullous dermatosis following autologous PBSC transplantation in a patient with non-Hodgkin's lymphoma. Bone Marrow Transplant 2011;46:156–8
11. Paniker U, Levine N. Dapsone and sulfapyridine. Dermatol Clin 2001;19:79–86.
12. Talhari C, Althaus C, Megahed M. Ocular linear IgA disease resulting in blindness. Arch Dermatol 2006;142: 786–7.
13. Sato K, Hanazawa H, Sato Y, Watanabe J. Initial presentation and fatal complications of linear IgA bullous dermatosis in the larynx and pharynx. J Laryngol Otol 2005;119:314–8.