C1 Inhibitor Disorder Presenting as Abdominal Pain in a Middle-aged Man

Govardhanan Nagaiah, MD

Angioedema is a self-limiting, localized subcutaneous and submucosal swelling with several distinct etiologies, which include allergic reactions, genetic disorders, drug-induced reactions, and idiopathic and acquired variants. Typically, angioedema is a benign condition; however, these swelling episodes can involve the upper respiratory tract (eg, the tongue, pharynx, larynx) and place the patient at risk for airway compromise and asphyxiation. Determining the cause of angioedema, therefore, may be crucial for both acute and long-term management in patients with conditions that cause chronic angioedema, such as C1 inhibitor disorders. C1 inhibitor disorders are characterized by recurrent attacks of peripheral edema with circumscribed nonpitting, nonpruritic lesions and abdominal pain that are not usually relieved by treatment with antihistamines or steroids. In this article, the case of a 43-year-old man with abdominal pain associated with C1 inhibitor disorder is presented, and diagnosis and management of C1 inhibitor disorders are reviewed.

CASE PRESENTATION

Initial Presentation and History

In January 2005, a 43-year-old male Hispanic agricultural worker presented to the emergency department with abdominal pain associated with severe nausea. The pain began at 4 AM and progressively worsened over the next several hours. The patient denied hematemesis and melena.

Physical Examination

On examination, the patient's vital signs were stable: blood pressure, 142/95 mm Hg; respiratory rate, 18 breaths/min; pulse oximetry, 98% without supplemental oxygen; temperature, 98.3°F (37°C). The patient did not have any facial or periorbital edema, and the airway was clear with no tongue swelling. Abdominal examination was benign other than diffuse periumbilical tenderness with no guarding or rigidity.

Laboratory and Imaging Studies

Laboratory studies were ordered, and the results were within normal limits other than mildly elevated levels of white blood cells, amylase, and alanine aminotransferase, which were not clinically significant (**Table**). Contrast computed tomography (CT) scan of the abdomen revealed abnormally thickened small bowel loops predominantly involving the jejunum and duodenum (**Figure**).

Hospital Admission

The patient was admitted for persistent abdominal pain of unclear etiology and was treated with bowel rest, intravenous fluids, and analgesia. The patient's symptoms resolved within 24 hours, and he became abusive to staff and left against medical advice. The patient has not had any further admissions to date.

Past Medical History

The author admitted the patient on 2 previous occasions (August 2004 and January 2005) and was, therefore, familiar with data from these presentations; however, the rest of the data comprising his medical history was obtained by chart review after the patient was discharged in January 2005. The patient had presented 1 month earlier (December 2004) with diffuse pain around his umbilicus, vomiting, and watery diarrhea. Abdominal examination revealed diffuse tenderness around his umbilicus with no guarding or rigidity. Abdominal CT scan demonstrated moderate perihepatic and pelvic ascites with wall thickening in the sigmoid area thought to be suspicious for colitis. He had a leukocytosis of $3.4 \times 10^3/\mu L$. His symptoms resolved within 24 hours, and he left against medical advice.

The patient also had admissions in 1998, 1999, 2002, and 2004 with complaints of facial/tongue swelling and slurred speech with dyspnea. With each of these admissions, there appeared to be a temporal relationship to an inciting event, specifically an insect bite in 1998, pesticide exposure in 1999 and 2002, and exposure

At the time of submission, Dr. Nagaiah was a hospitalist at the Yuma Regional Medical Center, Yuma, AZ. He is now a clinical instructor at Case Western Reserve University, and a hospitalist in the Department of General Internal Medicine, Case Medical Center, Cleveland, OH.

Table. Laboratory Results for the Case Patient

Laboratory Tests (units)	Results	Normal
Alanine aminotransferase (U/L)	46	10–40
Amylase (U/L)	98	25–85
Aspartate aminotransferase (U/L)	26	20–48
Blood urea nitrogen (mg/dL)	20	8–23
Chloride (mEq/L)	103	96–106
Hemoglobin (g/dL)	16.9	14.0–17.5
Lipase (U/L)	185	14–280
Potassium (mEq/L)	3.7	3.5–5.0
Serum creatinine (mg/dL)	1	0.6–1.2
Sodium (mEq/L)	140	136–142
Total serum calcium (mg/dL)	9	8.2–10.2
White blood cell count ($\times 10^3/\mu L$)	18.3	4.5–11.0

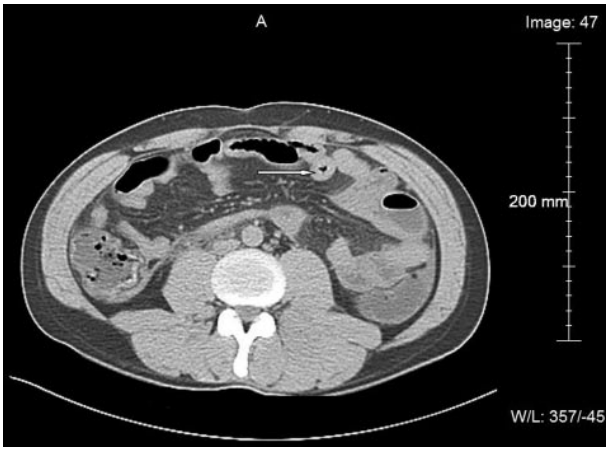

Figure. Contrast computed tomography scan of the abdomen showing abnormally thickened small bowel loops predominantly involving the jejunum and duodenum.

to detergent and boric acid in August 2004. However, the patient was admitted with the same complaints in November 2004 with no clear precipitating event. In each instance, he was diagnosed as having an allergic reaction and was treated with epinephrine, H_2 blockers, and steroids with no immediate response. His symptoms gradually subsided over a period of 1 day other than a presentation in 2002. On this occasion, the patient suffered severe airway compromise due to laryngeal edema, for which he received emergency tracheostomy and required mechanical ventilation for 24 hours.

During admission in August 2004, measurement of functional C1 esterase inhibitor (C1 INH) was ordered. The results were available a few weeks later and were found to be abnormal (5% [normal, > 68%; equivocal, 41%–67%; abnormal, < 40%]). The patient's history was negative for allergies and asthma, and he was not taking any medications. Surgical history was positive for appendectomy, and family history was positive for hypertension. His past medical history was otherwise unremarkable.

Diagnosis

Based on review of his medical record, the patient was diagnosed with C1 INH deficiency after discharge in January 2005, as this best explained his myriad presentations. Whether the deficiency was congenital or acquired was not established as C1q and C1 inhibitor antigenic levels were not obtained before the patient was discharged and lost to follow-up.

DISCUSSION

Diagnosing patients with C1 inhibitor disorder can be difficult given the large differential diagnosis for angioedema. In addition, these disorders are rare, and therefore, may not be familiar to physicians. In this patient, there were several clues that indicated the diagnosis of C1 inhibitor disorder. First, this patient had multiple admissions with episodes of facial and peripheral edema that did not respond to treatment with antihistamines, which rules out allergic reactions. Second, he had recurrent and usually self-remitting abdominal pain associated with angioedema, which should prompt testing for C1 INH deficiency. Third, CT findings of bowel wall thickening and ascites are suggestive of this rare condition.[1,2] Finally, the patient was not taking any medications known to precipitate attacks of angioedema.

C1 INHIBITOR DISORDERS

C1 inhibitor disorders are typically associated with either low levels or abnormal function of C1 INH. C1 INH is a serum α_2 globulin molecule and a member of the serpin family of protease inhibitors encoded on chromosome 11.[3] Its physiologic function is inhibition of the catalytic subunits of the first component of the classic complement pathway (C1r and C1s) and inhibition of kallikrein, plasmin, and coagulation factors XIa and XIIa. In C1 inhibitor disorders, dysfunctional or abnormally low levels of C1 INH lead to capillary leakage and subsequently angioedema. Although the precise cause of the capillary leakage is unknown, it is believed that a peptide formed during activation of the bradykinin–generating mediator pathway is responsible.

Acquired and Hereditary Forms

C1 inhibitor disorders can be divided into 2 categories, acquired and hereditary. The hereditary category,

known clinically as hereditary angioedema (HAE), is an autosomal dominant disease that affects 1 in 10,000 to 150,000 persons[4] and has been reported in all races with no sex predominance.[5] The literature describes 3 types of HAE, each with a different mechanism. Type I accounts for approximately 85% of HAE cases and is caused by decreased production of C1 INH. Type II accounts for the remaining 15% of HAE cases and is characterized by normal or elevated quantities of functionally impaired C1 INH.[6] Another type of familial, nonallergic angioedema that affects females only has been described (estrogen-dependent/estrogen-associated angioedema) but is not related to C1 INH levels or function and is tentatively labeled as type III HAE.[7] As type III HAE does not involve C1 INH deficiency, an in-depth discussion of this entity is beyond the scope of this review. It should be noted, however, that all 3 variants of HAE have similar signs and symptoms. Approximately 20% to 30% of HAE patients do not have a positive family history and most likely represent new mutations.[8,9]

Acquired C1 inhibitor disorder is a rare, separate entity caused by increased catabolism of C1 INH and C1q.[10] As a result, C1q levels are invariably low in patients with acquired C1 INH deficiency.[11] Acquired C1 inhibitor disorder has been associated with cancers, myeloproliferative disorders, autoimmune diseases, and infections. A specific autoantibody directed towards the C1 INH molecule has been described as well.[12]

Diagnosis

Clinical features. Recurrent attacks of angioedema associated with abdominal pain that do not respond to treatment with antihistamines are the hallmark of C1 inhibitor disorders. Patients with HAE usually develop symptoms during childhood, with the symptoms worsening at puberty. The skin and submucosal edema gradually develops over several hours, increasing slowly between 12 and 36 hours and subsiding within 2 to 3 days. The attack frequency varies widely from weekly to 1 to 2 times per year.[6]

Although prodromal erythema may be present, urticaria itself is not a feature of C1 INH deficiency, and its presence should indicate that another cause is responsible for the patient's angioedema symptoms. Prodromal erythema usually occurs in the extremities; however, it can affect any part of the body.[13] The 15% to 33% mortality rate reported is typically due to laryngeal edema.[14] In approximately 25% of patients, abdominal pain, nausea, and vomiting are the most prominent symptoms and are caused by submucosal edema that results in narrowing of the intestinal walls.[15] CT findings, as previously noted, reveal ascites and bowel wall thickening.[1,2] Drugs (eg, angiotensin–converting enzyme inhibitors, estrogen), infection, and emotional stress can precipitate attacks of angioedema. Dental procedures are the precipitating cause in up to 50% of attacks[16,17] and can lead to fatal asphyxiation between 4 and 30 hours after the procedure.[18]

It can be difficult to differentiate between surgical emergencies and C1 inhibitor disorders in patients whose predominant symptom is abdominal pain, thus leading to unnecessary appendectomies (as may have been the case in the patient presented here) or exploratory laparotomies prior to the patient being correctly diagnosed.[19] Conversely, inappropriate delays when surgery is indicated may occur after a patient has been diagnosed with C1 inhibitor disorder.[19]

In 1 report, endoscopic evaluation performed during an acute attack showed lesions resembling submucosal tumors with diffuse redness and bulging mucosa.[20] Similarly, barium studies performed during an acute attack showed extensive submucosal edema, spiculation, and fold thickening.[21] These mucosal changes were segmental and reverted to normal within days of the attack resolution. Thus, radiologic and endoscopic evaluation do not appear to be definitive studies, and a therapeutic challenge with C1 INH concentrate may be the only way to differentiate between an acute attack of angioedema and a true surgical diagnosis. However, C1 INH concentrate is not available in the United States.

Laboratory studies. Serum C4 titer is a reliable screening study for C1 INH deficiency, as patients with untreated HAE typically have low levels of serum C4 (< 30%), and this assay has 100% sensitivity and 100% negative predictive value.[22] When C4 levels are low, the next step is to test for C1 INH levels and function. If levels of C1 INH are low, the patient is diagnosed with type I HAE. If C1 inhibitor antigen levels are in the normal or high range, functional testing is required if HAE remains a strong diagnostic consideration; absence of function indicates type II HAE.[6] C1q level should also be obtained to rule out the possibility of acquired C1 inhibitor disorder. Determining whether the patient has nonhereditary C1 inhibitor disorder is important as further screening for precipitating illnesses, such as lymphoproliferative diseases, may be appropriate in older patients presenting for the first time with nonallergic angioedema.

Management

Management of C1 inhibitor disorders should be directed by the individual patient's frequency as well as severity of attacks, bearing in mind that some patients may require minimal to no intervention. Patients

should be educated about their illness so that appropriate treatment, when needed and when available, can be commenced early.

Treatment of acute attacks. At present, there is no drug approved in the United States for the treatment of acute attacks of C1 inhibitor disorder. Stanozolol (≤ 16 g/day) or danazol (≤ 1g/day) given early during an attack may shorten the duration of peripheral swelling, although no specific treatment is required in most cases if there are no life-threatening manifestations of the disease.[6] If available, C1 INH concentrate (500–1500 U depending on the severity) should be used if airway involvement is suspected.[23–25] Oropharyngeal attacks can lead to death from asphyxiation and hospitalization and careful monitoring of airway patency is imperative. If the airway is threatened, the patient should be intubated by an experienced physician who can perform emergency tracheostomy. Fresh frozen plasma is usually effective and can be used,[26–29] although worsening of symptoms has been reported, presumably due to replacement of complement with fresh frozen plasma.[30]

Severe abdominal attacks require aggressive intravenous fluid replacement and analgesia. Narcotics are usually required for pain relief. Antihistamines and corticosteroids are not effective in the treatment of acute attacks of C1 inhibitor disorders. C1 INH concentrate (not available in the United States) usually gives relief within 0.5 to 1.5 hours, with complete resolution of symptoms in 24 hours.[31] If symptoms persist at a high intensity 2 hours after infusion, additional concentrate should be given and alternative diagnoses should be considered. Epinephrine may have a transient effect on swelling but does not alter the course of the attack.

Primary prevention. Potential treatable triggers for attacks should be anticipated and treated in all patients. Possible complement triggers such as infections, including those of teeth, should be treated.[4,31] Although not substantiated by good data,[6] *Helicobacter pylori* infection may be associated with more severe disease and eradication might be beneficial.[32,33] Estrogen and angiotensin–converting enzyme inhibitors should be avoided because they are potent triggers of angiodema.[34–36] Angiotensin-II receptor blockers may be used with caution in patients with C1 inhibitor disorders.[6]

Short-term prophylaxis. High-dose anabolic androgen therapy (2 mg of stanozolol 3 times daily or 200 mg of danazol 3 times daily) begun 7 to 10 days prior to expected trauma (eg, surgical or dental procedures) affords excellent protection.[37] Alternatively, 2 units of fresh frozen plasma or of C1 INH concentrate, when available, infused several hours prior to the procedure may be used.[23,24,38]

Long-term prophylaxis. The general consensus appears to be to consider prophylaxis in patients with recurrent disabling symptoms and episodes of life-threatening laryngeal edema. It should be noted that absence of previous life-threatening attacks does not preclude the possibility of such attacks in the future. Availability of emergency care should also be a factor in deciding prophylactic treatment. The Canadian Consensus Algorithm[39] recommends prophylaxis if the patient experiences more than 1 severe attack every month or more than 5 disabling days per month. Treatment should be aimed at minimizing the frequency of attacks.

Attenuated androgens and antifibrinolytic agents (tranexamic acid or ε-aminocaproic acid [EACA]) are the mainstays of treatment. The most effective, well-tolerated long-term prophylactic drugs are anabolic androgens.[26,40–42] Stanozolol can be started at 2 mg/day and decreased by 2 mg/wk every 4 to 6 weeks. In most cases, adequate control can be achieved using up to 2 mg/day of stanozolol or 200 mg/day of danazol. The lowest dose affording good control should be used and may be dosed on alternate days as well. Dosage should be based on clinical indicators rather than increasing C1 INH or C4 levels, as they do not appear to correlate. Side effects are dose dependent and include hepatotoxicity, weight gain, muscle pains, headaches, depression, fatigue, nausea, constipation, menstrual irregularities, and virilization. Patients taking anabolic androgens should have their liver enzymes tested every 6 months. If the results are abnormal, hepatic ultrasound should be performed to look for adenomas. In children, anabolic steroids could cause androgenization, accelerated bone growth with premature bone fusion, and other undesirable side effects; anabolic steroids are therefore relatively contraindicated in children. Anabolic androgens are contraindicated in pregnancy and should be stopped prior to conception. Oxandrolone, which is approved for HIV wasting syndrome, has been found effective in treating HAE.[43]

Antifibrinolytic agents are second-line agents for treating patients with C1 inhibitor disorder and may be used in patients unable to tolerate androgens; however, these agents are not always effective in preventing angioedema.[44,45] The mechanism of action of antifibrinolytic agents in HAE is unknown. The typical therapeutic dose of EACA is 1 g orally 3 to 4 times daily, and the dose of tranexamic acid is between 1 and 1.5 g 2 to 3 times daily. Liver function should be monitored every 6 months.[6] Antifibrinolytic agents are contraindicated

in active thromboembolic disease, and patients with a personal or family history of thrombophilia should be screened.

CONCLUSION

C1 inhibitor disorders cause chronic abdominal pain and angioedema. Although these symptoms are self-limiting and usually benign, laryngeal edema may prove fatal. Differentiating angioedema associated with C1 inhibitor disorder is necessary, so that physicians may provide patients with appropriate treatment in the acute setting as well as provide short- and long-term prophylaxis as needed based on patients' attack frequency, severity, and access to care. **HP**

REFERENCES

1. Talavera A, Larraona JL, Ramos JL, et al. Hereditary angioedema: an infrequent cause of abdominal pain with ascites. Am J Gastroenterol 1995;90:471–4.
2. Bork K, Bindewald H, Bockers M, Eckhardt V. [Ascites and suspected acute abdomen in hereditary angioedema due to C1 inhibitor deficiency.] [Article in German.] Dtsch Med Wochenschr 1997;122:1347–50.
3. Agostoni A, Aygoren-Pursun E, Binkley KE, et al. Hereditary and acquired angioedema: problems and progress: proceedings of the third C1 esterase inhibitor deficiency workshop and beyond. J Allergy Clin Immunol 2004;114(3 Suppl):S51–131.
4. Volanakis JE, Frank MM, editors. The human complement system in health and disease. New York: M. Dekker; 1998:229–44.
5. Donaldson VH, Bissler JJ. C1-inhibitors and their genes: an update. J Lab Clin Med 1992;119:330–3.
6. Gompels MM, Lock RJ, Abinun M, et al. C1 inhibitor deficiency: consensus document [published erratum appears in Clin Exp Immunol 2005;141:189–90]. Clin Exp Immunol 2005;139:379–94.
7. Bork K, Dewald G. Hereditary angioedema type III, angioedema associated with angiotensin II receptor antagonists, and female sex [letter]. Am J Med 2004;116:644–5.
8. Eck SL, Morse JH, Janssen DA, et al. Angiodema presenting as chronic gastrointestinal symptoms. Am J Gastroenterol 1993;88:436–9.
9. Agostoni A, Cicardi M. Hereditary and acquired C-1 inhibitor deficiency: biological and clinical characteristics in 235 patients. Medicine (Baltimore) 1992;71:206–15.
10. Oltvai ZN, Wong EC, Atkinson JP, Tung KS. C1 inhibitor deficiency molecular and immunologic basis of hereditary and acquired angioedema. Lab Invest 1991;65:381–8.
11. Svetomir NM, David JI, et al. Acquired C1 esterase deficiency. Ann Intern Med 2000;132:144–150.
12. Alsenz J, Loos M. The acquired C1-INH deficiencies with autoantibodies (AAE type II). Behring Inst Mitt 1989;84: 165–72.
13. Carreer FM. The C1 inhibitor deficiency. A review. Eur J Clin Chem Clin Biochem 1992;30:793–807.
14. Moore GP, Hurley WT, Pace SA. Hereditary angioedema. Ann Emerg Med 1988;17:1082–6.
15. Sim TC, Grant JA. Hereditary angioedema: its diagnostic and management perspectives. Am J Med 1990;88:656–64.
16. Frank MM, Gelfand JA, Atkinson JP. Hereditary angioedema: the clinical syndrome and its management. Ann Intern Med 1976;84:580–93.
17. Karlis V, Glickman RS, Stern R, Kinney L. Hereditary angioedema: case report and review of management. Oral Surg Oral Med Oral Pathol Oral Radiol Endod 1997; 83:462–4.
18. Bork K, Baernstedt SE. Laryngeal edema and death from asphyxiation after tooth extraction in four patients with hereditary angioedema. J Am Dent Assoc 2003; 134:1088–94.
19. Cicardi M, Bergamaschini L, Cugno M, et al. Pathogenetic and clinical aspects of C1 inhibitor deficiency. Immunobiology 1998;199:366–76.
20. Hara T, Shiotani A, Matsunaka H, et al. Hereditary angioedema with gastrointestinal involvement: endoscopic appearance. Endoscopy 1999;31:322–4.
21. Pearson KD, Buchignani JS, Shimkin PM, Frank MM. Hereditary angioneurotic edema of the gastrointestinal tract. Am J Roentgenol Radium Ther Nucl Med 1972; 116:256–61.
22. Gompels MM, Lock RJ, Morgan JE, et al. A multicentre evaluation of the diagnostic efficiency of serological investigations for C1 inhibitor deficiency. J Clin Pathol 2002; 55:145–7.
23. Kunschak M, Engl W, Maritsch F, et al. A randomized, controlled trial to study the efficacy and safety of C1 inhibitor concentrate in treating hereditary angioedema. Transfusion 1998;38:540–9.
24. Waytes AT, Rosen FS, Frank MM. Treatment of hereditary angioedema with vapor-heated C1 inhibitor concentrate. N Engl J Med 1996;334:1630–4.
25. Bork K, Barnstedt SE. Treatment of 193 episodes of laryngeal edema with C1 inhibitor concentrate in patients with hereditary angioedema. Arch Intern Med 2001; 161:714–8.
26. Zuraw BL. Current and future therapy for hereditary angioedema. Clin Immunol 2005;114:10–6.
27. Galan HL, Reedy MB, Starr J, Knight AB. Fresh frozen plasma prophylaxis for hereditary angioedema during pregnancy. A case report. J Reprod Med 1996;41:541–4.
28. Warrier MR, Copilevitz CA, Dykewicz MS, Slavin RG. Fresh frozen plasma in the treatment of resistant angiotensin-converting enzyme inhibitor angioedema. Ann Allergy Asthma Immunol 2004;92:573–5.
29. Hill BJ, Thomas SH, McCabe C. Fresh frozen plasma for acute exacerbations of hereditary angioedema [letter]. Am J Emerg Med 2004;22:633.
30. Zuraw BL. Diagnosis and management of hereditary angioedema: an American approach. Transfus Apher Sci 2003;29:239–45.
31. Cicardi M, Frangi D, Bergamaschini L, et al. Acquired

C1 inhibitor deficiency with angioedema symptoms in a patient infected with Echinococcus granulosus. Complement 1985;2:133–9.
32. Rais M, Unzeitig J, Grant JA. Refractory exacerbations of hereditary angioedema with associated Helicobacter pylori infection. J Allergy Clin Immunol 1999;103:713–4.
33. Farkas H, Gyeney L, Majthenyi P, et al. Angioedema due to acquired C1-esterase deficiency in a patient with Helicobacter pylori infection. Z Gastroenterol 1999;37:513–8.
34. Tisch M, Lampl L, Groh A, Maier H. Angioneurotic edemas of the upper aerodigestive tract after ACE-inhibitor treatment. Eur Arch Otorhinolaryngol 2002;259:419–21.
35 Berkun Y, Shalit M. Hereditary angioedema first apparent in the ninth decade during treatment with ACE inhibitor. Ann Allergy Asthma Immunol 2001;87:138–9.
36. Kleiner GI, Giclas P, Stadtmauer G, Cunningham-Rundles C. Unmasking of acquired autoimmune C1-inhibitor deficiency by an angiotensin-converting enzyme inhibitor. Ann Allergy Asthma Immunol 2001;86:461–4.
37. Agostoni A, Cicardi M, Cugno M, Storti E. Clinical problems in the C1-inhibitor deficient patient. Behring Inst Mitt 1993;93:306–12.
38. Maves KK, Weiler JM. Tonsillectomy in a patient with hereditary angioedema after prophylaxis with C1 inhibitor concentrate. Ann Allergy 1994;73:435–8.
39 Canadian 2003 International Consensus Algorithm for the Diagnosis, Therapy and Management of Hereditary Angiodema. J Allergy Clin Immunol 2004;143:629–37.
40. Agostoni A, Cicardi M, Martignoni GC, et al. Danazol and stanozolol in long-term prophylactic treatment of hereditary angioedema. J Allergy Clin Immunol 1980;65: 75–9.
41. Gelfand JA, Sherins RJ, Alling DW, Frank MM. Treatment of hereditary angioedema with danazol. Reversal of clinical and biochemical abnormalities. N Engl J Med 1976;295:1444–8.
42. Rothbach C, Green RL, Levine MI, Fireman P. Prophylaxis of attacks of hereditary angioedema. Am J Med 1979; 66:681–3.
43. Barakat AJ, Castaldo AJ. Successful use of oxandrolone in the prophylaxis of hereditary angioedema: a case report. Pediatr Asthma Allergy Immunol 1999;13:189–93.
44. Frank MM, Sergent JS, Kane MA, Alling DW. Epsilon aminocaproic acid therapy of hereditary angioneurotic edema. A double-blind study. N Engl J Med 1972; 286:808–12.
45. Zuraw BL. Current and future therapy for hereditary angioedema. Clin Immunol 2005;114:10–6.

Copyright 2007 by Turner White Communications Inc., Wayne, PA. All rights reserved.