Spinal Dural Arteriovenous Fistula: An Overlooked Cause of Progressive Myelopathy

Rebecca I. Spain, MD
Erika Stuckert, MD
Ashwini Sharan, MD
Christopher T. Skidmore, MD

Spinal dural arteriovenous fistula (SDAVF) is a rare vascular lesion of the spinal cord associated with progressive myelopathy.[1] Older men are most commonly affected, and symptoms include progressive gait dysfunction, weakness, sensory loss, and bowel, bladder, and sexual dysfunction.[2] The diagnosis of SDAVF is often overlooked because its symptoms overlap with those of more common causes of myelopathy such as cervical spondylosis.[3] SDAVF accounted for nearly one third of unexplained myelopathies in a series of 78 patients.[4] Additionally, imaging studies can be ambiguous or even normal,[4] frequently resulting in delayed diagnosis that may confer a worse outcome despite treatment.[5] As SDAVF represents a surgically treatable form of nontraumatic myelopathy, it should be included early in the differential diagnosis. This article presents the case of a 77-year-old man with a 2-year history of progressive myelopathy that was ultimately diagnosed as SDAVF.

CASE PRESENTATION

Initial Presentation and History

A 77-year-old man was transferred emergently from a rehabilitation facility to the neurology service with acute urinary retention and back pain as well as sudden worsening of progressive gait dysfunction, sensory loss, constipation, and erectile dysfunction that had been present for 2 years. He was unsuccessfully treated 3 months prior with intravenous methylprednisolone (1000 mg/day) for 3 days for transverse myelitis, a diagnosis made after a T2-weighted magnetic resonance image (MRI) demonstrated a nonenhancing intrinsic cord lesion extending from T4 to the conus medullaris. A lumbar puncture performed at the time of MRI revealed high protein levels without the presence of inflammation or malignant cells. Although there was known lumbar disc disease, there was no history of acute trauma or strenuous exercise to precipitate a lumbar injury. Furthermore, no history of preceding illnesses, immunizations, immune deficiency states, connective tissue disorders, toxic exposures, or known malignancies were present to explain the cause of transverse myelitis. Past medical history was positive for hypertension, benign prostatic hypertrophy, chronic kidney disease, diverticulosis, and lumbar disc disease.

Physical Examination and Laboratory Evaluation

At admission, the patient's physical examination was normal aside from an elevated blood pressure of 181/78 mm Hg with a regular pulse. Neurologic testing revealed normal mental status, cranial nerve function, and upper extremity motor and sensory examinations. The legs exhibited a distal paraparesis greater than proximal paraparesis, with right iliopsoas Medical Research Council (MRC) strength of 2/5 worse than left iliopsoas MRC strength of 3/5. Distal MRC strength was 0/5 bilaterally. Mild wasting and increased tone were present in the legs. Deep tendon reflexes were pathologically increased at the patellae but not at the Achilles tendon; Babinski's sign was absent in both legs. Rectal tone was decreased. Sensation to pinprick and temperature was absent distal to the T7 level. Vibration and proprioception were decreased to the ankles. The patient was nonambulatory. Routine complete blood count, vitamin B_{12} level, folate level, methylmalonic acid level, homocysteine level, serum protein

At the time of submission, Dr. Spain was a neuroimmunology fellow, Thomas Jefferson Comprehensive Multiple Sclerosis Center, and Dr. Stuckert was a neurology resident; both were at the Thomas Jefferson University, Philadelphia, PA. Dr. Spain is now a senior instructor, MS Center of Oregon, Oregon Health Sciences University, Portland, OR. Dr. Stuckert is now an epilepsy fellow, Stanford Comprehensive Epilepsy Center, Palo Alto, CA. Dr. Sharan is an assistant professor, Department of Neurological Surgery, and Dr. Skidmore is an assistant professor, Department of Neurology; both are at the Thomas Jefferson University.

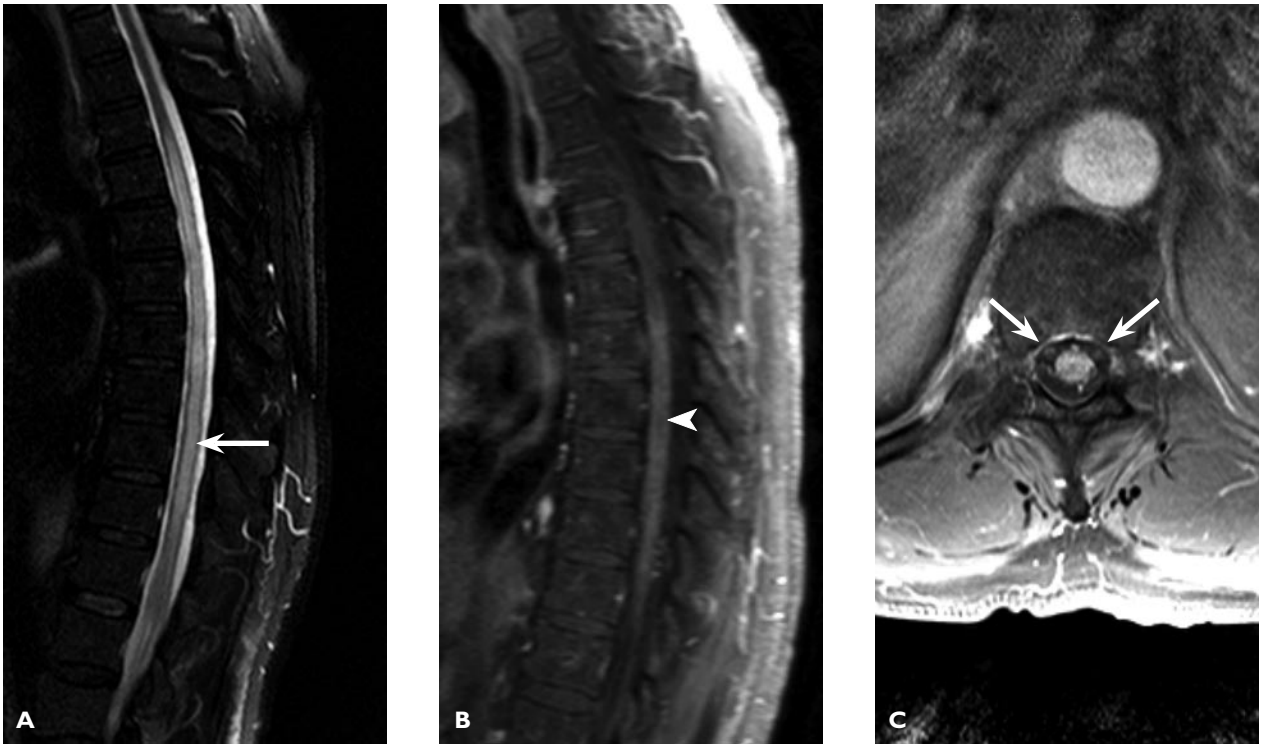

Figure 1. A T2-weighted magnetic resonance image (**A**) of the thoracic and lumbar spine demonstrated a hyperintense intramedullary lesion with cord edema extending from T4 to the conus (*arrow*). After gadolinium administration, a T1-weighted magnetic resonance image (**B**) demonstrated this lesion enhancing diffusely (*arrowhead*). Magnetic resonance angiography (**C**) revealed several minimally dilated vessels that were considered normal (*arrows*).

electrophoresis, and thyroid function studies were normal. A chemistry panel revealed a high serum creatinine (1.5 mg/dL [normal 0.6–1.2 mg/dL]), consistent with the known history of chronic kidney disease. The patient was negative for hepatitis B and C, HIV, and human T-lymphotropic virus antibodies as well as Lyme disease on polymerase chain reaction testing of the cerebrospinal fluid.

Radiology

An MRI of the spine revealed diffuse increased T2 cord signal from T4 to the conus with edema (**Figure 1A**), which enhanced after gadolinium administration (**Figure 1B**). Based on magnetic resonance characteristics, a primary intramedullary tumor was thought unlikely, and no primary tumor was found to suggest a spinal metastasis after full body computed tomography screening was performed. A vascular cause of the patient's symptoms was entertained. Computed tomography angiography of the thoracic spine was normal. Although magnetic resonance angiography (MRA) of the thoracic spine revealed a few minimally dilated vessels at the T10–11 level (**Figure 1C**), the examination was considered within normal limits, and no vascular disorder was established.

Treatment and Hospital Course

Two weeks after hospitalization, the patient was found to be acutely weak and flaccid in his proximal leg muscles during a morning neurologic examination and was immediately started on intravenous methylprednisolone (1000 mg/day). Three days of steroid administration provided no benefit. Although the MRA had been normal, clinical suspicion for a vascular disorder remained high; therefore, spinal angiography was performed on hospital day 19. Two procedures using the Seldinger technique were required because of the large iodinated contrast load in the context of a high baseline creatinine. The second angiography on hospital day 21 definitively demonstrated an abnormal vessel at the left T12 pedicle with an early draining vein both superior and inferior extending up to the level of T3 consistent with SDAVF (**Figure 2**). The patient underwent intra-arterial embolization at the time of angiography, which was unsuccessful due to an inability to canalize the severely atherosclerotic vessel. Subsequently, the patient underwent treatment

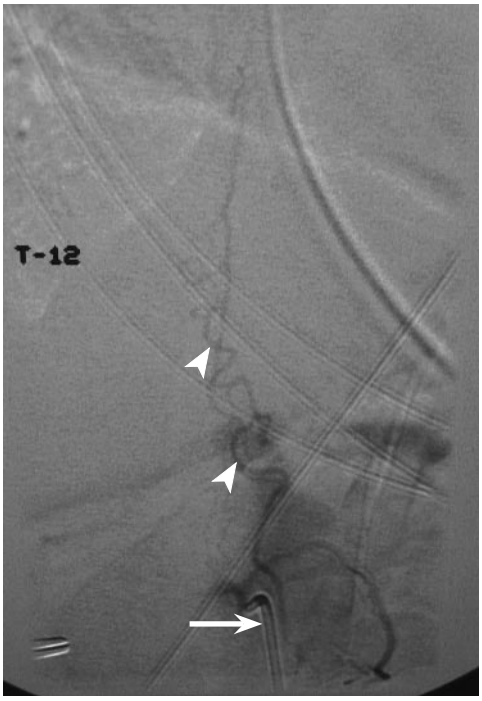

Figure 2. Spinal angiogram demonstrating the cannula at the left T12 pedicle (*arrow*) and the serpentine abnormal vessel (*arrowheads*) diagnostic of a spinal dural arteriovenous fistula.

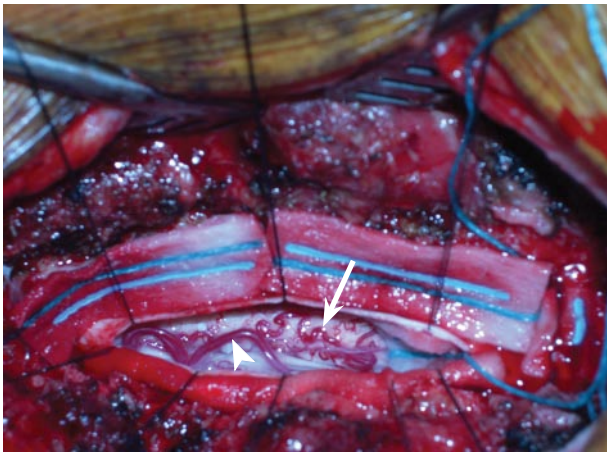

Figure 3. Photograph of the tightly coiled arteriovenous fistula (*arrow*) and dilated draining veins (*arrowhead*) overlaying the spinal cord prior to ligation.

via an open laminectomy and clipping of the fistula on hospital day 26 (**Figure 3**). There were no complications during the temporary clipping of the SDAVF, subsequent ligation of the vessels, or postoperative monitoring. The patient's back pain resolved by the following day, although his neurologic examination remained unchanged at the time of discharge (hospital day 29) to the rehabilitation facility. At a 3-month follow-up visit to the outpatient neurology clinic, the patient was pain free and able to ambulate with a walker. However, he continued to have profound sensory loss along with severe bowel and bladder dysfunction.

SDAVF

Spetzler et al[6] proposed a classification for spinal vascular lesions consisting of 3 categories: neoplasms, aneurysms, and arteriovenous lesions, which includes SDAVFs. In a series that analyzed the spinal angiograms of 132 patients, SDAVFs accounted for 66 of 97 (68%) spinal arteriovenous lesions identified.[1] The annual incidence of SDAVF is estimated to be 5 to 10 cases per million persons.[7] Approximately 80% of patients diagnosed with SDAVF are male and most (two thirds) are between ages 60 and 70 years.[7] In a series of 80 patients, median time to diagnosis was 15 months (range, 7 days–197 mo).[5] Given the diagnostic delays, most patients require an ambulatory device at the time of diagnosis, and one third are wheelchair dependent.[7] SDAVFs are predominately found at the lower thoracic and upper lumbar levels with presenting symptoms secondary to myelopathy along with back, radicular, and nonspecific pain; only 1% of patients present with subarachnoid hemorrhage.[7] Although SDAVF is considered an acquired lesion, the exact etiology is unknown. Proposed etiologic mechanisms for SDAVF include trauma, infection, surgery, and syringomyelia. Unlike intracranial dural arteriovenous fistulas, there is no association with venous thrombosis, and thrombophilia does not appear to be a predisposing factor.[8]

Pathophysiology

First described in 1926 by Foix and Alajouanine,[9] the pathophysiology of venous hypertension was not elucidated until 1974 by Aminoff and Logue.[10] In a SDAVF, typically 1 (but sometimes multiple) feeding radiculomedullary artery enters the dura mater of the spinal cord at the dural root sleeve and forms a fistula with a medullary vein, thus arterializing the corona venous plexus surrounding the spinal cord. The resistance to venous outflow results in chronic venous hypertension/stagnation leading to chronic medullary ischemia.[6] In the case patient, a feeding dorsal radiculomedullary artery formed an intradural arteriovenous fistula and arterialized the coronal venous plexus (Figures 2 and 3). Hurst et al[11] reported that a spinal cord biopsy from a patient with documented SDAVF demonstrated marked hypocellularity, small blood vessels with hyalinized walls, extensive vascular sclerosis and gliosis of the

white matter, and focally enlarged, degenerating axons, findings that supported a pathophysiology of ischemic myelopathy due to increased venous pressure.

Clinical Features

The clinical course of a SDAVF is one of a slowly progressive or stepwise myelopathy with symptoms of weakness, sensory loss, and bowel, bladder, and/or sexual dysfunction. Gait disturbance is often the first motor symptom observed, occurring in 20% to 69% of cases; the paraparesis or tetraparesis can be flaccid, spastic, or mixed.[2] Development of sensory symptoms tends to parallel motor symptoms, with progressive distal to proximal sensory loss usually associated with a spinal sensory level. Back and radicular pain is often present along with nonspecific cramping and burning. Symptoms can be aggravated by exercise; acute deterioration is not uncommon.[7]

Diagnostic Evaluation

MRI has replaced myelography for initial radiographic diagnostic evaluation of SDAVF. MRI findings associated with SDAVF include spinal cord congestion, swelling, increased T2 signal, and decreased T1 signal with or without patchy or diffuse enhancement. Lesions range from 1 to 11 segments long.[12] MRI, however, is not fully sensitive for diagnosing SDAVF; of 22 confirmed cases of SDAVF in a series of 78 cases of unexplained myelopathy, 3 patients had a normal MRI.[4] MRA can enhance the diagnostic yield to approximately 80% and reduce the iodinated contrast load necessary for spinal angiography by localizing the fistula.[13] In a series of 31 cases, MRA had a sensitivity of 91% and specificity of 78% for confirming the presence and absence of a SDAVF. It also reduced the amount of iodinated contrast load by more than 50% during conventional angiography when the level of the fistula was localized as compared with the quantity of contrast necessary when MRA was either nonlocalizing or negative.[13] On MRA, dilated perimedullary veins are seen in patients with SDAVF, but these are not specific to this condition and may be masked by variable blood flow properties and pulsation artifacts. Spinal angiography is required for definitive diagnosis. If the lesion is not localized by MRI and MRA, conventional angiography requires the injection of each spinal artery supplying the dura, a procedure that is time consuming and can be complicated by concurrent atherosclerotic disease and contraindications for iodinated contrast. However, spinal angiography should be seriously considered in patients with a normal MRI and MRA if the clinical suspicion for a fistula is high given the treatable nature of this condition.[13]

Differential Diagnosis

The differential diagnosis of nontraumatic progressive myelopathy is broad (**Table**).[14,15] The most urgent diagnoses to exclude are compressive neoplasm and infection with a spinal epidural abscess, conditions readily identifiable with neuroimaging and cerebrospinal fluid analysis. However, other causes of increased MRI T2 cord signal are intramedullary tumors, degenerative disc disease, inflammatory and autoimmune conditions, infections, vascular disorders, and nutritional and toxic causes. Intradural tumors can be primary or metastatic and are found in the intramedullary or extramedullary space.[14,15] Myelopathy due to cervical spondylosis is the most common cause of nontraumatic spastic paraparesis and quadriparesis, accounting for nearly one quarter of cases in a series of 585 patients presenting to a regional medical center in the United Kingdom.[3] Lumbar canal stenosis is also common in this age group and can contribute to gait dysfunction, thus complicating the diagnosis. The spinal cord is at risk for ischemia and infarct following surgery or an aortic artery dissection. Inflammatory myelitis can be isolated (idiopathic transverse myelitis) or can be the first sign of multiple sclerosis. Myelitis can be acute (as seen in postviral infection or demyelinating myelitis) but can also be subacute to chronic conditions (eg, AIDS myelopathy, syphilis).[14,15] Inflammation of the spinal cord also occurs in several rheumatologic and connective tissue diseases, which may precede the onset of systemic symptoms by years.[16] Nutritional deficiencies should be considered in patients with gastrointestinal disease, a history of gastric bypass surgery, or history of toxic exposures that prevent adequate absorption of nutrients.[17] Myelopathy occurs in paraneoplastic syndromes as well as hereditary and degenerative conditions and also may be caused by radiation or electrical injury.

The time course, patient age, comorbidities, systemic symptoms, presence or absence of peripheral nervous system involvement, and localization to tracts or regions within the spinal cord can help narrow the extensive differential diagnosis for progressive myelopathy. Many etiologies are easily excluded by history, imaging (eg, tumors), and serum and cerebrospinal fluid analysis (eg, infections). However, the nonspecific features of SDAVF and frequency of both upper motor neuron signs (increased muscle tone and deep tendon reflexes) and lower motor neuron signs (flaccid weakness, depressed deep tendon reflexes) can delay

diagnosis, particularly in older adults who are likely to have comorbid systemic diseases and/or cervical spondylosis. Failure to respond to standard therapy for other causes of myelopathy should trigger further investigation.

Treatment

Treatment of SDAVF involves either an open laminectomy with resection of the draining fistula or endovascular occlusion of the responsible vessel.[18] Open surgery results in 98% fistula occlusion with 2% morbidity but exposes the patient to surgical risks.[18] Endovascular embolization is advantageous in that it can be performed at the time of angiography; however, this procedure has lower permanent occlusion rates (30%–75%) and can be complicated by atherosclerotic vessels.[19] The success of endovascular techniques is improving with changes in technology, endovascular occlusive agents, and increasing experience. In a meta-analysis of long-term outcomes after microsurgery, the authors concluded that 55% of patients treated for SDAVF showed clinical improvement in gait, 11% had worsened gait, and the rest remained stable. Improvements in micturition were less favorable, with only 33% showing improvement.[18] Prognosis is related to the level of disability at diagnosis. Improvements occur in activities of daily living with the greatest benefit in motor and pain symptoms, followed by sensory symptoms, and lastly by bowel and bladder deficits.[7] Indications for repeat spinal angiography include failure to improve, further clinical deterioration, or a delayed deterioration with persistent abnormalities on MRI, which can indicate a lack of occlusion or a second fistula.[19]

CONCLUSION

Although SDAVF is a known cause of progressive myelopathy, it is frequently overlooked because its clinical features overlap with more common causes of myelopathy and because neuroimaging may be normal. As SDAVF has a better outcome when diagnosed earlier in the disease course, it should be considered in the differential diagnosis of selected patients, such as older patients (particularly men) with progressive myelopathy. High clinical suspicion for SDAVF when neuroimaging is ambiguous should prompt angiography to avoid delay in this treatable condition. **HP**

REFERENCES

1. Gilbertson JR, Miller GM, Goldman MS, Marsh WR. Spinal dural arteriovenous fistulas: MR and myelographic findings. AJNR AM J Neuroradiol 1995; 16:2049–57.
2. Atkinson JL, Miller GM, Krauss WE, et al. Clinical and radiographic features of dural arteriovenous fistula, a treatable cause of myelopathy. Mayo Clin Proc 2001;76:1120–30.

Table. Differential Diagnosis of Nontraumatic Progressive Myelopathy

Infection
Spinal epidural abscess
HIV/AIDS myelopathy
Human T-cell lymphotropic virus type 1
Syphilis
Tuberculosis
Schistosomiasis
Lyme disease
Acute viral myelitis
Spinal cord neoplasm
Intramedullary primary tumors
Intramedullary metastases
Intradural extramedullary tumors
Extradural primary tumors, malignant or benign
Vascular diseases
Ischemia/infarct
Vascular lesions
Neoplasms
Hemangioblastomas
Cavernous malformations
Aneurysms
Arteriovenous lesions
Fistulas (eg, spinal dural arteriovenous fistula)
Malformations
Musculoskeletal disease
Cervical spondylosis
Lumbar canal stenosis
Inflammatory disease
Transverse myelitis
Multiple sclerosis
Systemic lupus erythematosus
Sjögren's syndrome
Rheumatoid arthritis
Sarcoidosis
Paraneoplastic syndrome
Nutritional/toxic causes
Vitamin B_{12} or E deficiency
Nitrous oxide toxicity
Copper deficiency
Radiation myelopathy
Inherited and degenerative myelopathies
Amyotrophic lateral sclerosis
Hereditary spastic paraplegias
Adrenoleukodystrophy
Friedreich's ataxia
Other
Electrical injury
Hepatic myelopathy
Decompression sickness myelopathy
Syringomyelia

3. Moore AP, Blumhardt LD. A prospective survey of the causes of non-traumatic spastic paraparesis and tetraparesis in 585 patients. Spinal Cord 1997;35:361–7.
4. Strom RG, Derdeyn CP, Moran CJ, et al. Frequency of spinal arteriovenous malformations in patients with unexplained myelopathy. Neurology 2006; 66:928–31.
5. Jellema K, Canta LR, Tijssen CC, et al. Spinal dural arteriovenous fistulas: clinical features in 80 patients. J Neurol Neurosurg Psychiatry 2003;74: 1438–40.
6. Spetzler RF, Detwiler PW, Riina, HA, Porter RW. Modified classification of spinal cord vascular lesions. J Neurosurg 2002;96(2 Suppl):145–56.
7. Koch C. Spinal dural arteriovenous fistula. Curr Opin Neurol 2006;19:69–75.
8. Jellema K, Tijssen CC, Fijnheer R, et al. Spinal dural arteriovenous fistulas are not associated with prothrombotic factors. Stroke 2004;35:2069–71.
9. Foix C, Alajouanine T. [Subacute necrotic myelitis, slowly progressive central myelitis with vascular hyperplasia, and slowly ascending, increasingly flaccid amyotrophic paraplegia accompanied by albuminocytologic dissociation.] [Article in French.] Rev Neurol (Paris) 1926;46:1–42.
10. Aminoff M, Logue V. The prognosis of patients with spinal vascular malformations. Brain 1974;97:211–8.
11. Hurst RW, Kenyon LC, Lavi E, et al. Spinal dural arteriovenous fistula: the pathology of venous hypertensive myelopathy. Neurology 1995;45:1309–13.
12. Pattany PM, Saraf-Lavi E, Bowen BC. MR Angiography of the spine and spinal cord. Top Magn Res Imaging 2003;14:444–60.
13. Luetmer PH, Lane JI, Gilbertson JR, et al. Preangiographic evaluation of spinal dural arteriovenous fistulas with elliptic centric contrast-enhanced MR angiography and effect on radiation dose and volume of iodinated contrast material. AJNR AM J Neuroradiol 2005;26:711–8.
14. Sheerin F, Collison K, Quaghebeur G. Magnetic resonance imaging of acute intramedullary myelopathy: radiological differential diagnosis for the on-call radiologist. Clin Radiol 2009;64:84–94.
15. Abul-Kasim K, Thurnhur MM, McKeever P, Sundgren PC. Intradural spinal cord tumors: current classification and MRI features. Neuroradiology 2008;50:301–14.
16. Delalande S, de Seze J, Fauchais AL, et al. Neurologic manifestations in primary Sjögren syndrome: a study of 82 patients. Medicine (Baltimore) 2004;83: 280–91.
17. Tan JC, Burns DL, Jones HR. Severe ataxia, myelopathy, and peripheral neuropathy due to acquired copper deficiency in a patient with history of gastrectomy. JPEN J Parenter Enteral Nutr 2006;30:446–50.
18. Steinmetz MP, Chow MM, Krishnaney AA, et al. Outcome after the treatment of spinal dural arteriovenous fistulae: a contemporary single-institution series and meta-analysis. Neurosurgery 2004;55:77–88.
19. Van Dijk JM, TerBrugge KG, Willinsky RA, et al. Multidisciplinary management of spinal dural arteriovenous fistulas: clinical presentation and long-term follow-up in 49 patients. Stroke 2002;33:1578–83.

Copyright 2009 by Turner White Communications Inc., Wayne, PA. All rights reserved.