# Antiphospholipid Syndrome: A Paraneoplastic Phenomenon Unmasking Occult Extragonadal Seminoma

*Samer Bleibel, MD*
*Kirti Sanghvi, MD*
*Sadia Hussain, MD*
*Rajan S. Kohli, MD*

Antiphospholipid syndrome (APS) is a disorder defined by recurrent vascular thrombosis, pregnancy loss, or thrombocytopenia and the presence of persistently elevated levels of antiphospholipid antibodies. This syndrome develops secondary to systemic lupus erythematosus and other autoimmune disorders, infections, use of certain drugs, and malignancy. Primary APS occurs in isolation and is idiopathic. This article describes the case of a patient with recurrent deep venous thrombosis (DVT) caused by APS that presented as a paraneoplastic phenomenon, unmasking an occult retroperitoneal seminoma.

## CASE PRESENTATION

### Initial Presentation and Evaluation

A 46-year-old man presented to the emergency department complaining of swelling and pain affecting his right lower extremity that was found to be caused by DVT as shown by Doppler ultrasonography. His past medical history was significant for an undescended right testicle that was surgically corrected by inguinal orchiopexy at age 6 years as well as a superficial lower extremity thrombophlebitis that had been diagnosed several months prior. Initial laboratory studies revealed an elevated partial thromboplastin time (PTT) of 43.6 sec (normal, 22–34 sec), a prothrombin time (PT) of 11.8 sec (normal, 11–13 sec), and an international normalized ratio (INR) of 1.05. Review of the patient's medical records showed that his PTT 6 months ago was 81.6 sec, PT was 15.3 sec, and INR was 1.79. In addition, complete blood count at the current presentation showed thrombocytopenia of 93,000 cells/μL (lower normal limit, 150,000 cells/μL). The patient's IgG anticardiolipin level was greater than 80 GPL units (high positive), while the test for IgM anticardiolipin antibodies was negative. These findings were highly suggestive of APS. The remainder of the hypercoagulability tests were unremarkable.

### Further Work-up

Secondary causes of APS were sought, including malignancy and rheumatic disorders. Computed tomography (CT) of the chest was negative, while abdominal CT showed a 3 × 2 cm retroperitoneal lymph node anterior to the inferior vena cava (**Figure 1**). Because of the location of the enlarged lymph node and given the history of an undescended testicle, the possibility of a gonadal neoplasm was considered. Testing revealed a mildly elevated level of α-fetoprotein at 10.9 ng/mL (normal, 0.0–8.8 ng/mL), while a β-human chorionic gonadotropin assay was negative. Ultrasonography of the testicles showed an atrophic right testicle with a heterogeneous density suspicious for malignancy. Subsequently, the patient underwent orchiectomy that revealed an atrophic testicle with no evidence of neoplastic changes.

The etiology of the enlarged retroperitoneal lymph node was still unclear. CT-guided biopsy of the lymph node was deferred due to the close proximity to the inferior vena cava, and thus an open laparotomy was performed. Histopathologic evaluation of the resected lymph node revealed features consistent with an extragonadal seminoma (**Figure 2**). The patient was further treated with radiotherapy, to which he had an excellent response. He was placed on warfarin during the 12 months of treatment. Four-years after being diagnosed and treated, the patient has had no recurrence of the seminoma or thrombosis and does not require anticoagulation therapy.

*Dr. Bleibel is a resident, Department of Internal Medicine, Saint John's Medical Centers, Detroit, MI. Dr. Sanghvi is a resident and Dr. Kohli is an attending physician, Department of Family Medicine, North Oakland Medical Centers, Pontiac, MI. Dr. Hussain is a resident, Department of Internal Medicine, Caritas Carney Hospital/Tufts University, Boston, MA.*

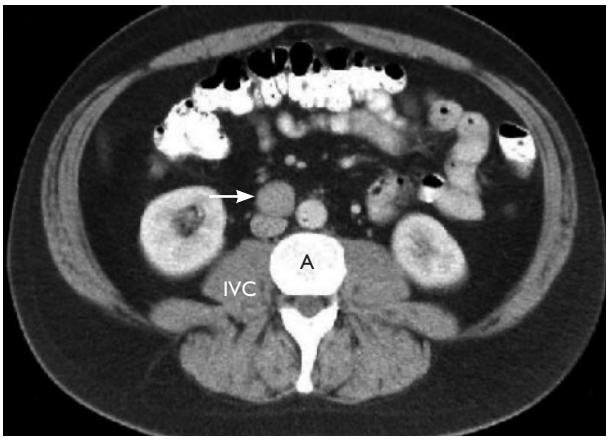


**Figure 1.** Abdominal computed tomography scan showing an enlarged retroperitoneal lymph node (*arrow*) compressing the inferior vena cava (IVC) anterolateral to the abdominal aorta (A).

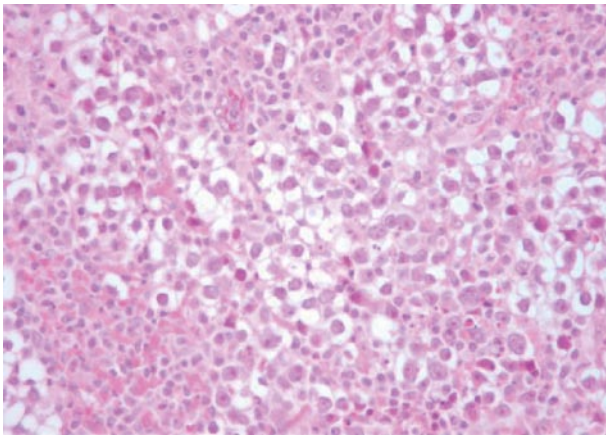

**Figure 2.** Open biopsy of the enlarged retroperitoneal lymph node revealed the diagnosis of seminoma. It is characterized by large cells with clear cytoplasm aggregated in nests separated by thin septa of infiltrating lymphocytes.

## HYPERCOAGULABILITY IN MALIGNANCY

The association between hypercoagulability and cancer was first noted by Trousseau in 1865.[1] Since then, the term *Trousseau's syndrome* has been used in reference to recurrent episodes of migratory venous and/or arterial thrombosis occurring in patients with underlying malignancy.[2] Further studies have shown that DVT and pulmonary embolism occur in 10% to 50% of patients with cancer.[3] Thrombosis has been associated with all kinds of cancers and is triggered by tissue factor, cancer procoagulant, and/or various cytokines.[4,5] The term *Trousseau's syndrome* is used broadly to refer to any form of hypercoagulability associated with cancer regardless of the etiopathologic mechanism. APS as a paraneoplastic phenomenon represents an autoimmune-mediated form of Trousseau's syndrome.[6] Cancer-related APS has been associated with a variety of malignancies, including solid tumors and hematologic neoplasms. Besides malignancy, secondary forms of APS occur with infections, connective tissue disorders, and use of certain drugs, while the primary form of this disease is idiopathic.[7,8]

Approximately 20% of patients presenting with DVT have a known active malignancy. In addition, studies have shown that an occult malignancy is identified at the time of the idiopathic thrombotic event in more than 3% of patients, and this number increases to 10% after 6 months.[7,9,10] Moreover, the Montpelier Antiphospholipid Study has shown that 19% of patients with APS have a known or occult malignancy.[10] It is important to keep in mind that thrombotic events associated with antiphospholipid antibodies can be the first manifestation of an occult malignancy.[11]

APS is characterized by the presence of antibodies (anticardiolipin antibodies, anti-β2-glycoprotein I, and lupus anticoagulant) directed against either phospholipids or plasma proteins bound to anionic phospholipids. Clinically, the syndrome manifests as recurrent fetal losses, noninfectious endocarditis, thrombocytopenia, incidental prolongation of a test of blood coagulation (eg, PT or PTT), or, most commonly, venous or arterial thrombosis.[9,12,13]

For patients with cancer-related thrombophilia, therapy should target the underlying malignancy. Because the patient will continue to be at high risk for recurrent thrombotic events as long as the tumor persists,[14] anticoagulation serves as a method of prophylaxis and treatment. Anticoagulation may be achieved with unfractionated heparin, low molecular weight heparin (LMWH), or warfarin. Many patients with Trousseau's syndrome have a poor response to warfarin.[14] Recent studies have demonstrated that LMWH provides better control of the thrombosis and hypercoagulability associated with malignancy compared with unfractionated heparin.[14,15]

### Extragonadal Germ Cell Tumors

The origin of primary extragonadal germ cell tumors (EGGCTs) is unclear. Most likely they arise outside the gonads, although there are studies indicating evidence of burnt-out gonadal malignancy in many cases of EGGCT.[16] These cancers are uncommon and represent less than 4% of all germ cell tumors. Typically, EGGCTs arise in midline locations, with the most common sites being the anterior mediastinum, retroperitoneum, and pineal and suprasellar regions. EGGCTs are histologically

classified as teratomas or nonteratomas. The latter include seminomas and malignant nonseminomas. EGGCTs are usually diagnosed in advanced stages, as they remain asymptomatic for long periods of time.[17,18]

## CONCLUSION

The case presented in this article is, to the best of our knowledge, the first reported case of APS as the initial presentation of extragonadal seminoma. The work-up of APS in this case led to early diagnosis of a malignancy at a potentially curable stage. This example serves as a reminder that the differential diagnosis of secondary APS includes occult malignancy and that diagnosis at an early stage can result in a considerably improved prognosis. **HP**

*Corresponding author: Samer Bleibel, MD, 61 Summit Avenue, Quincy, MA 02170; samerableibel@yahoo.com.*

## REFERENCES

1. Muir DF, Stevens A, Napier-Hemy RO, et al. Recurrent stent thrombosis associated with lupus anticoagulant due to renal cell carcinoma. Int J Cardiovasc Intervent 2003;5:44–6.
2. Sato T, Tsujino I, Ikeda D, et al. Trousseau's syndrome associated with tissue factor produced by pulmonary adenocarcinoma. Thorax 2006;61:1009–10.
3. Sallah S, Wan JY, Nguyen NP. Venous thrombosis in patients with solid tumors: determination of frequency and characteristics. Thromb Haemost 2002;87:575–9.
4. Lee AY. Cancer and thromboembolic disease: pathogenic mechanisms. Cancer Treat Rev 2002;28:137–40.
5. Rickles FR, Falanga A. Molecular basis for the relationship between thrombosis and cancer. Thromb Res 2001;102:V215–24.
6. Ohashi S, Yazumi S, Nishio A, et al. Acute cerebral infarction during combination chemotherapy with s-1 and cisplatin for a young patient with a mucin-producing adenocarcinoma of the stomach. Intern Med 2006;45:1049–53.
7. Miesbach W, Scharrer I, Asherson R. Thrombotic manifestations of the antiphospholipid syndrome in patients with malignancies. Clin Rheumatol 2006;25:840–4.
8. Falanga A. Thrombophilia in cancer. Semin Thromb Hemost 2005;31:104–10.
9. Ozkan M, Eser B, Er O, et al. Antiphospholipid syndrome associated with malignant mesothelioma presenting with superior vena cava thrombosis: a case report. Clin Appl Thromb Hemost 2004;10:393–6.
10. Yoon KH, Wong A, Shakespeare T, Sivalingam P. High prevalence of antiphospholipid antibodies in Asian cancer patients with thrombosis. Lupus 2003;12:112–6.
11. Gomez-Puerta JA, Cervera R, Espinosa G, et al. Antiphospholipid antibodies associated with malignancies: clinical and pathological characteristics of 120 patients. Semin Arthritis Rheum 2006;35:322–32.
12. Pierangeli SS, Chen PP, Gonzalez EB. Antiphospholipid antibodies and the antiphospholipid syndrome: an update on treatment and pathogenic mechanisms. Curr Opin Hematol 2006;13:366–75.
13. Olayemi E, Halim NK. Antiphospholipid antibodies in medical practice: a review. Niger J Med 2006;15:7–15.
14. Walsh-McMonagle D, Green D. Low-molecular-weight heparin in the management of Trousseau's syndrome. Cancer 1997;80:649–55.
15. Morita S, Gebska MA, Kakkar AK, Scully MF. High affinity binding of heparin by necrotic tumour cells neutralises anticoagulant activity—implications for cancer related thromboembolism and heparin therapy. Thromb Haemost 2001;86:616–22.
16. Scholz M, Zehender M, Thalmann GN, et al. Extragonadal retroperitoneal germ cell tumor: evidence of origin in the testis. Ann Oncol 2002;13:121–4.
17. Gerl A, Clemm C, Kohl P, et al. [Primary extragonadal germ cell tumors. Clinical manifestations, differential diagnosis and therapy.] [Article in German.] Med Klin (Munich) 1994;89:240–4.
18. Berthold P, Bronnimann M, Wegmuller E. [Primary retroperitoneal seminoma—a rare germ cell neoplasm.] [Article in German.] Schweiz Rundsch Med Prax 2000;89:291–6.

Copyright 2008 by Turner White Communications Inc., Wayne, PA. All rights reserved.