

## Esophageal Dysphagia: Review Questions

Douglas G. Adler, MD

### QUESTIONS

Choose the single best answer for each question.

#### Questions 1 and 2 refer to following case.

A 30-year-old man presents to a gastroenterologist with intermittent dysphagia to solids. Over the past 5 years, he has had 2 episodes of food impaction requiring endoscopic treatment, which he attributed to taking very large bites. He has not followed-up with his physician as recommended. Past medical history reveals childhood asthma, which has resolved. Physical examination is unremarkable. Upper endoscopy shows an esophagus with a ringed appearance and vertical furrows throughout its length (Figure).

#### 1. What is this patient's most likely diagnosis?

- (A) Achalasia
- (B) Eosinophilic esophagitis
- (C) Esophageal candidiasis
- (D) Schatzki's rings
- (E) Scleroderma

#### 2. What is the next step in this patient's management?

- (A) Esophageal biopsy
- (B) Esophageal dilation
- (C) Observation
- (D) Oral fluconazole
- (E) Oral proton pump inhibitor (PPI) therapy

#### 3. A 50-year-old man presents to the emergency department with progressive weight loss and dysphagia. Upper endoscopy reveals a large, fungating, friable mass at the esophagogastric junction, and biopsy reveals adenocarcinoma. Computed tomography shows no distant metastatic lesions. He has no other active medical issues. What is the next best step in this patient's management?

- (A) Referral for chemotherapy
- (B) Referral for combined chemoradiotherapy
- (C) Referral for endoscopic ultrasonography
- (D) Referral for radiotherapy
- (E) Referral for surgical evaluation

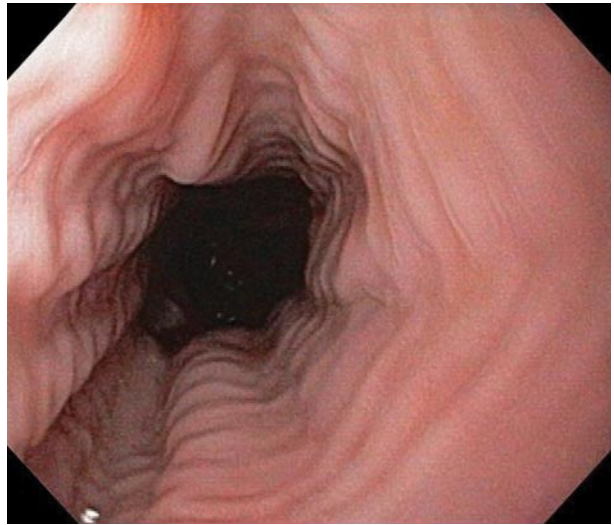


Figure. Upper endoscopy of the patient described in questions 1 and 2 demonstrating an esophagus with a ringed appearance and vertical furrows throughout its length.

#### 4. A 65-year-old man is diagnosed with esophageal adenocarcinoma via upper endoscopy, which was performed for evaluation of dysphagia. Computed tomography demonstrates multiple hepatic lesions consistent with metastatic cancer. He has severe solid food dysphagia and can only swallow liquids, albeit with some difficulty. Given the patient's advanced disease, he is not considered a candidate for surgery. What is the best treatment for this patient's dysphagia?

- (A) Endoscopic balloon dilation of the tumor
- (B) Endoscopic laser therapy
- (C) Placement of a gastrostomy tube for tube feeds and gastric venting
- (D) Placement of a jejunostomy tube for tube feeds
- (E) Placement of an esophageal stent

---

Dr. Adler is an assistant professor of medicine and Director of Therapeutic Endoscopy, Department of Gastroenterology and Hepatology, Huntsman Cancer Center, University of Utah, Salt Lake City, UT.

**Questions 5 and 6 refer to the following case.**

A 32-year-old man presents to his primary care physician for evaluation of dysphagia to both solids and liquids. He reports that he has had this problem for several years, but symptoms have been worsening. He often leaves the table to regurgitate food that he cannot swallow. On several recent occasions, he has awakened at night to find undigested food on his pillow.

**5. What is the most likely underlying diagnosis in this patient?**

- (A) Achalasia
- (B) Esophageal adenocarcinoma
- (C) Esophageal squamous cell carcinoma
- (D) Schatzki's ring
- (E) Zenker's diverticulum

**6. Given the underlying diagnosis, the patient is at increased risk for which of the following conditions?**

- (A) Esophageal gastrointestinal stromal tumor (GIST)
- (B) Esophageal squamous cell carcinoma
- (C) Gastric adenocarcinoma
- (D) Gastric GIST
- (E) Gastroesophageal reflux disease

**7. A 50-year-old woman with long-standing scleroderma presents to her primary care physician with dysphagia and chest pain after eating. A barium swallow demonstrates an atonic esophagus with a widely patent lower esophageal sphincter with free reflux of gastric contents into the esophagus. Upper endoscopy confirms these findings and reveals severe distal esophagitis. Based on findings from the barium swallow and upper endoscopy, scleroderma esophagus is suspected. What is the best treatment option for this patient?**

- (A) Aggressive antireflux regimen
- (B) Daily calcium channel blockers
- (C) Placement of a gastrostomy tube
- (D) Surgical referral for a Nissen fundoplication
- (E) Surgical referral for a Toupe fundoplication

**ANSWERS AND EXPLANATIONS**

**1. (B) Eosinophilic esophagitis.** Eosinophilic esophagitis commonly presents with recurrent dysphagia, often with food impactions. Many patients have a history of prior or concurrent asthma, food allergies, or eczema. Endoscopic findings may include a ringed esophagus, vertical furrows, small white plaques, and friable mucosa; however, some patients have a normal-appearing esophagus. In achalasia, endos-

copy would demonstrate a dilated esophagus with a tight lower esophageal sphincter. Scleroderma would present with a pipe-like esophagus and severe erosive esophagitis. Large, raised, yellow-white plaques would be evident on endoscopy if the patient had esophageal candidiasis. Schatzki's rings can cause solid food dysphagia but rarely produce food impaction.

**2. (A) Esophageal biopsy.** The patient's esophagus should be biopsied to confirm the suspected diagnosis of eosinophilic esophagitis. A high concentration (> 15–20) of eosinophils per high-power field is characteristic of eosinophilic esophagitis.<sup>1</sup> Observation alone would be inadequate given this patient's ongoing symptoms. There is no mechanical obstruction and therefore dilation would not be helpful. PPI therapy could be started, but the underlying disease process is not due to acid exposure. Fluconazole is a treatment for candidiasis, which this patient does not appear to have.

**3. (C) Referral for endoscopic ultrasonography.** The patient does not have obvious metastatic cancer and may be a candidate for surgery. However, it is too early to determine if surgery would be appropriate because more information regarding the tumor should be obtained. Endoscopic ultrasonography will allow more complete locoregional staging (ie, T and N staging of the tumor; assess for depth of tumor invasion, and determine presence or absence of malignant lymph nodes). Endoscopic ultrasound can also be used to sample suspicious peritumoral lymph nodes via fine-needle aspiration. Patients found to have advanced local disease (deep tumor invasion into or through the esophageal wall) and/or malignant adenopathy are typically referred for neoadjuvant therapy in an effort to decrease tumor burden prior to operative therapy.

**4. (E) Placement of an esophageal stent.** Endoscopic stents are the current mainstay of therapy for malignant dysphagia for unresectable esophageal cancer. Modern endoscopic stents are self-expanding and are almost universally coated to avoid tissue ingrowth through the stent interstices. Most patients with esophageal stents experience marked and rapid improvement in dysphagia, although such devices are not without the risk of complications (eg, perforation, bleeding). Gastrostomy or jejunostomy tubes are possible management options but would not allow a return to oral feeding, which would be preferable. Laser therapy is effective but is rarely

performed. Lasers are currently not widely available, and patients often need multiple sessions of treatment to relieve dysphagia. Balloon dilation works well for benign esophageal strictures but is largely ineffective for malignant stenoses.

5. **(A) Achalasia.** The patient has dysphagia to both solids and liquids, which suggests a motility disorder rather than a mechanical or obstructive process such as a tumor or ring. Zenker's diverticulum, a cricopharyngeal outpouching that can trap food, could produce some of the symptoms seen in this patient (ie, regurgitation) but would be unlikely to cause such profound dysphagia, especially to liquids. Zenker's diverticulum is often associated with aspiration pneumonia, which this patient does not have. In patients with achalasia, the esophagus becomes aperistaltic and the lower esophageal sphincter fails to relax with swallowing. This produces significant dysphagia to solids and liquids as well as trapping of food in the esophagus that often leads to regurgitation, especially when recumbent.
6. **(B) Esophageal squamous cell carcinoma.** Achalasia is a premalignant condition and a risk factor for the development of esophageal squamous cell

carcinoma. Achalasia may also increase the risk for esophageal adenocarcinoma. However, achalasia is associated with decreased risk of gastroesophageal reflux disease because the hypertensive lower esophageal sphincter retards acid reflux into the esophagus. GISTs and gastric adenocarcinoma are not associated with achalasia.

7. **(A) Aggressive antireflux regimen.** Patients with scleroderma often develop severe esophageal hypomotility and a hypotensive lower esophageal sphincter, which often leads to gastroesophageal reflux and esophagitis. An aggressive antireflux regimen with PPIs can treat this patient's reflux esophagitis and reduce the risk of developing an esophageal stricture as a consequence of unchecked esophagitis. Surgical fundoplication may worsen dysphagia and is not recommended. A gastrostomy tube would not improve this patient's reflux and would not allow the patient to eat. Calcium channel blockers may help patients with spastic esophageal disorders but are of little use in patients with scleroderma.

#### REFERENCE

1. Baxi S, Gupta SK, Swigonski N, Fitzgerald JF. Clinical presentation of patients with eosinophilic inflammation of the esophagus. *Gastrointest Endosc* 2006;64:473–8.

#### SELF-ASSESSMENT QUESTIONS ON THE WEB

Now you can access the entire self-assessment series on the Web. Go to [www.turner-white.com](http://www.turner-white.com), click on the "Hospital Physician" link, and then click on the "Board-Type Questions" option.

Copyright 2008 by Turner White Communications Inc., Wayne, PA. All rights reserved.