Ventricular Tachycardia with Stokes-Adams Attack

Hongya Song, MD, MS
Anthony P. Geraci, MD

CASE PRESENTATION

Initial Presentation and History

A 77-year-old woman presented to the emergency department complaining of left-sided weakness and facial droop for more than 12 hours. The patient denied headache, incontinence, nausea, vomiting, fever, loss of consciousness, palpitations, chest pain, or shortness of breath. Past medical history included hypertension, diabetes mellitus, diabetic neuropathy, cerebrovascular accident, anemia, and multiple myeloma. The patient had recently completed 5 days of second-cycle chemotherapy for multiple myeloma that included arsenic trioxide. Medications included oxycodone, multivitamins, acetaminophen, senna, gabapentin, metformin, calcium D, erythropoietin, clopidogrel, carvedilol, citalopram, thalidomide, and risedronate. She had no history of seizures or syncope.

Physical Examination

On physical examination, the patient was alert and cooperative. She was afebrile, and her vital signs were blood pressure, 84/50 mm Hg; heart rate, 64 bpm; and respiratory rate, 16 breaths/min. Fingerstick blood glucose was 243 mg/dL, and oxygen saturation by pulse oximetry was 97% on 2 L oxygen by nasal cannula. Her pupils were equal, round, and reactive to light. Lungs were clear, and auscultation of the heart revealed a normal S_1 and S_2 without murmur or gallop. Abdominal examination was unremarkable. Neurologic examination revealed a supple neck without carotid bruits and a left facial droop. Muscle strength was 2/5 in the left lower extremity and 4/5 in the left upper extremity. She exhibited a mild dysarthria, but language and higher cortical functions were normal. Laboratory findings were as follows: sodium, 129 mEq/L (normal, 136–145 mEq/L); potassium, 5.5 mEq/L (normal, 3.5–5.1 mEq/L); bicarbonate, 19 mEq/L (normal, 23–29 mEq/L); glucose, 229 mg/dL (normal, 74–106 mg/dL); blood urea nitrogen, 50 mg/dL (normal, 10–26 mg/dL); calcium, 7.1 mg/dL (normal, 7.6–10 mg/dL); and myoglobin, 145 ng/mL (normal, 0–110 ng/mL).

Imaging Studies and Diagnosis

Chest radiograph showed cardiomegaly with an atherosclerotic and tortuous aorta. Magnetic resonance imaging (MRI) of the head showed a small area of increased signal intensity in the right frontal subcortical area, with a corresponding area of diffusion-weighted increased signal indicating a small subacute/acute cerebral infarction. Slight dilatation of the ventricles and subarachnoid space along with white matter ischemic changes were also noted.

The patient was diagnosed with an acute cerebral infarction of the right middle cerebral artery and was admitted to the acute stroke unit. Intravenous (IV) heparin drip was administered, and routine laboratory and cardiovascular tests were performed to determine the etiology of her stroke.

Clinical Course

On hospital day 3, the patient experienced 3 episodes of "seizures," each lasting 30 to 40 seconds and witnessed by the stroke unit nurses. The fourth episode of "seizure" was witnessed by a resident who observed that the patient snored loudly and became cyanotic with apparent difficulty breathing and a brief loss of consciousness followed by flushing. No ictal scream or tonic-clonic muscle movements were seen or heard. Immediately after each event, the patient rapidly returned to baseline and was fully alert and oriented. A Foley catheter precluded incontinence, and no tongue bite was noted. The cardiac monitor documented ventricular tachycardia during each episode lasting between 10 and 30 seconds (**Figure 1** and **Figure 2**). Because each episode of ventricular tachycardia lasted no more than 40 seconds, blood pressure measurements could not be taken. After each tachycardic episode spontaneously converted back to sinus rhythm, sonorous breathing and the other observed features

Dr. Song is an internal medicine resident, Lutheran Medical Center, Brooklyn, NY. Dr. Geraci is a clinical assistant professor of neurology, Mount Sinai School of Medicine, New York, NY, and attending neurologist, Lutheran Medical Center.

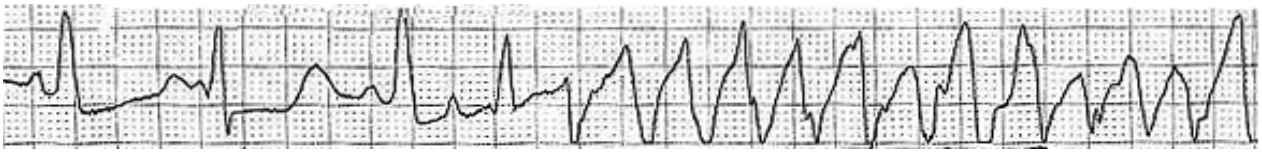

Figure 1. A cardiac monitor rhythm strip recorded during Stokes-Adams attack in the case patient.

suggestive of seizure activity ceased within a few seconds. Repeat laboratory testing included an analysis of serum electrolytes, which were normal except for bicarbonate, 16 mEq/L; chloride, 112 mEq/L (normal, 98–106 mEq/L); glucose, 165 mg/dL; calcium, 6.1 mg/dL; magnesium, 1.4 mg/dL (normal, 1.5–2.6 mg/dL); and phosphorous, 2.1 mg/dL (normal, 2.7–4.5 mg/dL). Blood pressure after each episode was 120/60 mm Hg.

A cardiologist and neurologist were present to witness the clear temporal relationship between symptoms, signs, and electrocardiographic changes during one of the attacks, prompting a consideration of Stokes-Adams phenomenon. Amiodarone 150 mg was administered intravenously over 10 minutes followed by IV amiodarone drip (1 mg/min), during which time the patient had no recurrence. Because there was only one IV line, amiodarone was discontinued after approximately 40 minutes and IV magnesium sulfate was started. Approximately 25 minutes later, a recurrent Stokes-Adams attack occurred. Amiodarone 150 mg was again administered intravenously over 10 minutes followed by IV amiodarone drip (1 mg/min).

The patient had no additional attacks. She was transferred to another hospital for electrophysiologic study before an electroencephalogram (EEG) could be performed. It was hypothesized that ventricular tachycardia caused impaired consciousness and pseudoseizure, as the patient did not have a Stokes-Adams attack after amiodarone was administered but experienced recurrent attacks when amiodarone was discontinued.

DISCUSSION

A Stokes-Adams attack is described as collapse from any posture without warning associated with disturbance of consciousness for several seconds. The condition is characterized by sudden transient episodes of lightheadedness or unconsciousness, with or without convulsions, and is thought to be due to a temporary cessation of blood supply to the brain. Most Stokes-Adams attacks are caused by complete or incomplete heart block due to disturbances of the conductive pathway of the heart,[1] but the condition has also been described in association with other diseases, such as tachy-brady syndrome or, rarely, ventricular tachycardia.[2] Initially, the affected individual is pale and pulseless but may become flushed upon recovery from the episode (as seen in the case patient). This flushing is due to stasis of well-oxygenated blood in the pulmonary capillaries during the period of circulatory arrest, which on recovery is pumped into systemic capillaries that are widely dilated as a result of accumulated vasodilator metabolites. In addition, seizure-like activity (eg, ictal scream, tonic-clonic muscle movements, incontinence) may be noted if the attack is prolonged.

As with all cases of syncope or transient loss of consciousness, the differential diagnosis for Stokes-Adams attacks is broad and includes conditions that may require immediate medical attention (**Table**). A detailed case history including description of the first and subsequent attacks, additional medical problems, and potential culprit medications must be obtained from patients, family members, and witnesses. A thorough physical examination that includes blood pressure measurement and cardiovascular and neurologic examinations should be performed. In addition, a 12-lead electrocardiogram (ECG), EEG, and routine hematologic and biochemical testing may identify potential contributory disorders, such as seizures, hypoglycemia, cardiac arrhythmia, or cardiopulmonary disorders. Echocardiography, Holter monitoring, or brain MRI or computed tomography may aid in the diagnosis of aortic stenosis, atrial myxoma, or hypertrophic cardiomyopathy. Psychiatric disorders may also cause transient loss of consciousness and characteristically occur or recur in the presence of observers or in emotionally charged situations, rarely resulting in physical injury to the patient.

Arsenic trioxide has been implicated as a cause of Stokes-Adams attacks[3] and had been administered to the case patient. Arsenic trioxide is used to induce remission and consolidation in patients with acute promyelocytic leukemia and multiple myeloma. This drug can cause tachycardia and prolonged QT interval or can lead to torsades de pointes or complete atrioventricular block. Risk factors for torsades de pointes include congestive heart failure, a history of torsades de pointes, pre-existing QT-interval prolongation, use of potassium-wasting diuretics, and conditions that cause hypokalemia or hypomagnesemia.[4] Ischemic middle cerebral artery stroke may also cause cardiac arrhythmia. Christensen et al[5] reported that insular

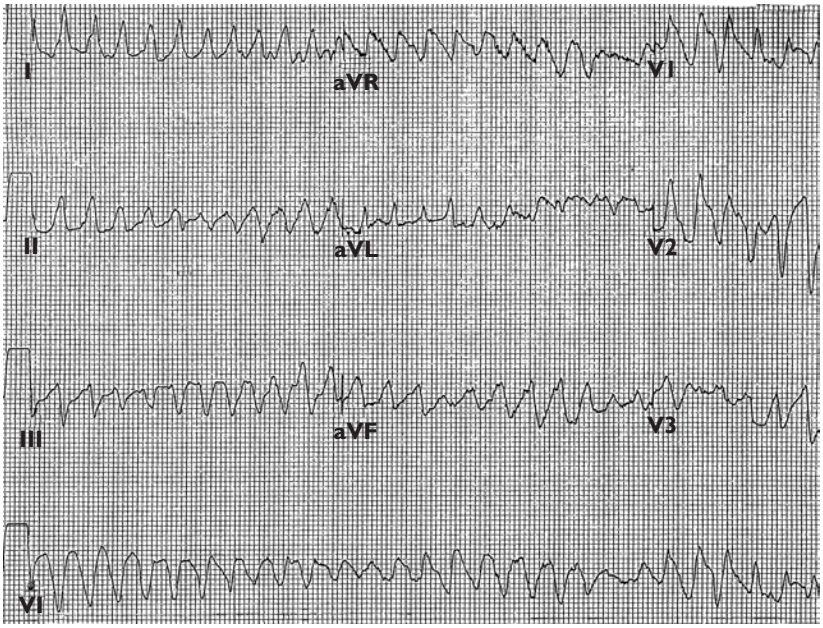

Figure 2. 12-Lead electrocardiogram showing ventricular tachycardia during Stokes-Adams attack in the case patient.

Table. Differential Diagnosis of Patients Presenting with Stokes-Adams Attack

Neurologic	Metabolic
Seizures	Hypoglycemia
Transient ischemic attacks	Psychiatric
Raised intracranial pressure	Panic attacks
Narcolepsy or cataplexy	
Cardiopulmonary	
Aortic stenosis	
Atrial myxoma	
Hypertrophic cardiomyopathy	

lesions were related to sinus tachycardia with heart rate greater than 120 bpm, ectopic beats greater than 10%, and ST-segment elevation.

First described by Holter in 1961,[6] continuous cardiac monitoring has greatly enhanced our understanding of the precise cardiac mechanism leading to Stokes-Adams attacks. The development of portable EEG recording proved more difficult than Holter monitoring because of the need for signal amplification and multichannel recording. In the past decade, however, computer technology has enabled portable recording of more than 16 channels with sampling rates of over 200 Hz.[7] EEG monitoring may be warranted in a number of clinical scenarios, including evaluating fainting spells in which routine EEGs are inconclusive, evaluating confirmed epileptics experiencing suspected nonepileptic events, evaluating suspected epileptics with poorly documented seizures, monitoring while adjusting antiepileptic medication levels, evaluation prior to withdrawal of medication, localizing seizure focus for enhanced medical management or surgical consideration, evaluating episodic events in which pseudoseizures are suspected, and differentiating between neurologic and cardiac problems.[8]

Simultaneous ECG and EEG recordings are valuable tools in the diagnosis and treatment of patients with unexplained episodes of disturbed consciousness and in patients with tonic anoxic seizures caused by cardiac arrhythmias.[9–11] Early diagnosis is essential so that effective, potentially life-saving treatments can be initiated quickly. Blumhart[12] showed that 25% of tonic anoxic seizures due to a cardiac arrest and brainstem hypoperfusion may have been misdiagnosed and treated as generalized motor seizures.

SUMMARY

Stokes-Adams attacks are triggered by cardiac arrhythmias; however, the clinical presentation of Stokes-Adams attacks may mistakenly point to a diagnosis of seizure. Stokes-Adams attacks caused by ventricular tachycardia are rarely reported. This case demonstrates a temporal relationship between cardiac rhythm and a Stokes-Adams attack, which resulted in seizure-like activity following transient cessation of cerebral blood flow. Although simultaneous ECG and EEG recordings were not obtained during the case patient's attacks, vigilant observation allowed for the correct diagnosis of Stokes-Adams attack and subsequent treatment. **HP**

REFERENCES

1. Shua-Haim J, Gross JS. Geriatrics photo quiz. Stokes-Adams attack. Geriatrics 1997;52:75.
2. Osler W. Stokes-Adams disease. Ann Noninvasive Electrocardiol 2002;7:79–81.
3. Venkataraman V, Wheless JW, Willmore LJ, Motookal H. Idiopathic cardiac asystole presenting as an intractable adult onset partial seizure disorder. Seizure 2001;10: 359–64.
4. Olson KR. Poisoning and drug overdose. 4th ed. Philadelphia: McGraw-Hill Medical; 2004:115–9.
5. Christensen H, Boysen G, Christensen AF, Johannesen HH. Insular lesions, ECG abnormalities, and outcome in acute stroke. J Neurol Neurosurg Psychiatry 2005; 76:269–71.
6. Holter NJ. New method for heart studies. Science 1961; 134:1214–20.
7. Morris GL. The clinical utility of computer-assisted ambulatory 16 channel EEG. J Med Eng Technol 1997;21: 47–52.
8. Guideline twelve: guidelines for long-term monitoring for epilepsy. American Electroencephalographic Society. J Clin Neurophysiol 1994;11:88–110.
9. Lai CW, Ziegler DK. Syncope problem solved by continuous ambulatory simultaneous EEG/ECG recording. Neurology 1981;31:1152–4.
10. Pitney MR, Beran RG, Jones A. A simultaneous electrocardiogram is important when electroencephalography is used in the evaluation of loss of consciousness. Electroencephalogr Clin Neurophysiol 1994;90:246–8.
11. Diaz-Castro O, Orizaola P, Vazquez S, et al. Images in cardiovascular medicine. "Stokes-adams epilepsy": sometimes we need the electroencephalogram. Circulation 2005;112:e101–2.
12. Blumhart LD. Ambulatory ECG and EEG monitoring in the differential diagnosis of cardiac and cerebral dysrhythmias. In: Gumnit RJ, editor. Intensive neurodiagnostic monitoring. New York: Raven Press; 1986:183–202.

Copyright 2006 by Turner White Communications Inc., Wayne, PA. All rights reserved.

WHAT WAS YOUR MOST MEMORABLE CODE BLUE?

Real-life stories are sometimes more bizarre than fiction, yet they leave us with a profound lesson about the unique and fragile balance between life and death and the role of medicine within this context.

In a few paragraphs (less than 700 words), send us your most unusual, difficult, or humorous story of a code blue (resuscitative effort) in which you were involved. Include any long-term reflections that you may have about the case, or share with us the humor of the moment. You may discuss an event that took place in your first days of residency or one that occurred just yesterday. The story may have taken place on a back road or in a hospital cafeteria. Whatever or wherever it was, we want to know.

Please send us your most interesting personal stories. Submissions should include the author's name, address, phone and fax numbers, and e-mail address if available. We'll maintain your anonymity if you wish. The best stories will be selected for publication.

Send your submission to: Code Blue, *Hospital Physician*
125 Strafford Avenue, Suite 220, Wayne, PA 19087-3391
fax: (610)975-4564 or e-mail to: hp@turner-white.com