Syndromes of Bronchiolitis

Sat Sharma, MD

The term *bronchiolitis* refers to a group of diverse clinical disorders that share a common instigating mechanism: inflammatory injury to the small airways.[1] Lange[2] in 1901 first used the term *bronchiolitis obliterans* in describing 2 cases of interstitial bronchiolar disorder, and the following year, Fraenkel[3] reported a case of airway bronchiolar disorder caused by nitrogen oxide inhalation. Over the years, bronchiolar disorders have been increasingly recognized by clinicians, radiologists, and pathologists, and many variations of these disorders have been described. In the literature, interchangeable terminology, numerous classification systems, and overlap between histopathologic lesions and clinical syndromes have contributed to confusion surrounding bronchiolitis.[4] The terms used to refer to these disorders can be confusing as they are often used to describe both the clinical syndromes and their histopathologic manifestations.[5,6] In addition, multiple terms may refer to the same clinical entity (eg, constrictive bronchiolitis, bronchiolitis obliterans, and obliterative bronchiolitis). Given this sometimes baffling terminology as well as the recent increase in knowledge of the bronchiolitis syndromes, these disorders can pose a challenge to the practicing clinician.[7–10] A recent classification scheme has helped categorize these disorders into 2 disparate groups: airway and interstitial bronchiolar disorders. This article reviews the causes of these unique syndromes and discusses in detail the 2 prototypes belonging to each category: constrictive bronchiolitis and cryptogenic organizing pneumonia.

TAKE HOME POINTS

- The syndromes of bronchiolitis comprise a heterogeneous group of etiologically, clinically, and pathologically disparate lesions of the small conducting airways.
- Constrictive bronchiolitis is an irreversible concentric fibrotic process in the bronchiolar submucosal layer with external circular scarring. The clinical features of constrictive bronchiolitis (bronchiolitis obliterans) consist of a chest radiograph that is often normal, early inspiratory crackles, and irreversible airflow obstruction by pulmonary function testing.
- Bronchiolitis obliterans organizing pneumonia (BOOP) is a histopathologic lesion characterized by the presence of buds of granulation tissue within the alveolar lumen, usually associated with proliferative bronchiolitis obliterans.
- BOOP may result from several causes, but cryptogenic organizing pneumonia is a distinct clinicopathologic entity with characteristic clinical and imaging features.
- While treatment of bronchiolitis obliterans is unsatisfactory, the response to corticosteroids is rapid and complete in cryptogenic organizing pneumonia. However, relapses occur frequently and prolonged corticosteroid treatment is often necessary.

ROLE OF THE BRONCHIOLES IN DISEASE

Bronchioles are small airways (< 2 mm in diameter) that lack cartilage and submucosal glands. The gas exchange unit of the lung, or acinus, comprises respiratory bronchioles, alveolar ducts, and alveoli. The terminal bronchiole, a 16th generation airway, is the final conducting airway that terminates into the respiratory bronchioles. The bronchiolar lining consists of surfactant-secreting Clara cells and the neuroendocrine cells that are the source of bioactive products such as somatostatin, endothelin, and serotonin. Injured bronchiolar epithelium may play a role in the bronchiolar disease process.[11]

The small airways of the lungs were initially considered to be a quiet zone but are now known to play an important pathophysiologic role in asthma, chronic obstructive pulmonary disease (COPD), and bronchiolar disorders. The small airways are pathways of low resistance and normally contribute about 10% of the total resistance to flow; therefore, a sizeable affliction of the small airways is a prerequisite for the development of symptoms. More recently, computational analyses based

Dr. Sharma is professor and head, Section of Pulmonary Medicine, Department of Internal Medicine, University of Manitoba, Winnipeg, MB.

Table 1. Histopathologic Classification of Bronchiolitis

Airway lesions
Constrictive bronchiolitis
Cellular bronchiolitis
Diffuse panbronchiolitis
Follicular bronchiolitis
Mineral dust bronchiolitis
Respiratory bronchiolitis
Interstitial lesions
Bronchiolitis obliterans organizing pneumonia
Hypersensitivity pneumonitis
Respiratory bronchiolitis-associated interstitial lung disease

on quantitative histology have shown that the small airways account for the majority of airway hyperresponsiveness among patients with asthma.[12] Similarly, inflammation in small airways is said to be a determinant of the progression and severity of disease in COPD. Multiple mechanisms limit airflow in small airways, including disruption of alveolar attachments, thickening of the airway wall by an inflammatory cell infiltrate or structural changes, and occlusion of airway lumen by mucous secretions.[13] Narrowing of small airways results in hyperinflation of the lungs, which are unable to empty; this effect in turn results in dyspnea on exertion and, eventually, even at rest.

CLASSIFICATION

The pathogenesis of the bronchiolitis syndromes is poorly understood. It is believed that the diverse histopathologic and clinical syndromes of bronchiolitis are the sequelae of injury to the bronchiolar epithelium and alveoli adjacent to the small airways and the interaction of inflammatory and mesenchymal cells during the repair process that follows the initial injury.[14,15] The repair process may result in inflammatory/fibrosing changes within the small airways that are characterized by 2 broad histologic patterns: peribronchiolar fibrosis that surrounds the lumen, resulting in extrinsic narrowing or obliteration of the lumen ("constrictive" pattern), and proliferation of granulation tissue that fills the lumen of the bronchioles ("interstitial proliferative" pattern).[5,6,9]

The injury of membranous and respiratory bronchioles and the ensuing repair process gone awry will result in 1 of 2 broad clinical patterns: a syndrome of constrictive bronchiolitis with airflow obstruction, or a syndrome of proliferative bronchiolitis with ventilatory restriction. A system to classify these disorders according to the underlying histopathologic lesion has been proposed by Colby and Myers,[5] who classified bronchiolar disorders into 2 clinicopathologic syndromes: airway bronchiolar disorders and interstitial bronchiolar disorders (**Table 1**). These disorders have characteristic clinical presentation, physiologic and radiologic features, treatment, and outcome.

Airway Bronchiolar Disorders

Several patterns of primary bronchiolitis have been described. These include constrictive bronchiolitis/bronchiolitis obliterans, acute bronchiolitis, diffuse panbronchiolitis, respiratory bronchiolitis, mineral dust airway disease, follicular bronchiolitis, and aspiration bronchiolitis. These histologically distinct disorders can occur in dissimilar clinical settings. For example, constrictive bronchiolitis may occur in patients with connective tissue diseases, transplant recipients, and in an idiopathic form (cryptogenic constrictive bronchiolitis). Constrictive bronchiolitis is the prototypical airway bronchiolar process associated with airflow obstruction.

Interstitial Bronchiolar Disorders

Many parenchymal lung diseases can involve the bronchioles with varying degrees of inflammation and scarring. Pulmonary function testing and high-resolution computed tomography (HRCT) of the chest demonstrate primarily an interstitial process with evidence of bronchiolar involvement. These disorders include hypersensitivity pneumonitis, respiratory bronchiolitis-associated interstitial lung disease (RB-ILD), and cryptogenic organizing pneumonia/idiopathic bronchiolitis obliterans organizing pneumonia (BOOP).

Disorders with Mixed Lesions

Despite attempts to neatly classify bronchiolar disorders as airway or interstitial, it is important to remember that both airway and interstitial bronchiolar lesions can occur in some forms of bronchiolitis. Cellular and follicular bronchiolitis are such disorders where an overlap exists and the clinical manifestation could be obstructive, restrictive, or a mixed obstructive and restrictive physiology on pulmonary function testing. Cellular bronchiolitis is an acute or chronic inflammation of the bronchioles; the inflammation may be submucosal, mural, or peribronchiolar. It is characterized by the presence of an inflammatory cellular infiltrate involving both the bronchiolar lumen and the wall and therefore can present either as an airway bronchiolar or interstitial disorder. Subtypes of cellular bronchiolitis are infectious bronchiolitis, hypersensitivity pneumonitis, follicular bronchiolitis, diffuse panbronchiolitis, and aspiration bronchiolitis. *Follicular bronchiolitis* is a

descriptive term for a subset of cellular bronchiolitis associated with lymphoid hyperplasia and reactive germinal centers along the small airways and bronchioles.

Diffuse panbronchiolitis is a rare form of bronchiolitis that has been described in Japanese adults with purulent sputum, dyspnea, and airflow obstruction. These patients are colonized with *Pseudomonas aeruginosa* and have inexorable progression of disease. On HRCT, the disease is characterized by a "tree-in-bud" appearance and centrilobular nodules.[9,10] Respiratory bronchiolitis is a smoking-related small airways disease often found at autopsy in young cigarette smokers. There is prominent accumulation of pigmented macrophages in the lumen of respiratory bronchioles and adjacent alveoli. When symptomatic diffuse parenchymal lung infiltrates occur, the syndrome is referred to as RB-ILD.[15] Mineral dust exposure is generally associated with restrictive lung disease due to parenchymal fibrosis; however, mineral dusts can also produce abnormalities in the small airways and airflow obstruction. Inhaled dust primarily affects respiratory bronchioles and sometimes alveolar ducts with increased fibrous tissue in the walls of the bronchioles with luminal narrowing.[9,10] Diffuse aspiration bronchiolitis refers to chronic inflammation of bronchioles caused by recurrent aspiration of foreign particles in elderly and bedridden patients.

The most common form of bronchiolitis is acute bronchiolitis, an illness most frequently seen in infants and children. It is an infectious and inflammatory disease of the upper and lower respiratory tract that results in obstruction of the small airways. Respiratory epithelial necrosis is followed by proliferation of goblet cells and excessive mucus production.[16] There is epithelial regeneration, lymphocytic infiltration, and cellular recruitment into infected airways. Obstruction of bronchioles from inflammation, edema, and debris leads to hyperinflation, increased airway resistance, atelectasis, and ventilation-perfusion mismatching. Although acute bronchiolitis may occur in all age groups, severe respiratory symptoms are usually limited to young infants because of their small airways, high closing volumes, and insufficient collateral ventilation.

APPROACH TO EVALUATION

History and Physical Examination

In bronchiolar disorders, it is imperative to integrate the clinical and radiologic manifestations with pathologic findings to make an accurate diagnosis.[17–19] Patients with bronchiolar disorders usually present with exertional dyspnea and gradually progress to dyspnea at rest. Nonproductive cough is another common feature, although copious expectoration can be a feature of diffuse panbronchiolitis. A detailed history should be obtained to elicit any features of connective tissue diseases as well as identify exposure to inhalational irritants, drugs, and radiation. While BOOP is commonly an idiopathic disorder, an etiologic agent often can be identified in patients with constrictive bronchiolitis (**Table 2** and **Table 3**). On physical examination, clubbing is not seen. Inspiratory wheeze may be heard in patients with bronchiolitis obliterans, whereas crackles may be present in BOOP.

Table 2. Clinical (Etiologic) Classification of Airway Bronchiolar Disorders

Idiopathic
Postinfectious
Viral (respiratory syncytial virus, adenovirus, influenza, parainfluenza)
Mycoplasma
Drug-related
Penicillamine
Gold
Rheumatologic or connective-tissue disorders
Rheumatoid arthritis
Eosinophilic fasciitis
Systemic lupus erythematosus
Bone marrow transplantation
Lung transplantation
Fumes or oral toxin exposure
Sulfur dioxide, ammonia, chlorine, phosgene, nitrogen dioxide, mustard gas
Sauropus androgynous, diacetyl from butter flavoring
Miscellaneous
Ulcerative colitis
Stevens-Johnson syndrome
Neuroendocrine cell hyperplasia/carcinoid tumorlets
Chronic aspiration

Pulmonary Function Tests

Patients with airway bronchiolar disorders demonstrate an obstructive pattern with no significant bronchodilator response. The interstitial bronchiolar disorders typically have a restrictive pattern with a reduction in lung volumes and diffusing capacity. Small airway function is difficult to assess with simple spirometry as patients are often asymptomatic and forced expiratory volume in 1 second is normal. However, lung function tests such as maximal mid-expiratory flow rate, forced expiratory flow 25%–75%, frequency dependence of

Table 3. Clinical (Etiologic) Classification of Interstitial Bronchiolar Disorders

Respiratory bronchiolitis-associated interstitial lung disease
Hypersensitivity pneumonitis
Bronchiolitis obliterans organizing pneumonia
Idiopathic
Postinfectious
Adenovirus
Chlamydia
Cytomegalovirus
Influenza
Legionella
Mycoplasma
Drug-related
Amiodarone
Bleomycin
Gold
Rheumatologic or connective-tissue disorders
Dermatomyositis
Rheumatoid arthritis
Sjögren's syndrome
Systemic lupus erythematosus
Bone marrow transplantation
Lung transplantation
Miscellaneous
Chronic thyroiditis
HIV infection
Inflammatory bowel disease
Lymphoma and cancer
Radiation therapy
Seasonal syndrome with cholestasis
Tryptophan

Table 4. Patterns of Lung Involvement on High-Resolution Computed Tomography in Bronchiolitis

Bronchiolar disease with tree-in-bud pattern
Infections (bacterial, *Mycoplasma, Chlamydia,* tuberculosis, cytomegalovirus, pneumocystis pneumonia)
Diffuse panbronchiolitis
Bronchiolar disease with diffuse centrilobular nodules
Hypersensitivity pneumonitis, respiratory bronchiolitis-associated interstitial lung disease, follicular bronchiolitis, lymphocytic interstitial pneumonitis
Bronchiolar disease with decreased lung attenuation
All causes of airway bronchiolar disorders (*see* Table 2)
Bronchiolar disease with ground-glass opacity and/or consolidation
All causes of interstitial bronchiolar disorders (*see* Table 3)

compliance, and closing volume can detect abnormalities in the small airways. Frequency dependence of compliance, also called dynamic compliance, measures lung compliance in patients at a higher breathing frequency. The alveoli distal to the affected small airways fill and empty slowly but have sufficient time to empty at a slow breathing frequency.[13] However, at a higher breathing frequency these units trap air and contribute to reduced compliance. Closing volume is defined as the lung volume at which the airways in the dependent part of the lungs begin to close. Small airways disease predisposes abnormal airways to close at a higher volume compared with the normal lung.

An alternative approach to assessing small airways disease measures airway resistance (Raw) using body plethysmography or total respiratory system resistance (Rrs) using the forced oscillation technique or impulse oscillometry system. All 3 methods should be able to detect bronchiolitis and expiratory flow limitation in early COPD, although these tests are only available at specialized centers.

Radiologic Evaluation

Plain chest radiograph is usually normal in patients with bronchiolitis obliterans; however, hyperinflation, attenuation of peripheral vascular markings, and reticulonodular infiltrates may be seen. Bilateral patchy infiltrates are generally seen in interstitial bronchiolar disorders. HRCT scan plays a critical role in the diagnosis of bronchiolar disorders. When interpreting an HRCT scan in a patient with suspected bronchiolitis, 2 questions need to be asked: Does the patient have bronchiolar disease, and what is the pattern of involvement? Bronchiolar disease on HRCT can be identified by either direct or indirect signs. Direct findings include bronchiolar wall thickening, bronchiolar dilatation, and luminal impaction. Centrilobular nodules or a tree-in-bud pattern denotes bronchiolitis or bronchiolectasis. Indirect signs on HRCT include subsegmental atelectasis and air trapping. Patterns of lung involvement associated with particular bronchiolar disorders are shown in **Table 4**.

Lung Biopsy

After a detailed history and physical examination, pulmonary function testing, and HRCT, most patients can be categorized either as having airway bronchiolar disorder or interstitial bronchiolar disorder. A specific etiology also can be identified in most cases. A lung biopsy is rarely required in airway bronchiolar disorder, whereas in interstitial bronchiolar disorders,

lung biopsy is often necessary, especially in patients with an atypical presentation. Transbronchial biopsy is an insensitive diagnostic tool because of the patchy involvement of the lungs in bronchiolitis. Therefore, a surgical or thoracoscopic lung biopsy is necessary for histologic confirmation.

AIRWAY BRONCHIOLAR DISORDERS

Airway bronchiolar disorders encompass clinical entities that involve acute or chronic bronchiolar inflammation. The nonspecific inflammation may be submucosal, mural, or peribronchiolar. The histologic lesions may vary from mild inflammation to concentric fibrosis and complete obliteration of the airway lumen.[18,19]

Constrictive Bronchiolitis

Constrictive bronchiolitis (clinically referred to as bronchiolitis obliterans) is a histopathologic lesion that is characterized by obliteration of the bronchioles with concentric, mural, or adventitial scarring. Acute and chronic inflammation of the airway is evident surrounded by normal lung parenchyma. Most types of airway bronchiolar disorder exhibit constrictive bronchiolitis, although in some cases there are findings of cellular and follicular bronchiolitis, which eventually progress to concentric bronchiolitis.[18,20] The follicular bronchiolitis is often present in rheumatologic disorders and is defined by lymphoid hyperplasia and reactive germinal centers along the bronchioles. Patients with airway bronchiolar disorders characteristically develop a syndrome of irreversible airflow obstruction, which is often severe at low lung volumes. Airflow obstruction is determined by the extent of bronchiolar involvement and the degree of narrowing.[21]

Symptoms of constrictive bronchiolitis are nonspecific but include chronic progressive exertional dyspnea and nonproductive cough. The chest radiograph in patients with constrictive bronchiolitis may be normal or may show hyperinflation or a nodular or reticulonodular pattern.[20,21] Regular computed tomography (CT) scan of the thorax has a limited role in the diagnosis, whereas HRCT scans show a variety of direct and indirect findings (**Figure 1**). The direct signs (features of bronchiolitis) are ill-defined centrilobular nodules and branching lines, also called a tree-in-bud pattern. The indirect features (secondary changes in lungs) show widespread or patchy areas of decreased lung attenuation due to reduced perfusion of areas with bronchiolar obstruction and redirected blood flow to normal areas, a phenomenon termed *mosaic perfusion*.[22] Mosaic perfusion can also be seen in pulmonary vascular disease and some forms of interstitial diseases.

Figure 1. High-resolution computed tomography findings consistent with bronchiolitis obliterans (airway bronchiolar disorder) in a 48-year-old nonsmoking woman who presented with several month's history of progressive dyspnea. Hyperinflation, reflected by patchy areas of hyperperfusion interspersed with decreased lung attenuation (termed *mosaic perfusion*), is evident.

However, expiratory HRCT scan is considered to be a more accurate indicator of constrictive bronchiolitis since abnormal lung density persists in both phases of respiration, which is not a feature of the pulmonary vascular diseases and other interstitial diseases.

Underlying Causes and Associated Disorders

The underlying causes of constrictive bronchiolitis can be categorized as infectious and noninfectious. Infections are the most common cause of acute bronchiolitis, a disease seen most commonly in children. The offending organisms include adenovirus (types 3, 7, 21), respiratory syncytial virus, measles, *Mycoplasma*, influenza A, and pertussis.[7,9,23] The pathologic findings demonstrate cellular or follicular bronchiolitis that may progress to constrictive bronchiolitis. Lung biopsy is not required since the diagnosis can be made clinically and the condition most often resolves spontaneously. On imaging studies, hyperinflation with increased bronchial markings is the usual finding; diffuse nodular or reticulonodular patterns may also be evident on chest radiograph and CT scan. Pulmonary function testing may be normal or show obstructive changes, and there may be associated hypoxemia. Treatment is symptomatic, and recovery within days to weeks is the rule.

Noninfectious causes of or conditions associated with constrictive bronchiolitis include organ transplantation, collagen vascular disease, inhalation of toxins and drugs, and an idiopathic form. Constrictive bronchiolitis occurs in 9% of allogenic bone marrow transplant patients but is rarely seen after autologous transplants.[24,25] The cumulative incidence of constrictive bronchiolitis at 5 years posttransplant is 50% to 80%. Five-year survival after onset of constrictive bronchiolitis is only 30% to 50%.[26] Constrictive bronchiolitis is a well-recognized but rare complication of rheumatoid arthritis, polymyositis, and other collagen vascular diseases. Pathologically, small airways disease, cellular and follicular bronchiolitis, and bronchiectasis have also been reported.[27,28] Inhalation injury by toxic fumes and gases (ammonia, sulfur dioxide, phosgene, nitrogen dioxide), mineral dusts, or organic material may lead to mild or severe disease.[29–31]

Idiopathic (primary or cryptogenic) constrictive bronchiolitis is a rare condition mainly affecting women between ages 40 and 60 years.[32,33] Patients present with chronic cough and dyspnea. These patients are nonsmokers and lack other known causes of constrictive bronchiolitis. Bronchial wall thickening and expiratory air trapping is very common on imaging studies. Lung biopsies in these patients show constrictive bronchiolitis, airway obliteration, and mucus stasis. The disorder can be confused with asthma clinically; however, absence of eosinophilic inflammation and/or lack of bronchial hypersensitivity can be useful in differentiating between them. Early treatment with corticosteroids may be beneficial, as most patients progress to irreversible airflow obstruction.[33] The disease often stabilizes and generally has a good prognosis.

INTERSTITIAL BRONCHIOLAR DISORDERS

Respiratory Bronchiolitis-Associated Interstitial Lung Disease

RB-ILD is a clinically overt, smoking-related interstitial lung disease in which the essential histologic features are indistinguishable from smoking-related respiratory bronchiolitis. This disorder can be viewed as an exaggerated respiratory bronchiolitic response to cigarette smoke. There is major overlap of clinical presentation and histopathologic and radiologic manifestations between respiratory bronchiolitis and RB-ILD. Many experts consider the 2 patterns to have features in common and regard them as ends of a spectrum of the same smoking-related disease process rather than as separate entities.[15,34] The pathologic findings of respiratory bronchiolitis and RB-ILD are inflammation of membranous and respiratory bronchioles. The hallmark of these disorders is the presence of tan-brown pigmented macrophages within the respiratory bronchioles and adjoining alveolar ducts.[14] The pulmonary parenchyma away from the airways is usually normal. Respiratory bronchiolitis and RB-ILD present with insidious onset of cough, dyspnea, and fine-end inspiratory crackles on auscultation. Mild to moderate restriction with reduced diffusion or a mixed obstructive-restrictive pattern is demonstrated on pulmonary function tests. Diffuse reticulonodular infiltrates are found on chest radiograph. HRCT shows distinctive features consisting of centrilobular ill-defined nodules, ground-glass opacity, mosaic perfusion, and evidence of lung fibrosis. A disorder with HRCT findings similar to respiratory bronchiolitis/RB-ILD is encountered with mineral dust exposure to asbestos, silica, or other metals. Smoking cessation leads to resolution of respiratory bronchiolitis/RB-ILD.

Proliferative Bronchiolitis/Bronchiolitis Obliterans Organizing Pneumonia

Proliferative bronchiolitis is the underlying histopathologic lesion in interstitial pulmonary disorders and is characterized by an organizing intraluminal exudate. These characteristic intraluminal buds of granulation tissue and fibroblasts, called Masson bodies, are seen in the respiratory bronchioles, alveolar ducts, and alveoli.[7] Organizing pneumonia (eg, inflammatory changes in the surrounding alveolar walls and prominent foamy macrophages in alveolar spaces) is frequently present in patients with proliferative bronchiolitis. BOOP is a histopathologic lesion (not a specific diagnosis) characterized by proliferative bronchiolitis or bronchiolitis obliterans in association with organizing pneumonia. BOOP has features of sequential inflammatory response similar to asthma, COPD, and granulomatous diseases; yet these disorders are different as bronchiolitis is only a small part of the overall pathologic and clinical manifestations of these disorders. Restrictive ventilatory abnormality on lung function tests along with cough, dyspnea, and systemic symptoms are the clinical correlates.[5,7,15,17] Proliferative bronchiolitis causes diffuse infiltrates on chest radiograph. While multiple etiologies may cause the lesions of organizing pneumonia (Table 3), cryptogenic organizing pneumonia (idiopathic BOOP) is the typical syndrome with characteristic clinical, pathologic, and radiographic features.[7–11]

Cryptogenic Organizing Pneumonia

Cryptogenic organizing pneumonia is also referred to as idiopathic BOOP since an etiologic factor is not identified in up to 50% of cases.[7–12,35] The usual age of

onset is between 50 and 60 years; there is no gender predilection.[5,7] Patients develop subacute symptoms of cough and dyspnea, occasionally following flu-like illness. Systemic symptoms such as fever, malaise, and anorexia and weight loss are common. Patients often are initially diagnosed with community-acquired pneumonia and typically do not respond to antibiotics. Physical examination shows absence of clubbing and bilateral inspiratory crackles.

Erythrocyte sedimentation rate and C-reactive protein levels are elevated with peripheral blood leukocytosis and neutrophilia. Pulmonary function tests show a restrictive ventilatory pattern and reduced diffusion. The diffusing capacity is reduced in the majority of patients, and gas exchange abnormalities are extremely common.[5,7] The majority of patients develop arterial hypoxemia at rest and/or during exercise.[6] Bilateral patchy alveolar opacities with peripheral distribution are seen on chest radiograph. Pleural effusions, nodules, and cavities are rare.[6] A less common pattern of linear opacities similar to interstitial pneumonitis is associated with a poorer prognosis. The infiltrates may progress or new infiltrates may appear; unilateral BOOP also has been reported.[11] CT scan of the chest shows findings similar to the chest radiograph, with bilateral patchy areas of consolidation and ground-glass opacities, usually with a peripheral location. The appearance of opacities may vary from ground glass to consolidation on air bronchogram.[11] The CT patterns may be migratory, and this finding is highly characteristic of cryptogenic organizing pneumonia. The peripheral opacities may form the shape of triangles, with the base along the pleural surface and the tip towards the mediastinum.[11] The linear opacities may be along the bronchi toward the pleura and in a subpleural location, predominantly in lower lobes (**Figure 2**).

Bronchoalveolar lavage (BAL) shows absence of pathogens and a mixed cellular pattern with increased counts of lymphocytes (CD8), neutrophils, and eosinophils.[5] The BAL findings are most similar to those reported in hypersensitivity pneumonitis. Other BAL abnormalities found in cryptogenic organizing pneumonia include foamy macrophages, mast cells, plasma cells, and a decreased CD4/CD8 cell ratio. A typical clinicoradiologic pattern with compatible BAL findings has been used to make a presumptive diagnosis to initiate therapy. However, because of the need for long-term corticosteroid treatment and potential for side effects, a definitive diagnosis by surgical lung biopsy is more appropriate.

Surgical lung biopsy is necessary for confirmation of the diagnosis in many cases. Recently, video-assisted thoracoscopic procedure has become the preferred technique. Pathologically, the newly formed plugs of granulation tissue (fibroblasts and connective matrix) are present in the distal bronchioles and extend into the alveolar ducts and alveoli (**Figure 3**). Lung architecture is maintained in BOOP but not in usual interstitial pneumonitis lesions. Interestingly, the pathologic lesions can be completely reversed by corticosteroid therapy. Abundant capillarization in the intraluminal fibromyxoid lesions in BOOP compared with minimal vascularization in interstitial pneumonitis/idiopathic pulmonary fibrosis is believed to be the differentiating factor for corticosteroid response.[17]

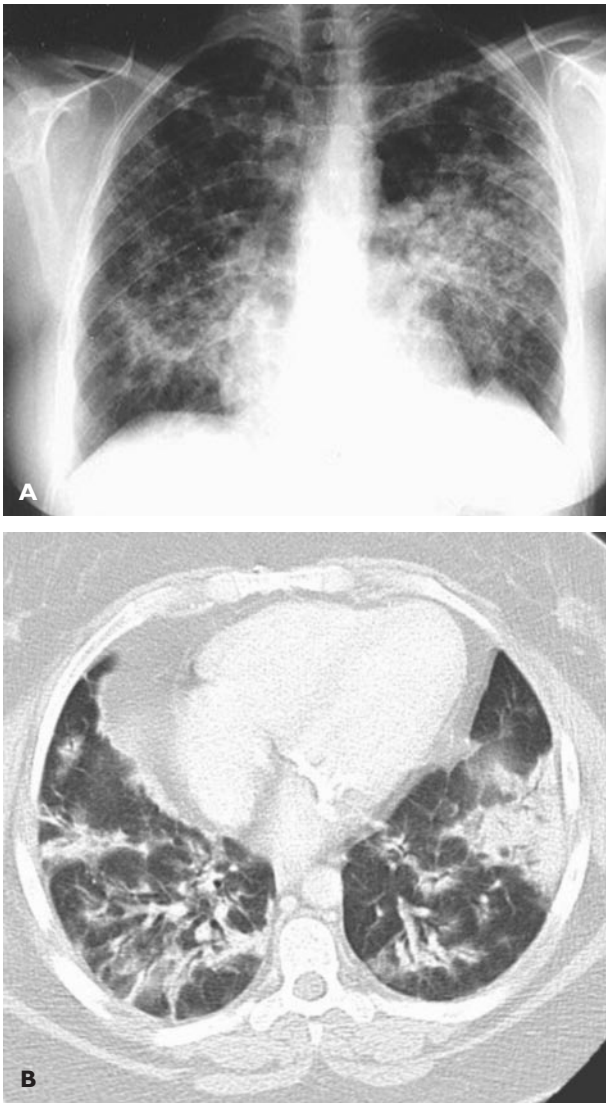

Figure 2. The radiologic hallmarks of bronchiolitis obliterans organizing pneumonia: bilateral patchy alveolar opacities with peripheral distribution and ground-glass attenuation on (**A**) chest radiograph and (**B**) computed tomography scan.

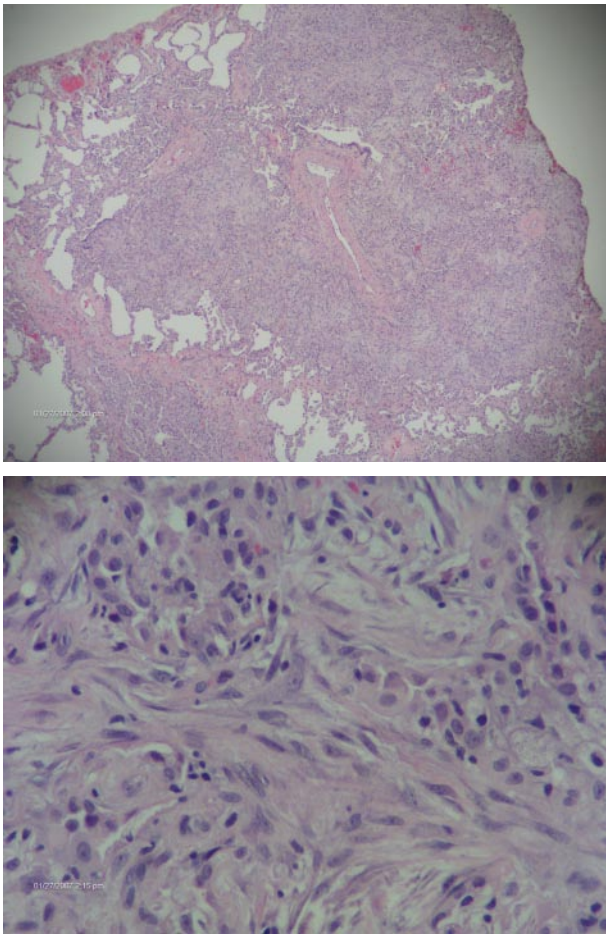

Figure 3. Histopathology slide demonstrating bronchiolitis obliterans organizing pneumonia (BOOP), which is characterized by plugs of granulation tissue in distal bronchioles and minimal interstitial inflammation. In this patient, no etiology was found on clinical evaluation; thus, the clinical disorder was cryptogenic organizing pneumonia, or idiopathic BOOP. (Figures are courtesy of Dr. Julianne Klein.)

TREATMENT

Treatment of bronchiolitis depends upon the underlying cause or the associated disorder. Response to therapy and prognosis in general also depends upon the stage of disease and whether the disorder is airway or interstitial.

Constrictive bronchiolitis is generally progressive with minimal response to therapy, and corticosteroids have little role in treating bronchiolar disorders associated with this lesion. In cases due to toxic inhalation injury, corticosteroids are occasionally effective in the management of both the acute phase illness (pulmonary edema) and the late phase illness (bronchiolitis obliterans). Macrolide antibiotics have been reported to improve symptoms and lung function in airway bronchiolar disorders.[36–38] Macrolides impair neutrophil-derived elastolytic activity in the lung and also decrease the total number of neutrophils in BAL.[37,38] They are also effective in reducing the circulating pool of T lymphocytes and attenuating the immune response. The appropriate drug/dosage has not been adequately studied, and no controlled data exist. Low doses of oral erythromycin (200–600 mg/day), clarithromycin (25–500 mg/day), or azithromycin (250 mg every other day) have been recommended for most patients.[37,38] Etanercept has shown promise in a clinical trial of patients with connective tissue disease–associated bronchiolitis obliterans.[39]

Treatment of cryptogenic organizing pneumonia depends on the underlying cause and treating or removing the causative exposure (Table 2). The mainstay treatment of organizing pneumonia is corticosteroids. Prednisone is recommended as first-line treatment for patients with symptomatic and progressive disease.[8–10] Characteristically, clinical improvement occurs within a few days, followed by resolution of radiographic opacities within a few weeks. Prednisone therapy is initiated at 0.75 to 1 mg/kg and tapered by 0.25 mg/kg every 4 weeks, for a total duration of 6 months to 1 year.[8–10] Since a 6-month course may be sufficient in certain situations, rapid weaning may be attempted. Relapses may occur in 10% to 40% of patients upon dose reduction or cessation of therapy.[9,10] The prognosis of cryptogenic organizing pneumonia is excellent, as resolution occurs in most patients despite relapses. A few patients demonstrate a progressive course leading to severe pulmonary fibrosis. These patients usually have diffuse infiltrative opacities on imaging studies and require treatment with azathioprine and cyclophosphamide.[9,35,40]

If the patient deteriorates despite corticosteroid therapy or cannot tolerate it, therapy with a cytotoxic agent should be started while generally maintaining low-dose (0.25 mg/kg/day) oral corticosteroid therapy, if tolerated.[35,40] Cyclophosphamide is often used in this setting. A dose of 1 to 2 mg/kg/day is initiated and adjusted according to the effect on bone marrow. Some centers begin therapy with 50 mg/day and slowly increase the dose over 2 to 4 weeks to 100 to 150 mg/day. For a maximal clinical response, a trial of at least 3 to 6 months is needed.[40]

CONCLUSION

The term *bronchiolitis* has been historically confusing to clinicians and pathologists alike. Referring to an inflammatory process that involves air-conducting passages measuring less than 2 mm in diameter, this term has been inconsistently used as both a descriptive and a

formal diagnostic term. Bronchiolitis comprises a heterogeneous group of etiologically, clinically, and pathologically disparate lesions. Bronchiolitis may be an isolated pathologic finding, and divergent causes of bronchiolitis may have similar microscopic findings. Hence, a pathologic diagnosis is nonspecific and not clinically meaningful unless placed in the context of relevant clinical and radiographic findings. **HP**

Test your knowledge and comprehension of this article with the *Clinical Review Quiz* on page 30.

Corresponding author: Sat Sharma, MD, St. Boniface General Hospital, BG034, 409 Tache Avenue, Winnipeg, MB, Canada R2H 2A6; ssharma@sbgh.mb.ca.

REFERENCES

1. King TE Jr. Bronchiolitis. In: Schwarz MI, King TE Jr. Interstitial lung disease. 4th ed. Lewiston (NY): B.C. Decker; 2003:787.
2. Lange W. Ueber eine eigenthmliche erkrankung der kleinen bronchien und bronchiolen. Dtsch Arch Klin Med 1901;70:342–64.
3. Fraenkel A. Ueber bronchiolitis fibrosa obliterans, nebst bemerkungen uber lungenhyperaemie und indurierende pneumonie. Dtsch Arch Klin Med 1902;73:484–510.
4. Miller RR, Muller NL, Thurlbeck WM. Diffuse diseases of the lungs. In: Silverberg SG, DeLellis RA, Frable WJ, et al, editors. Silverberg's principles and practice of surgical pathology and cytopathology. 4th ed. New York: Churchill Livingstone; 1997:1099–187.
5. Colby TV, Myers JL. Clinical and histologic spectrum of bronchiolitis obliterans, including bronchiolitis obliterans organizing pneumonia. Semin Respir Med 1992;13:119–33.
6. Green M, Turton CW. Bronchiolitis and its manifestations. Eur J Respir Dis Suppl 1982;121:36–42.
7. Epler GR, Colby TV, McLoud TC, et al. Bronchiolitis obliterans organizing pneumonia. N Engl J Med 1985;312:152–8.
8. King TE Jr. Overview of bronchiolitis. Clin Chest Med 1993;14:607–10.
9. Ryu JH, Myers JL, Swensen SJ. Bronchiolar disorders. Am J Respir Crit Care Med 2003;168:1277–92.
10. Epler GR, Colby TV. The spectrum of bronchiolitis obliterans. Chest 1983; 83:161–2.
11. Lombard C, Yousem SA, Kitaichi M, Colby TV, editors. Atlas of pulmonary surgical pathology. Philadelphia: W.B. Saunders Company; 1991:356–89.
12. Gulliver T, Piedimonte G, Eid N. Small airways disease in asthma. Curr Respir Med Rev 2006;2:279–83.
13. Shaw RJ, Djukanovic R, Tashkin DP, et al. The role of small airways in lung disease. Respir Med 2002;96:67–80.
14. Colby TV. Bronchiolitis. Pathologic considerations. Am J Clin Pathol 1998; 109:101–9.
15. American Thoracic Society; European Respiratory Society. American Thoracic Society/European Respiratory Society International Multidisciplinary Consensus Classification of the Idiopathic Interstitial Pneumonias. This joint statement of the American Thoracic Society (ATS), and the European Respiratory Society (ERS) was adopted by the ATS board of directors, June 2001 and by the ERS Executive Committee, June 2001 [published erratum appears in Am J Respir Crit Care Med 2002;166:426]. Am J Respir Crit Care Med 2002;165:277–304.
16. Penn CC, Liu C. Bronchiolitis following infection in adults and children. Clin Chest Med 1993;14:645–54.
17. Coutre C, Colby TV. Histopathology of bronchiolar disorders. Semin Respir Crit Care Med 2003;24:489–98.
18. Myers JL, Colby TV. Pathologic manifestations of bronchiolitis, constrictive bronchiolitis, cryptogenic organizing pneumonia, and diffuse panbronchiolitis. Clin Chest Med 1993;14:611–22.
19. Garg K, Lynch DA, Newell JD, King TE Jr. Proliferative and constrictive bronchiolitis: classification and radiologic features. AJR Am J Roentgenol 1994;162:803–8.
20. Stern EJ, Frank MS. Small-airway diseases of the lungs: findings at expiratory CT. AJR Am J Roentgenol 1994;163:37–41.
21. Padley SP, Adler BD, Hansell DM, Muller NL. Bronchiolitis obliterans: high resolution CT findings and correlation with pulmonary function tests. Clin Radiol 1993;47:236–40.
22. Eber CD, Stark P, Bertozzi P. Bronchiolitis obliterans on high-resolution CT: a pattern of mosaic oligemia. J Comput Assist Tomogr 1993;17:853–6.
23. Sweatman MC, Millar AB, Strickland B, Turner-Warwick M. Computed tomography in adult obliterative bronchiolitis. Clin Radiol 1990;41:116–9.
24. Paz HL, Crilley P, Topolsky DL, et al. Bronchiolitis obliterans after bone marrow transplantation: the effect of preconditioning. Respiration 1993;60: 109–14.
25. Yousem SA. The histological spectrum of pulmonary graft-versus-host disease in bone marrow transplant recipients. Hum Pathol 1995;26:668–75.
26. Bolme P, Henter JI, Winiarski J, et al. Allogeneic bone marrow transplantation for hemophagocytic lymphohistiocytosis in Sweden. Bone Marrow Transplant 1995;15:331–5.
27. Schwarz MI, Lynch DA, Tuder R. Bronchiolitis obliterans: the lone manifestation of rheumatoid arthritis? Eur Respir J 1994;7:817–20.
28. Hayakawa H, Sato A, Imokawa S, et al. Bronchiolar disease in rheumatoid arthritis. Am J Respir Crit Care Med 1996;154:1531–6.
29. Konichezky S, Schattner A, Ezri T, et al. Thionyl-chloride-induced lung injury and bronchiolitis obliterans. Chest 1993;104:971–3.
30. Zwemer FL Jr, Pratt DS, May JJ. Silo filler's disease in New York State. Am Rev Respir Dis 1992;146:650–3.
31. Boswell RT, McCunney RJ. Bronchiolitis obliterans from exposure to incinerator fly ash. J Occup Environ Med 1995;37:850–5.
32. Epler GR. Miscellaneous causes of bronchiolitis obliterans. In: Epler GR, editor. Diseases of the bronchioles. New York: Raven Press; 1994:291–3.
33. Kraft M, Mortenson RL, Colby TV, et al. Cryptogenic constrictive bronchiolitis. A clinicopathologic study. Am Rev Respir Dis 1993;148:1093–101.
34. Finkelstein RA, Cosio MG. Disease of the small airways in smokers: smokers' bronchiolitis. In: Epler GR, editor. Diseases of the bronchioles. New York: Raven Press; 1994:115–37.
35. King TE Jr, Mortenson RL. Cryptogenic organizing pneumonitis. The North American experience. Chest 1992;102(1 Suppl):8S–13S.
36. Azuma A, Kudoh S. Securing the safety and efficacy of macrolide therapy for chronic small airway diseases [editorial]. Intern Med 2005;44:167–8.
37. Khalid M, Al Saghir A, Saleemi S, et al. Azithromycin in bronchiolitis obliterans complicating bone marrow transplantation: a preliminary study. Eur Respir J 2005;25:490–3.
38. Nagai H, Shishido H, Yoneda R, et al. Long-term low-dose administration of erythromycin to patients with diffuse panbronchiolitis. Respiration 1991;58:145–9.
39. Cortot AB, Cottin V, Miossec P, et al. Improvement of refractory rheumatoid arthritis-associated constrictive bronchiolitis with etanercept. Respir Med 2005;99:511–4.
40. Cohen AJ, King TE Jr, Downey GP. Rapidly progressive bronchiolitis obliterans with organizing pneumonia. Am J Respir Crit Care Med 1994;149: 1670–5.

Copyright 2008 by Turner White Communications Inc., Wayne, PA. All rights reserved.