Series Editor: Bernard M. Karnath, MD

Evaluation of Hematuria

Bernard M. Karnath, MD
Gabriel Rodriguez, MD
Roxana Narat, MD

Blood in the urine is a common problem that can be a sign of a number of benign and malignant underlying diseases. Hematuria may be macroscopic (visible on gross examination) or microscopic.[1,2] The American Urological Association defines microscopic hematuria as 3 or more red blood cells (RBCs) per high-power field (hpf) on microscopic analysis of 2 or 3 properly collected urine specimens,[3] although other definitions range from 1 to more than 10 RBCs/hpf.[2,4,5] The causes of hematuria can be broadly categorized into renal and extrarenal, and renal causes can be subdivided into glomerular and nonglomerular (**Table 1**). A detailed history is essential in elucidating the cause of hematuria, and a family history should not be overlooked. Laboratory evaluation is also important as microscopic examination of the urine can confirm whether blood is actually present in the urine (eg, in the case of a false-positive dipstick test) and may help determine whether the source of blood is glomerular or nonglomerular.[6] Further investigation with imaging studies may be warranted in some disease processes. This article discusses the approach to the patient with hematuria, with an emphasis on history and laboratory evaluation.

CLINICAL FEATURES OF HEMATURIA

- Hematuria can be macroscopic or microscopic.
- The causes of hematuria are broadly categorized into renal and extrarenal, and renal causes of hematuria are further divided into glomerular and nonglomerular.
- Hematuria of glomerular origin is described as cola-colored.
- Hematuria from the lower urinary tract and renal pelvises (extrarenal) is pink or red in color.
- Dysmorphic red blood cells (RBCs) on urine microscopy are indicative of a glomerular source.
- The presence of RBC casts is diagnostic for a glomerular source of bleeding.

HISTORY

The evaluation of hematuria should always begin with a detailed history. The timing of hematuria in the urinary stream is important. Hematuria at the start of urination suggests a problem with the distal urethra, while hematuria at the end of urination suggests a problem with the bladder neck, posterior urethra, or prostatic urethra in men. Hematuria throughout urination suggests an upper urinary tract or upper bladder source. The color of the urine may help determine whether the source of blood is glomerular or nonglomerular in origin. Hematuria of glomerular origin is described as cola-colored, while hematuria from the renal pelvises and lower urinary tract is usually pink or red.

A history of associated pain also may point to a certain disease process (eg, urinary tract infection, especially if there is associated fever and chills). The presence of costovertebral angle tenderness suggests pyelonephritis (**Figure 1**). Hematuria with pain that is acute in onset and associated with nausea and vomiting may suggest nephrolithiasis. The pain of nephrolithiasis is generally described as a severe colicky flank pain that can radiate to the groin.

A detailed family history is important in screening for familial diseases that cause hematuria, such as Alport's syndrome, polycystic kidney disease, sickle cell syndromes, benign familial hematuria, and a bleeding diathesis.[7] In the family history, a finding of deafness

Dr. Karnath is an associate professor of medicine, Division of General Medicine, and Dr. Rodriguez is an associate professor of surgery, Division of Urology; both are at the University of Texas Medical Branch, Galveston, TX. Dr. Narat is a resident, Department of Pediatrics, University of Texas Southwestern Medical Center, Dallas, TX.

Table 1. Causes of Hematuria

Renal
Glomerular
Thin basement membrane disease (benign familial hematuria)
IgA nephropathy
Alport's syndrome
Other glomerulonephritides
Nonglomerular
Polycystic kidney disease
Medullary sponge kidney
Papillary necrosis
Pyelonephritis
Sickle cell disease
Renal cell carcinoma
Renal vascular disease
Extrarenal
Upper urinary tract
Nephrolithiasis
Ureteral cancer
Lower urinary tract
Cystitis
Bladder cancer
Bladder stones
Prostate cancer
Schistosomiasis
Other
Vigorous exercise
Coagulation related
Factitious
False hematuria

suggests Alport's syndrome, a finding of renal failure suggests polycystic kidney disease, and a finding of easy bleeding suggests an inherited coagulopathy or platelet disorder. Sickle cell trait or disease is suggested in young patients with unexplained hematuria who have ethnic origins from Africa, the Middle East, and Mediterranean countries.[8]

LABORATORY EVALUATION

The first question in the laboratory evaluation of the patient with hematuria is whether blood is actually present in the urine. False-positive dipstick readings are common and may be due to detection of myoglobin or contamination of the urine specimen with menstrual blood. All positive urine dipstick tests require confirmation with microscopic examination.

Urinalysis can usually differentiate a renal from a urologic source of bleeding. The presence of RBC casts is diagnostic for a glomerular source of hematuria (**Figure 2**). Phase-contrast microscopy is helpful in elucidating the origin of blood loss when RBC casts are not visualized. Nonglomerular hematuria is characterized by RBCs that have an appearance similar to those seen on a peripheral smear and are uniform in size and shape, while in glomerular hematuria the RBCs have a dysmorphic appearance and are smaller than nonglomerular RBCs.[9]

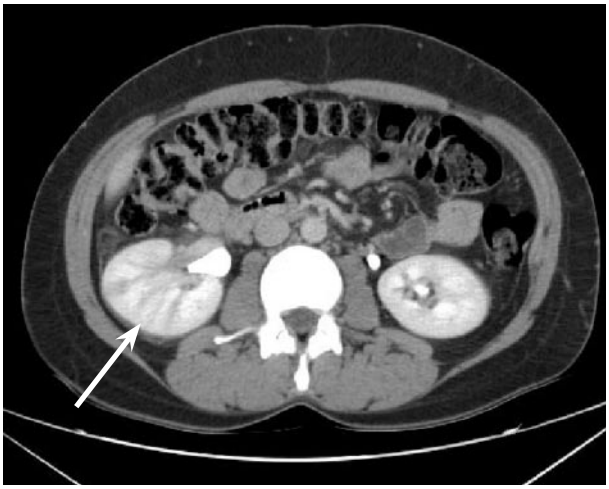

Figure 1. Computed tomography scan showing an edematous right kidney (*arrow*) in a patient with pyelonephritis.

A brief discussion of other urinary casts is warranted. Hyaline casts are formed in concentrated urine from normal components of urine and are considered benign. White blood cell (WBC) casts can be found in pyelonephritis and interstitial nephritis. Pigmented "muddy brown" granular casts and casts containing tubule epithelial cells are characteristic of acute tubular necrosis and suggest ischemic or nephrotoxic injury. Eosinophiluria (ie, eosinophils comprising > 5% of urine WBCs) is associated with drug-induced allergic interstitial nephritis. Eosinophils can be seen with Hansel's or Wright's stain of the urine. Crystals may be found in the urine of healthy individuals and in patients with nephrolithiasis.

IMAGING STUDIES

Imaging studies may be warranted when certain disease processes are suspected such as urolithiasis and malignancy. These studies include the intravenous pyelogram (IVP; **Figure 3**), computed tomography (CT), ultrasonography, and magnetic resonance imaging (MRI).[10] The IVP historically has been the traditional choice for evaluating the urinary tract, but it has low sensitivity for detecting renal and bladder masses and there is a risk

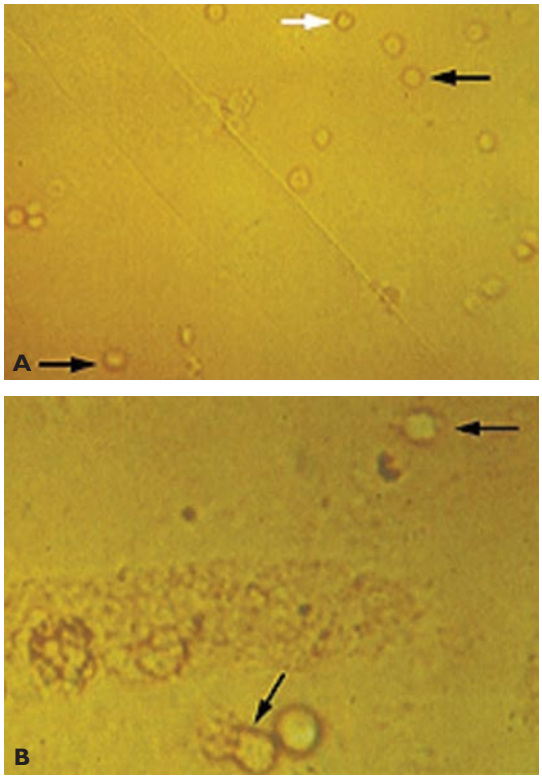

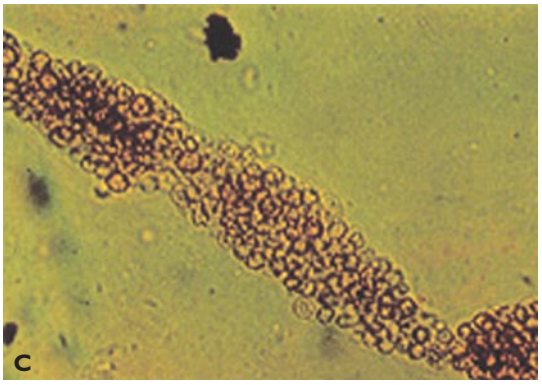

Figure 2. Microscopy of urine sediment demonstrating (**A**) nondysmorphic red blood cells (*black arrows*) and a dysmorphic red blood cell (*white arrow*), (**B**) dysmorphic red blood cells (*arrows*), and (**C**) a red blood cell cast. (Adapted with permission from Agrawal MA, Swartz R. Acute renal failure. Am Fam Physician 2000;61:2084. Copyright © 2000 American Academy of Family Physicians. All rights reserved.)

Figure 3. Intravenous pyelogram showing left hydronephrosis resulting from a stone (*arrow*) at the ureterovesical junction (the stone is difficult to visualize).

for nephrotoxicity with contrast media. Renal masses are best evaluated with ultrasonography, CT, or MRI. Cystoscopy is helpful when investigating bladder lesions.

CAUSES OF HEMATURIA

Malignancy

Common risk factors for urinary malignancy include age and tobacco use. Although screening for asymptomatic hematuria in adults is not recommended,[11] an evaluation is warranted when asymptomatic microscopic hematuria is found.[12] Malignancy-associated hematuria tends to be macroscopic and painless but can be microscopic and painless in early stages of disease. Renal cell carcinoma, however, can present with flank pain or may be incidentally discovered while performing an imaging study for another reason.

Renal masses can be a simple cyst, a complex cyst, or a solid mass (**Figure 4**). Solid masses are more likely to represent malignancies. Broadened use of radiologic imaging has increased the incidental detection of renal cell carcinoma. Incidental tumors may be frequently detected in elderly patients and may carry a better prognosis than tumors that present with symptoms, as symptomatic disease correlates with an aggressive histology and advanced disease.[13] Symptomatic disease classically presents with flank pain, palpable flank mass, and hematuria. Unfortunately, this triad only occurs in approximately 10% of all solid renal masses.[13] Other presenting features of renal cell carcinoma are constitutional symptoms, paraneoplastic syndromes, and skeletal pain related to metastatic disease.[13,14]

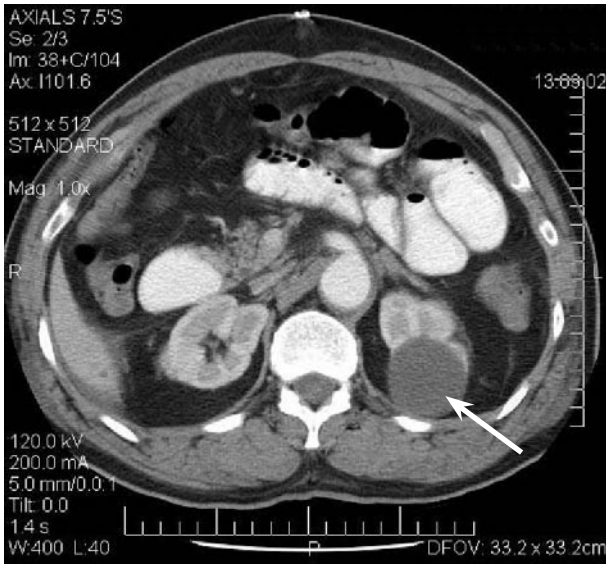

Figure 4. Computed tomography scan of the abdomen showing a nonenhancing benign cystic mass (*arrow*) of the left kidney.

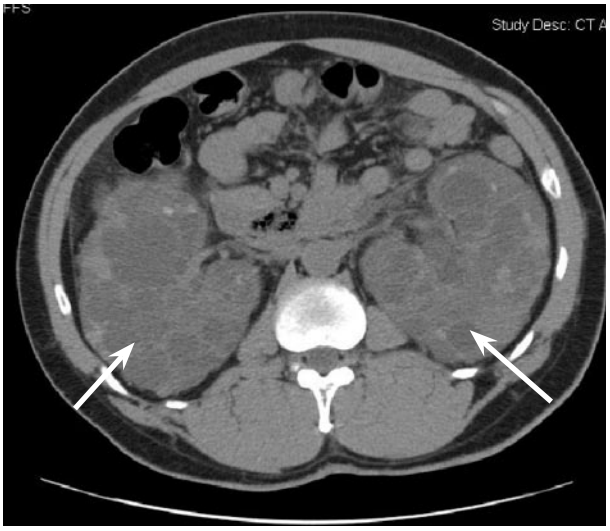

Figure 5. Computed tomography scan showing bilateral polycystic kidneys (*arrows*).

Cystic Kidney Diseases

Autosomal dominant polycystic kidney disease (ADPKD). ADPKD is a genetic disorder in which extensive cysts develop in the kidneys (**Figure 5**) and, to a lesser extent, in other organs, including the liver, pancreas, and ovaries. As the cysts enlarge over several years, the normal renal parenchyma is progressively destroyed, leading to renal failure. ADPKD is the fourth most common cause of end-stage renal disease in the United States, accounting for 5% of all cases.[15,16] Hematuria, flank pain, polyuria, nephrolithiasis, urinary tract infection, and hypertension may be part of the syndrome associated with ADPKD. In patients with ADPKD, most episodes of hematuria are due to urinary tract infections and renal cyst rupture.[17]

The gene involved in most cases of ADPKD (80%–85%) is PKD1, which is located on chromosome 16. In the remaining (10%–15%) cases, the disease is milder and is caused by mutational changes in PKD2, which is located on chromosome 4.[18]

Patients with ADPKD are prone to stone development. A study of 751 patients with ADPKD found that 151 of these patients had developed nephrolithiasis over 10 years of follow up. Stone analysis in 30 patients revealed the following stone compositions in decreasing order of prevalence: uric acid, calcium oxalate, calcium phosphate, and struvite.[19]

Medullary sponge kidney. Medullary sponge kidney is a renal malformation characterized by cystic dilatation of the renal collecting tubules, which is frequently associated with nephrocalcinosis and renal stones. Hematuria is also common. IVP is the gold standard for the diagnosis of medullary sponge kidney, which shows the accumulation of contrast in the dilated collecting ducts (**Figure 6**).[20]

Glomerular Diseases

Alport's syndrome. Alport's syndrome is a familial form of progressive renal disease associated with hematuria, sensorineural deafness, and end-stage renal disease. Diagnosis of the syndrome is typically based on a family history of hematuria, dysmorphic RBCs on urinalysis, audiometry revealing sensorineural hearing loss, and skin biopsy or renal biopsy. The absence of alpha 5 chains of type IV collagen in the epidermal basement membrane on skin biopsy or in the glomerular basement membrane on kidney biopsy is diagnostic.[21] Skin biopsy is less invasive and should be performed first.

Mutations in collagen type IV genes are responsible for the X-linked, autosomal recessive, and autosomal dominant forms of Alport's syndrome.[22] It has been suggested that benign familial hematuria represents the carrier state for autosomal recessive Alport's syndrome, as both manifest with collagen type IV nephropathy. Progressive renal dysfunction and renal failure occur in affected males. Most female carriers of collagen type IV gene mutations have minimal renal disease.

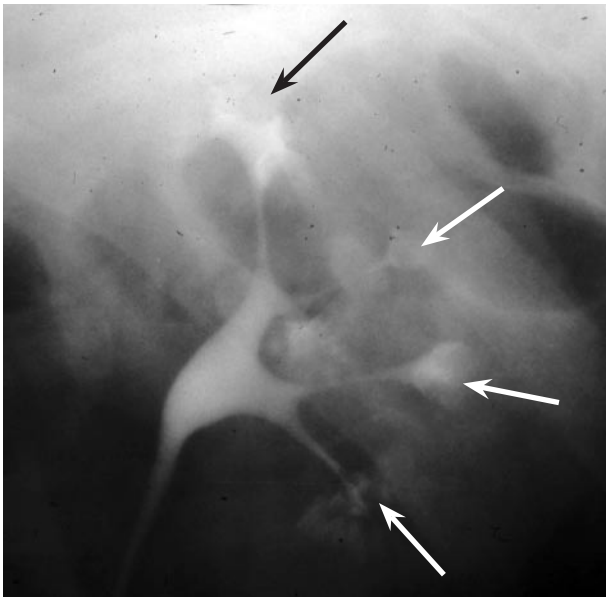

Figure 6. Intravenous pyelogram of the left kidney showing dilated collecting ducts (*arrows*) proximal to the renal calyces, consistent with medullary sponge kidney.

Table 2. Classification of Glomerulonephritides Based on Complement Levels

Low Serum Complement Level	Normal Serum Complement Level
Systemic Diseases	
Systemic lupus erythematosus	Henoch-Schönlein purpura
Cryoglobulinemia	Polyarteritis nodosa
	Wegener's granulomatosis
	Goodpasture's syndrome
Renal Diseases	
Poststreptococcal glomerulonephritis	IgA nephropathy
Membranoproliferative glomerulonephritis	Idiopathic rapidly progressive glomerulonephritis

Adapted with permission from Madaio MP, Harrington JT. The diagnosis of glomerular diseases: acute glomerulonephritis and the nephrotic syndrome. Arch Intern Med 2001;161:26. Copyright © 2001, American Medical Association. All rights reserved.

Thin basement membrane disease. Thin basement membrane disease, also known as benign familial hematuria, is the most common glomerular cause of hematuria.[23] Thin basement membrane nephropathy (TBMN) is a common, lifelong condition affecting the kidneys that is characterized by microscopic glomerular hematuria and normal renal function. In TBMN, the glomerular basement membrane (GBM) is thinned to about half its normal thickness and RBCs escape through gaps in the thin membrane. Patients with TBMN have a family history of hematuria with a benign clinical course. It may be inherited in an autosomal dominant or autosomal recessive manner. A renal biopsy is warranted if IgA disease or X-linked Alport's syndrome cannot be excluded clinically.[23] Renal biopsy in patients with TBMN reveals thinning of the GBM from the normal 300 to 400 nanometers to less than 200 to 250 nanometers.[23]

Glomerulonephritis. The presence of RBC casts is diagnostic for a glomerular source of hematuria. Glomerular bleeding is suggested by the presence of deformed (dysmorphic) RBCs as well as by the combination of hematuria and proteinuria. Additionally, the presence of a rash and hypertension increases the possibility of glomerulonephritis.[24] Causes of acute glomerulonephritis can be broadly classified into those associated with low serum complement levels and those associated with normal complement levels (**Table 2**).[25]

IgA nephropathy is the most common form of glomerulonephritis.[26] It presents with painless intermittent gross hematuria that frequently follows an upper respiratory infection. The cause of IgA nephropathy is unknown, but it is thought to result from hyperactivity of the mucosal immune system. Henoch-Schönlein purpura (HSP) shares a similar pathophysiology with IgA nephropathy in that both diseases have glomerular IgA deposits. In HSP, a purpuric palpable rash is seen predominantly on the lower extremities. Biopsy specimens from the skin of patients with HSP reveals IgA deposits in dermal vessels. HSP may represent a systemic form of IgA nephropathy. Abdominal pain and joint pain are often present in HSP as well.

Another glomerular disease that can follow an infectious process is poststreptococcal glomerulonephritis, which can occur after an episode of pharyngitis or impetigo. It generally presents with hematuria, edema, and hypertension, and patients with poststreptococcal glomerulonephritis typically present with high titers of antistreptolysin O and low levels of C3. Renal biopsy shows deposits of IgG and C3 in the glomeruli. Renal biopsy is not always indicated in such cases unless other causes of low serum complement are sought.[25]

Other Renal Causes

Sickle cell disease. Hematuria is seen in individuals with sickle cell disease and in those with sickle cell trait. Sickle cell disease causes renal dysfunction and hematuria due to sickling of RBCs in the renal medulla, which leads to papillary necrosis. However, hematuria in patients with sickle cell disease should not be attributed

solely to papillary necrosis as sickle cell syndromes are associated with renal medullary carcinoma, an aggressive tumor that has a poor outcome if diagnosis is delayed.[27]

Renal vein thrombosis. Acute renal vein thrombosis presents as sudden flank pain and macroscopic hematuria. Oral contraceptive use may be associated with increased risk of acute renal vein thrombosis.[28] Patients with nutcracker syndrome, or renal vein entrapment syndrome, are also at risk for renal vein thrombosis.[29] In this syndrome, the left renal vein is trapped between the aorta and superior mesenteric artery, and left renal vein hypertension ensues. Renal vein thrombosis has a more insidious onset in patients with nephrotic syndrome and renal cell carcinoma, both of which are risk factors for renal vein thrombosis. Doppler ultrasonography is the initial study of choice for evaluating suspected renal vein thrombosis. MRI is also useful.

Extrarenal Causes

Nephrolithiasis. Small kidney stones can pass without symptoms, but passage usually produces bleeding and pain secondary to acute ureteral obstruction. In 1 study, stones less than 5 mm were less likely to be associated with hematuria.[30] Hematuria associated with flank pain may suggest a diagnosis of nephrolithiasis, especially if the pain is colicky in nature.[31] Patients with nephrolithiasis are often writhing in pain and in distress and have difficulty finding a comfortable position. The pain may remain in the flank or spread downward toward the ipsilateral groin, testis, or vulva. This referred pain is explained by the common innervations of the ureter and inguinal region, scrotum, and vulva from T_{11} and T_{12}.

Plain radiographs of the abdomen may detect the stone, but not all stones are radiopaque (eg, uric acid stones). Most stones (80%) are composed of calcium in combination with either oxalate or phosphate.[32] Struvite stones, composed of magnesium ammonium phosphate, are associated with urinary tract infections (**Figure 7**). Plain radiographs have a sensitivity of 45% and a specificity of 77% for the detection of nephrolithiasis; the sensitivity of the plain radiograph increases with larger stones (> 5 mm).[33]

Traditionally, IVP has been used for evaluation of acute renal colic; however, helical CT scanning without intravenous radiocontrast has replaced the IVP given its many advantages, including the ability to detect smaller radiolucent stones (eg, uric acid stones) in addition to the more common radiopaque stones. Other advantages are the ability to detect stones without exposing the patient to radiocontrast dye and the ability to potentially diagnose other causes of abdominal pain in a patient suspected of having renal stones. Ultrasound is not as sensitive as CT scan for detecting renal or ureteral stones but may prove useful in evaluating patients with renal insufficiency.

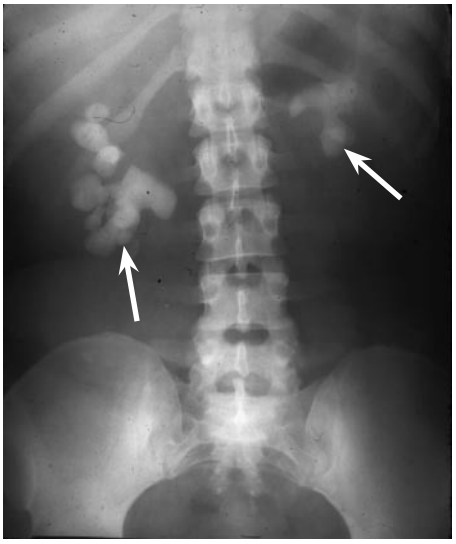

Figure 7. Plain abdominal radiograph showing radiopaque stones of both kidneys (*arrows*) consistent with a staghorn calculi.

Bladder disease. Bladder conditions that can cause hematuria include infections, inflammation, stones, and malignancy. Dysuria with frequency and hematuria suggests an infectious cause. Patients with acute cystitis usually report dysuria, frequency, urgency, and suprapubic pain. The urine often becomes grossly cloudy and malodorous and may be bloody. WBCs and bacteria can be detected by examination of the urine.

Interstitial cystitis is a separate disease entity with an unknown etiology. The incidence of hematuria in patients with interstitial cystitis may be higher than previously reported. Hematuria may be found in up to 30% of patients with interstitial cystitis.[34] Although many of these patients present with pelvic pain and irritative voiding symptoms, the hematuria evaluation is unlikely to reveal a life-threatening urologic condition.[34]

Cigarette smoking is a known risk factor for transitional cell carcinoma of the bladder and should heighten the suspicion for a potential malignancy.[35] Urine cytology is a cost-effective test in the evaluation of urologic malignancies, although the traditional test of choice has been the IVP (**Figure 8**). Urine cytology can be helpful in patients with significant risk factors for malignancy,[36] but unfortunately negative urine cytology does not exclude the presence of a malignancy, since only higher grade tumors will shed enough cells to be identified. Thus, cytologic examination alone

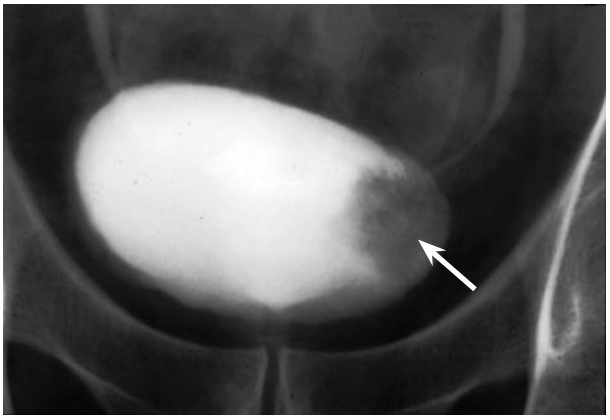

Figure 8. Intravenous pyelogram showing a filling defect in the left bladder wall (*arrow*) consistent with a malignancy.

cannot make the diagnosis of malignancy. Cystoscopy is needed for full evaluation of the bladder mucosa.

Schistosomiasis. Travel history is paramount in the diagnosis of schistosomiasis. *Schistosoma haematobium* is endemic in Africa and the Middle East. Patients present with episodic gross hematuria caused by bladder lesions that result from the deposition of eggs in the submucosa. Cystoscopy with bladder mucosa biopsy is diagnostic.[37]

Exercise-induced hematuria. Exercise-induced hematuria is a diagnosis of exclusion. It is considered a benign condition that occurs after strenuous activity in which bleeding is thought to originate from the bladder mucosa. The hematuria typically resolves after a few days. If it does not, a full work-up is indicated.

False hematuria. False hematuria includes bleeding from sources outside the urinary tract such as the vagina and external genitalia. Thus, a menstrual history is important in female patients being evaluated for microscopic hematuria. Not all reddish-brown urine is the result of hematuria. False hematuria also results from pigmenturia, myoglobinuria, and hemoglobinuria. Pigmenturia commonly occurs with certain medications such as phenazopyridine, methyldopa, and rifampin. Factitious hematuria can be excluded by carefully collecting and testing a catheterized urine sample. Long-term indwelling catheters pose a problem. A prospective study of episodes of gross hematuria identified by nursing staff at long-term-care facilities of elderly institutionalized patients found that 28% of episodes occurred in patients with indwelling catheters.[38]

Coagulation-related hematuria. Therapeutic anticoagulation or antiplatelet therapy generally does not cause hematuria, and an underlying disease must be excluded in such cases. Timely and thorough evaluation of hematuria in patients taking anticoagulants is necessary to identify and treat clinically important pathology. Early identification of malignancy allows for aggressive surgical intervention.[39] The presence of excessive anticoagulation should not impede a full evaluation. In a retrospective study of patients admitted for gross hematuria while receiving anticoagulation, 11 of 24 patients on warfarin were receiving excessive anticoagulation medication. Two patients in the excessive coagulation group were found to have transition cell carcinoma of the bladder.[40] In a prospective study of 32 consecutive patients with new onset of gross or microscopic hematuria while on anticoagulant therapy, significant urinary tract disease was present in 9 patients (30%).[41] Of 6 patients with microscopic hematuria, 3 had nephrolithiasis. In the 24 patients with gross hematuria, neoplastic disease invading the bladder (2 patients), benign prostatic hyperplasia requiring resection (1 patient), urethral stricture (1 patient), ureteropelvic junction obstruction (1 patient), and nephrolithiasis (1 patient) were found. Based upon these observations, it can be concluded that gross or microscopic hematuria during anticoagulant therapy is frequently precipitated by a significant pathologic condition and prompt evaluation should be undertaken.[41]

CONCLUSION

Hematuria may have a benign or malignant cause. A detailed history is essential in helping formulate a diagnostic plan, while examination of the urine is also required to elucidate the origin. Judicious use of imaging studies is warranted in some cases. In order to fully evaluate patients with microscopic or gross hematuria, a combined effort is needed among urologist and internal medicine physicians. Nephrology consultation is essential when renal failure is present. **HP**

Test your knowledge and comprehension of this article with the *Clinical Review Quiz* on page 51.

REFERENCES

1. Bergstein J, Leiser J, Andreoli S. The clinical significance of asymptomatic gross and microscopic hematuria in children. Arch Pediatr Adolesc Med 2005;159:353–5.
2. Cohen RA, Brown RS. Clinical practice. Microscopic hematuria. N Engl J Med 2003;348:2330–8.
3. Grossfeld GD, Wolf JS, Litwin MS, et al. Evaluation of asymptomatic microscopic hematuria in adults: the American Urological Association best practice policy recommendations. Part I: definition, detection, prevalence, and etiology. Urology 2001;57:599–603.

(continued on page 62)

(from page 26)

4. Mazhari R, Kimmel PL. Hematuria: an algorithmic approach to finding the cause. Cleve Clin J Med 2002;69:870, 872–4, 876.
5. Sokolosky MC. Hematuria. Emerg Med Clin North Am 2001;19:621–32.
6. Jaffe JS, Ginsberg PC, Gill R, Harkaway RC. A new diagnostic algorithm for the evaluation of microscopic hematuria. Urology 2001;57:889–94.
7. Kashtan CE. Familial hematurias: what we know and what we don't [editorial]. Pediatr Nephrol 2005;20:1027–35.
8. Voulgarelis M, Ziakas PD. Images in clinical medicine. Renal papillary necrosis unmasking sickle cell disease. N Engl J Med 2005;352:1237.
9. Kincaid-Smith P, Fairley K. The investigation of hematuria. Semin Nephrol 2005;25:127–35.
10. Yun EJ, Meng MV, Carroll PR. Evaluation of the patient with hematuria. Med Clin North Am 2004;88:329–43.
11. Froom P, Froom J, Ribak J. Asymptomatic microscopic hematuria—is investigation necessary? J Clin Epidemiol 1997;50:1197–200.
12. Grossfeld GD, Wolf JS Jr, Litwin MS, et al. Asymptomatic microscopic hematuria in adults: summary of the AUA best practice policy recommendations. Am Fam Physician 2001;63:1145–54.
13. Lee CT, Katz J, Fearn PA, Russo P. Mode of presentation of renal cell carcinoma provides prognostic information. Urol Oncol 2002;7:135–40.
14. Curti BD. Renal cell carcinoma. JAMA 2004;292:97–100.
15. Wilson PD. Polycystic kidney disease. N Engl J Med 2004; 350:151–64.
16. Tahvanainen E, Tahvanainen P, Kaariainen H, Hockerstedt K. Polycystic liver and kidney diseases. Ann Med 2005; 37:546–55.
17. Dedi R, Bhandari S, Turney JH, et al. Lesson of the week: causes of haematuria in adult polycystic kidney disease. BMJ 2001;323:386–7.
18. Al-Bhalal L, Akhtar M. Molecular basis of autosomal dominant polycystic kidney disease. Adv Anat Pathol 2005;12:126–33.
19. Torres VE, Erickson SB, Smith LH, et al. The association of nephrolithiasis and autosomal dominant polycystic kidney disease. Am J Kidney Dis 1988;11:318–25.
20. Gambaro G, Feltrin GP, Lupo A, et al. Medullary sponge kidney (Lenarduzzi-Cacchi-Ricci disease): a Padua Medical School discovery in the 1930s. Kidney Int 2006;69:663–70.
21. Komatsuda A, Ohtani H, Wakui H, et al. A family with X-linked Alport syndrome confirmed by skin biopsy. Nephrol Dial Transplant 2002;17:1145–7.
22. Tazon Vega B, Badenas C, Ars E, et al. Autosomal recessive Alport's syndrome and benign familial hematuria are collagen type IV diseases. Am J Kidney Dis 2003;42:952–9.
23. Savige J, Rana K, Tonna S, et al. Thin basement membrane nephropathy. Kidney Int 2003;64:1169–78.
24. Mookerje BK, Lohr JW, Jenis EH, Heffner HM. Glomerulonephritis for the generalist. J Med 2001;32:115–34.
25. Madaio MP, Harrington JT. The diagnosis of glomerular diseases: acute glomerulonephritis and the nephrotic syndrome. Arch Intern Med 2001;161:25–34.
26. Donadio JV, Grande JP. IgA nephropathy. N Engl J Med 2002;347:738–48.
27. Ataga KI, Orringer EP. Renal abnormalities in sickle cell disease. Am J Hematol 2000;63:205–11.
28. Chan HH, Douketis JD, Nowaczyk MJ. Acute renal vein thrombosis, oral contraceptive use, and hyperhomocysteinemia. Mayo Clin Proc 2001;76:212–4.
29. Mercieri A, Mercieri M, Armanini M, Raiteri M. Exertional haematuria. Lancet 2002;359:1402.
30. Safriel Y, Malhotra A, Sclafani SJ. Hematuria as an indicator for the presence or absence of urinary calculi. Am J Emerg Med 2003;21:492–3.
31. Teichman JM. Clinical practice. Acute renal colic from ureteral calculus. N Engl J Med 2004;350:684–93.
32. Gault MH, Chafe L. Relationship of frequency, age, sex, stone weight and composition in 15,624 stones: comparison of results for 1980 to 1983 and 1995 to 1998. J Urol 2000;164:302–7.
33. Levine JA, Neitlich J, Verga M, et al. Ureteral calculi in patients with flank pain: correlation of plain radiography with unenhanced helical CT. Radiology 1997;204:27–31.
34. Gomes CM, Sanchez-Ortiz RF, Harris C, et al. Significance of hematuria in patients with interstitial cystitis: review of radiographic and endoscopic findings. Urology 2001; 57:262–5.
35. Pashos CL, Botteman MF, Laskin BL, Redaelli A. Bladder cancer: epidemiology, diagnosis, and management. Cancer Pract 2002;10:311–22.
36. Hofland CA, Mariani AJ. Is cytology required for a hematuria evaluation? J Urol 2004;171:324–6.
37. Lischer GH, Sweat SD. 16-year-old boy with gross hematuria. Mayo Clin Proc 2002;77:475–8.
38. Nicolle LE, Orr P, Duckworth H, et al. Gross hematuria in residents of long-term-care facilities. Am J Med 1993; 94:611–8.
39. Ripley TL, Havrda DE, Blevins S, Culkin D. Early evaluation of hematuria in a patient receiving anticoagulant therapy and detection of malignancy. Pharmacotherapy 2004;24:1638–40.
40. Avidor Y, Nadu A, Matzkin H. Clinical significance of gross hematuria and its evaluation in patients receiving anticoagulant and aspirin treatment. Urology 2000;55:22–4.
41. Van Savage JG, Fried FA. Anticoagulant associated hematuria: a prospective study. J Urol 1995;153:1594–6.

Copyright 2007 by Turner White Communications Inc., Wayne, PA. All rights reserved.