

Metastatic Cancers of Unknown Primary Site

Jonathan A. Schneider

Douglas G. Adler, MD

In most cancer patients, the organ in which the cancer initially developed is readily identifiable. In a minority of patients with metastatic cancer, however, the primary organ cannot be identified despite an extensive clinical work-up. This is termed metastatic cancer of an unknown primary site (CUP) and represents a heterogeneous group of metastatic cancers (2%–5% of all cancers),^{1,2} making CUP one of the 10 most frequently diagnosed cancers^{1,2} and the fourth most common cause of cancer deaths in both sexes. Among solid tumors in the United States, CUP represents 40,000 of the 950,000 new cases per year.³ Median age at presentation is 60 years, with a slightly higher prevalence in males.⁴

In the 1970s, the diagnosis of CUP could only be made if the primary tumor was not found at autopsy,⁵ which likely reflects the immature status of computed tomography (CT) and magnetic resonance imaging (MRI) available at the time. Today, however, CUP is defined by patients presenting with a histologically confirmed metastatic cancer in whom a thorough evaluation fails to identify a primary tumor. Evaluation of these patients is difficult and is often protracted. Early reports of chemotherapy in these patients reported survivals of 3 to 4 months, but over the last decade, treatment, response rates, and survival rates have improved. This review discusses the natural history, diagnosis, and treatment of metastatic CUP.

NATURAL HISTORY

In patients with CUP, the primary tumor rarely manifests itself clinically, theoretically due to either regression of the primary tumor or a slow growth rate.^{6,7} It has also been proposed that neo-angiogenesis is dysfunctional, causing the primary tumor to undergo apoptosis.⁸ This results in a biologically advanced tumor that acquires a metastatic phenotype. Most tumors are aggressive as well as resistant to systemic therapies. This unusually aggressive behavior may indicate that CUP functions via a unique biochemical progression. Studies of CUP have shown a deletion of all or part of chromosome 1p as well as an overexpression of the tumor suppressor gene, p53 (in 53% of the tumors studied), and

the oncogene, Bcl-2 (in 40% of the tumors studied).^{9,10} One hypothesis postulates that chromosome 1p carries a metastasis suppressor gene.¹¹ The identification of chromosomal abnormalities associated with cancer is becoming increasingly important, especially in predicting prognosis. For example, when both p53 and Bcl-2 are overexpressed in CUP, there is a trend toward a higher response to cisplatin-based chemotherapy.¹⁰

The natural history of a patient with CUP is different than that of a patient with cancer of a known primary site. CUP is characterized by early dissemination, clinical absence of a primary tumor, unpredictability with regards to pattern of spread, and an overall aggressive nature. More than 50% of patients diagnosed with CUP have multiple sites of involvement.¹² Typically, patients have signs and symptoms related to the site of the metastatic cancer as well as constitutional symptoms, such as anorexia, weight loss, and fatigue. The unpredictable metastatic pattern can be illustrated by the following examples¹³:

- Primary lung cancer is associated with metastases to the bone nearly 50% of the time, whereas lung cancer presenting as CUP involves the bone only 4% of the time;
- Pancreatic cancer presenting as CUP is 4 times more likely to involve the bones, whereas known pancreatic cancer is rarely metastatic to the bone;
- Prostate cancer is 3 times less likely to involve the bones if it presents as a CUP (and more likely to invade the liver and the lungs), whereas in patients with a known prostatic primary cancer, bony metastases are seen up to 70% of the time; and
- The primary tumors of lymph node metastases in the left supraclavicular region (Virchow's node) that are found at autopsy are above the diaphragm as often as they are below, whereas

Mr. Schneider is a fourth year medical student, University of Texas–Houston Medical School, Houston, TX. Dr. Adler is director of gastrointestinal endoscopy and assistant professor of medicine, University of Texas–Houston Health Science Center, Houston, TX.

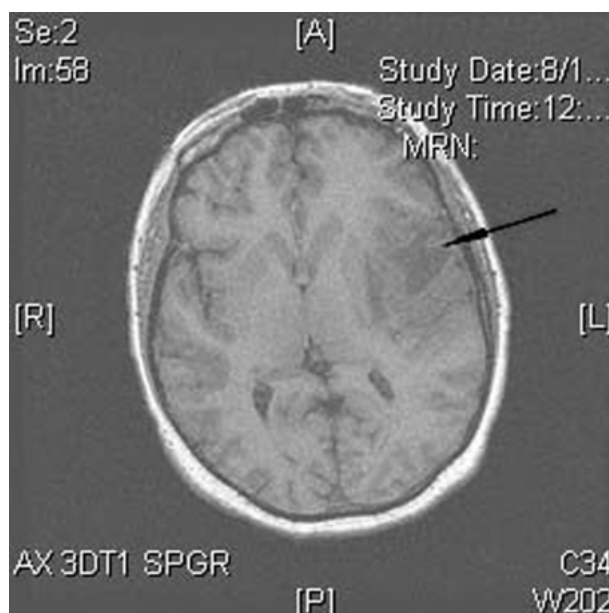


Figure. Head magnetic resonance image (MRI) of a patient who presented with dysarthria and hemiparesis. MRI revealed a left frontotemporal mass (arrow). Biopsy revealed adenocarcinoma from unknown primary. Further evaluation revealed the primary lesion to be an asymptomatic pancreatic adenocarcinoma.

the presence of Virchow's node classically indicates a gastrointestinal malignancy.

The most common sites of metastasis include lymph nodes, liver, lung, and bone.¹²

The most commonly detected primaries of CUP are not the same as the most commonly occurring cancers overall. For example, prostate cancer rarely occurs as CUP, but pancreatic malignancies, which are not one of the most commonly occurring cancers, are among the most commonly detected primaries in CUP (Figure).³ In a study published in 1977, fewer than 20% of patients with CUP had a primary site identified antemortem.¹³ Advanced imaging and the advent of specialized stains may have increased this percentage. The most common primary sites identified are lung (30%) and pancreas (20%), followed by other gastrointestinal and gynecologic cancers. The primary lesions, when identified, usually are small and asymptomatic.¹³

CUP is further biologically differentiated by its progression of malignancy. CUP is thought to undergo type 2 progression (ie, progression without a premalignant stage as opposed to progression from a premalignant state [type 1 progression]). The main difference between CUP and other malignancies undergoing type 2 progression is the aforementioned unpredictability of metastatic spread.¹⁴

Life expectancy for patients with CUP remains poor, with a median survival between 6 and 9 months.¹⁵ However, favorable subsets have been established with specific treatments and improved survival. The following factors have been associated with a favorable prognosis: young age (< 35 years), dominant tumor location in retroperitoneum/peripheral nodes, negative smoking history, good performance status, no liver metastases, and normal lactic dehydrogenase and carcinoembryonic antigen (CEA) levels.^{9,16}

CATEGORIZATION OF CUP SUBTYPES

CUP is commonly categorized into 4 distinct subtypes by light microscopy: (1) well to moderately differentiated adenocarcinomas, (2) undifferentiated or poorly differentiated adenocarcinomas, (3) squamous cell carcinomas, and (4) undifferentiated neoplasms. Approximately 50% of all CUP patients fall into the well to moderately differentiated adenocarcinomas, 30% into the undifferentiated/poorly differentiated adenocarcinomas category, 15% into the squamous cell carcinoma group, and only 5% are classified as undifferentiated neoplasms. Undifferentiated neoplasms are commonly further divided into neuroendocrine tumors, germ cell tumors, and embryonal cancers as well as lymphomas, sarcomas, and melanomas, although the latter 3 are not universally considered part of CUP.¹⁷

DIAGNOSTIC EVALUATION

As CUP is a diagnosis of exclusion, all patients presenting with a metastatic cancer with a primary site undetermined should undergo a detailed medical history, complete physical examination (including pelvic and rectal examinations), full blood count and blood chemistry, urinalysis, stool occult blood testing, pathological review of biopsy specimens, chest radiographs, CT of the abdomen and pelvis, and mammography or testicular examination.^{14,18} Table 1 lists the clinical and laboratory data required before a patient can be defined as having CUP.

Because the overall prognosis remains poor for patients with CUP, the goal of the evaluation is to rapidly diagnose these patients and to implement organ-specific treatment rather than delaying their treatment with further time-consuming, costly evaluations. Diagnostic evaluation should include laboratory and clinical investigations including pathologic, imaging, and endoscopic studies.

Pathologic Studies

The most important step in the work-up of CUP is

Table 1. Evaluation Prior to Diagnosing Patients with Cancer of an Unknown Primary Site

Standard evaluation
Confirm cancer is metastatic
Complete medical history
Complete physical examination (including pelvic, rectal, and testicular examinations as appropriate)
Fecal occult blood testing
Complete blood count
Biochemistry including liver function tests
Radiologic studies: chest radiograph; computed tomography of chest, abdomen, and pelvis
Mammography in women with axillary metastases
Additional procedures if indicated
Gastrointestinal endoscopy/endoscopic ultrasonography with or without biopsy or fine-needle aspiration
Bronchoscopy

obtaining an adequate sample of the metastatic tumor. Fine-needle aspiration by various methods (CT, ultrasound, or endoscopic ultrasound-guided) is commonly used and usually provides enough tissue for pathological examination and special staining. Open biopsies are preferred only when they are excisional biopsies or part of exploratory laparoscopy for carcinomatosis. Light microscopy, which is useful for characterizing cell morphology and tumor differentiation, is rarely successful in identifying the primary tumor. Routine staining with hematoxylin and eosin should be used as well as special stains such as Alcian blue, mucicarmine, and periodic acid-Schiff, which can help to rule out sarcomas and lymphomas in poorly/undifferentiated neoplasms.¹⁹

Immunoperoxidase staining can result in defining tumor lineage and sometimes identification of the tumor origin, especially if the metastases are poorly differentiated. Monoclonal or polyclonal antibodies directed at specific cell components or products are used to locate tissue antigens with either a peroxidase-labeled antibody or an unlabeled antiperoxidase-peroxidase staining method. In both methods, peroxidase is localized through an antigen-antibody reaction, and the sites of localization can be visualized. Most staining can be performed on formalin-fixed, paraffin-embedded tissue. None of the immunoperoxidase staining methods have great specificity, except for the stain for prostate-specific antigen (PSA), which is very specific for prostate cancer.²⁰ Also, the antibodies for leukocyte common antigen are specific for lymphoma, so that patients whose tumors stain for this antigen should undergo further evaluation for lym-

Table 2. Tumor Types and Associated Immunoperoxidase Markers

Tumor Type	Marker
Carcinoma	Cytokeratin, EMA, CLA
Lymphoma	CLA, EMA
Sarcoma	Desmin, vimentin, factor VIII antigen
Neuroendocrine tumor	NSE, chromogranin, synaptophysin, cytokeratin, EMA
Germ cell cancer	Cytokeratin, EMA, HCG, AFP
Prostate cancer	PSA, cytokeratin, EMA
Breast cancer	Cytokeratin, EMA, ER, PR
Melanoma	S-100, HMB-45, vimentin, NSE
Thyroid cancer	
Follicular cancer	Thyroglobulin
Medullary cancer	Calcitonin

AFP = α -fetoprotein; CLA = common leukocyte antigen; EMA = epithelial membrane antigen; ER = estrogen receptor; HCG = human chorionic gonadotropin; HMB = human melanoma, black; NSE = neuron-specific enolase; PR = progesterone receptor; PSA = prostate-specific antigen.

Adapted from Pavlidis N, Briasoulis E, Hainsworth J, Greco FA. Diagnostic and therapeutic management of cancer of an unknown primary. *Eur J Cancer* 2003;39:1990–2005. Copyright © 2003, with permission from Elsevier.

phoma.^{21,22} Monoclonal antibodies have been developed against cytokeratin (CK) polypeptides, with CK7 and CK20 being the most studied. CK7 is useful for diagnosing respiratory and gynecologic cancers, while CK20 can help in the diagnosis of gastrointestinal tumors.²³ **Table 2** lists some of the more commonly used immunoperoxidase staining patterns.

Electron microscopy can be extremely helpful in patients with CUP with regards to identifying a primary tumor type; however, it is not widely available and not usually needed, so it is rarely performed. The technique is expensive, requires special tissue fixation, and can only be recommended for the evaluation of certain poorly differentiated neoplasms. Because electron microscopy allows for the identification of features not visible by other methods, it is useful in distinguishing lymphoma from carcinoma, adenocarcinoma (intercellular/intracellular lumina and surface microvilli) from squamous cell carcinoma (desmosomes, prekeratin filaments), and in identifying neuroendocrine tumors (neurosecretory granules), melanomas (premelanosomes) or poorly differentiated sarcomas. Electron microscopy should be reserved for the evaluation of poorly differentiated neoplasms, particularly when the lineage of the tumor is unclear after light microscopy and immunoperoxidase staining. It is usually not possible to determine

the origin of poorly differentiated adenocarcinoma or squamous carcinoma by electron microscopic features.⁹

Endoscopic Studies

Endoscopies should be used in the CUP patient with specific complaints. Ear, nose, and throat endoscopy should be implemented in patients with cervical node involvement. Fiberoptic bronchoscopy is encouraged in patients with pulmonary complaints, whereas gastrointestinal endoscopies should be used for patients with gastrointestinal complaints or blood in the stool. Finally, proctoscopy/colposcopy should be implemented in patients with inguinal lymph node involvement.²⁴

Serum Markers

The routine use of serum tumor markers is not recommended because, in general, the sensitivity and specificity of tumor markers (CEA, cancer antigen [CA] 15-3, CA 19-9, etc) remain low for the detection of CUP. Nonspecific elevations of multiple markers occur in most patients with CUP. One study showed that 40% of CUP patients had simultaneous elevations of 6 common tumor markers (CEA, CA 19-9, CA 15-3, CA-125, β -chorionic gonadotropin [β -HCG], and α -fetoprotein [AFP]).²⁵ However, there are 3 serum tumor markers that have been found to be reliable in the diagnosis and monitoring of CUP: (1) PSA in men with predominant skeletal metastases to screen for prostate cancer, (2) β -HCG in young men with poorly differentiated carcinoma to evaluate for testicular cancer, and (3) AFP in young men with poorly differentiated carcinoma, which also can evaluate testicular cancer. Elevated CA-125 in women with malignant ascites is suggestive of but nonspecific for ovarian cancer.^{26,27} High levels of serum thyroglobulin in CUP patients with bone metastases suggests an occult thyroid cancer.²⁸

Imaging

Radiologic work-up is of key importance in the work-up of CUP. Chest radiography is almost always performed, but one study showed that a chest radiograph was only able to differentiate between a primary and secondary malignancy in the lungs in one third of cases.²⁹ However, it should always be used in the initial evaluation of the patient due to its availability and low cost. CT scanning of the chest, abdomen, and pelvis can detect the primary site in one third of CUP patients. It is also a good means to evaluate the mediastinum and to assist in any biopsies that may be needed.³⁰

Endoscopic ultrasonography is becoming more popular and has been shown to possess equal or better

sensitivity and specificity as CT in detecting pancreatic cancer, especially when combined with fine-needle aspiration.^{31–33} Endoscopic ultrasonography should be reserved for cases in which the index of suspicion for pancreatic, extraluminal, or submucosal gastrointestinal cancer is high. Mammography should be used for women with adenocarcinoma involving the axillary lymph nodes. If breast cancer is suspected despite a negative mammogram and ultrasound, MRI is considered sensitive for this situation.³⁴

2-[18F]-Fluorodeoxyglucose positron emission tomography (FDG-PET) is now gaining acceptance as an important early investigative tool in the work-up of CUP patients because of its high sensitivity in many malignant diseases and its potential for exploring the whole body in a single and noninvasive examination.³⁵ It is especially useful for detecting primaries in patients with metastases in their cervical nodes and is considered a better diagnostic tool than conventional modalities (CT and/or MRI and panendoscopy) in this setting. It has been shown to modify the treatment in some patients whose tumor was first localized with the use of CT.³⁶ In a study with 50 patients, FDG-PET had a higher sensitivity (100%) and specificity (94%) than the combination of conventional imaging and panendoscopy.³⁷

TREATMENT

The treatment strategy for CUP should be individualized according to the clinical subset. It should be determined whether the patient belongs to any of the favorable subsets before beginning treatment. Over the past several years, 8 subsets have been created, each with specific therapy that has produced improved survival rates. Their treatment is discussed below.

Chemotherapy has been and remains the mainstay of treatment for CUP. Trials initially studied 5-fluorouracil, cyclophosphamide, and mitomycin-C and yielded poor response rates. Doxorubicin was then used with low, but better response rates of 20%. Now, taxane and platinum compounds are being used for the patients that do not fall into any of the favorable subsets, these treatments are producing response rates between 17% and 50%.^{38,39}

Treatment of Favorable Subsets

Subsets of CUP exist that require specific treatment, and subset-specific treatment has improved patient outcomes. Patients in these categories have decreased mortality; unfortunately, they only comprise 40% of all patients diagnosed with CUP.⁹ Favorable subsets include germ cell tumors presenting as a poorly differentiated carcinoma, papillary carcinoma of peritoneal cavity in

Table 3. Cancer of an Unknown Primary Site: Favorable Subsets and Recommended Treatment

Subset	Recommended Treatment
Extragenadal germ cell syndrome: poorly differentiated carcinoma with midline distribution	Platinum-based chemotherapy
Females with papillary adenocarcinoma of the peritoneal cavity	Treat as advanced ovarian cancer with taxane- and platinum-based chemotherapy after exploratory laparotomy with maximal surgical cytoreduction/debulking
Females with adenocarcinoma involving axillary lymph nodes	Adjuvant chemotherapy or hormone-based regimens and/or radiation therapy; assess estrogen receptor positivity
Squamous cell carcinoma with cervical adenopathy	Assumed head and neck cancer; treat with radiation, with or without surgery and with or without chemotherapy
Inguinal lymphadenopathy with squamous cell carcinoma	Surgery with or without radiation
Poorly differentiated neuroendocrine carcinomas	Highly sensitive to platinum-based chemotherapies
Men with blastic bone metastases and elevated prostate-specific antigen from an adenocarcinoma	Trial of antiandrogen hormonal therapy
Single small metastasis of adenocarcinoma	Local therapy with resection with or without radiation

Adapted from Pavlidis N, Briasoulis E, Hainsworth J, Greco FA. Diagnostic and therapeutic management of cancer of an unknown primary. *Eur J Cancer* 2003;39:1990–2005; and Greco FA, Hainsworth JD. Cancer of unknown primary site. In: DeVita TV, Hellman S, Rosenberg SA, editors. *Cancer: principles and practice of oncology*. 4th ed. Philadelphia: J. B. Lippincott Co.; 1997:2072–92.

women, adenocarcinoma of axillary nodes in women, squamous cell carcinoma of cervical nodes, isolated inguinal lymphadenopathy from squamous cell carcinoma, poorly differentiated neuroendocrine carcinomas, men with bone metastases and an elevated PSA, and patients with a single small metastasis. **Table 3** provides a list of favorable subsets with their appropriate treatment.

Poorly differentiated carcinoma with midline distribution (extragenadal germ cell syndrome). This subset should be treated following the guidelines of poor prognosis germ cell tumors, that is, platinum-based chemotherapy regimens. Fifty percent response rates have been shown, with 10% to 15% long-term disease-free survivors.⁴⁰ Extragenadal germ cell syndrome has the following features:

- It occurs in younger men (age < 50 years);
- Tumors are located predominantly in the midline (mediastinum);
- The symptom interval is short (< 3 months) with rapid tumor growth;
- Serum levels of β -HCG, AFP, or both are elevated; and
- There is a good response to appropriate treatment.⁹

Few patients have all the components of the syndrome. Several factors are associated with a favorable prognosis in patients with poorly differentiated carcinoma: limited number of organ sites involved, tumor location in lymph nodes (including mediastinum and retro-

peritoneum) other than the supraclavicular lymph nodes, and female sex.¹⁵

Women with papillary adenocarcinoma of the peritoneal cavity (peritoneal papillary serous carcinoma). Peritoneal papillary serous carcinoma usually indicates that the primary site is in the ovary, and patients should be managed as International Federation of Gynecology and Obstetrics stage III ovarian cancer patients and treated with taxane and platinum-based chemotherapy after exploratory laparotomy with maximal surgical cytoreduction. Complete responses average approximately 20% with a 16% long-term survival rate.⁴¹ Patients may have elevated serum levels of CA-125. Carcinomas from the gastrointestinal tract and breast can occasionally produce this clinical scenario as well.

Women with adenocarcinoma involving axillary lymph nodes. Metastatic breast cancer should be considered in these cases. Overall, the management of these patients is similar to the management of those with stage II or III breast cancer. The initial lymph node biopsy should include measurement of estrogen and progesterone receptors. For patients with mobile nodes (N1), node resection followed by simple mastectomy/radiation should be undertaken as well as hormone therapy if the tumor is estrogen receptor positive. If the patient is premenopausal, adjuvant chemotherapy should be given. For those patients with fixed nodes (N2), neoadjuvant chemotherapy (chemotherapy given before surgery) is recommended. Estrogen receptor–positive patients should receive hormone therapy. MRI has been found to

be helpful for detecting occult breast carcinoma when ultrasound and mammogram have been negative and facilitates breast conservation in select women.^{42,43} If the patient is elderly or not responding, radical radiation therapy should be the course of action.⁴⁴ An occult primary breast tumor can be identified in 40% to 70% of these patients and is usually less than 2 cm in diameter.^{45,46}

Squamous cell carcinoma involving cervical lymph nodes. Treatment should follow guidelines for locally advanced head and neck cancers. Evaluation should include an examination of the oropharynx, hypopharynx, nasopharynx, larynx, and upper esophagus by direct endoscopy with biopsy of any suspicious lesions. The most common sites of primary lesions (82%) are tonsil/tonsillar fossa and base of the tongue.⁴⁷

Locoregional therapy is the mainstay of treatment. Extensive radiation to both the ipsilateral and contralateral sides of the neck has provided better survival rates than radiation to only the side of the neck containing the cancer. It should be noted that there is increased acute and late morbidity associated with bilateral radiation.⁴⁸ Involvement of the lower cervical or supraclavicular lymph nodes should suggest a primary lung cancer, but they should be treated with the same approach as patients with higher cervical node involvement if no tumor is detected below the clavicle. If chest radiograph and head and neck examinations are normal, fiberoptic bronchoscopy should be performed. In the absence of lesions, a tonsillectomy is recommended because 25% of primary tumors are located here.^{49,50} Five-year survival rates range from 35% to 50%.⁵¹ These patients typically are middle-aged or elderly and have a history of alcohol or tobacco abuse.⁹

Isolated inguinal lymphadenopathy from squamous cell carcinoma. Recommended treatment consists of node dissection with or without local radiation. Primary tumors, if found, usually reside in the genital or anorectal areas. In one study, survival at 5 years was 27%. Among 40 patients who presented with inguinal and inguinal plus iliac disease, survival was 37.5% at 5 years. The role of chemotherapy has not been evaluated in this population.⁵²

Poorly differentiated neuroendocrine carcinomas. This type of CUP has been shown to be sensitive to platinum-based chemotherapies and paclitaxel/carboplatin-based chemotherapies and is best diagnosed by electron microscopy (neurosecretory granules). Primary lesions include carcinoid tumors, islet cell tumors (pancreas), pheochromocytomas, and small cell lung cancers. Response rates have been reported at 50% to 70%.^{53,54}

Men with blastic bone metastases and elevated PSA from an adenocarcinoma. These patients should be considered to have prostate cancer and should initially receive a trial of hormonal therapy.⁹ Even when clinical features do not suggest prostate cancer, hormonal therapy should be initiated (usually with agents such as flutamide, finasteride, or leuprolide) because of the high likelihood of a possible underlying prostate cancer.^{55,56} Empirical hormonal therapy may be reasonable for elderly men with osteoblastic bone metastases, in the absence of an elevated serum PSA or of detectable PSA in the tumor.⁵⁷

Patients with a single small metastasis of adenocarcinoma. For these patients, resection and/or radiation therapy should be considered. Common locations for the metastases to occur are in single lymph nodes in the cervical, axillary, or inguinal areas. Choice of treatment should be based on location of the metastasis. Many of these patients receive palliative benefit from treatment and can have years before any metastases appear again.^{48,49}

Treatment of Unfavorable Subsets

Patients with multiple metastases to certain sites are considered to belong to unfavorable subsets. These include metastatic adenocarcinoma to the liver and multiple metastases to the bone, brain, or lung. The type of cancer with the worst prognosis remains adenocarcinoma.^{15,57}

While therapy for patients with a CUP that lies in a favorable subset is aimed toward long-term remission, patients whose cancer falls into an unfavorable subset should receive palliative care. Chemotherapy for these groups has been shown to lengthen survival by only 1 to 2 months, although taxane/platinum-based regimens have had more success, with median survival times of 8 to 13 months and higher response rates.⁵⁸⁻⁶⁰ Because single-agent chemotherapy has been shown to have very low response rates, initial treatment should be combination chemotherapy (combinations of fluorouracil, doxorubicin, mitomycin, taxanes, and cisplatin).⁵⁶

Any patient presenting with CUP who does not fit into any of the favorable subsets should be started on a trial of empirical chemotherapy if the performance status is adequate. A 6- to 8-week trial of treatment is sufficient to determine whether the tumor is sensitive to treatment or not. If the tumor is sensitive, treatment should continue for 4 to 6 months; in patients who have no response, consideration can be given to discontinuing therapy and/or instituting palliative care. Patients in this category who are very elderly or have a poor performance status should receive symptomatic care only.

CONCLUSION

Cancers that present with the primary site unknown have natural histories and clinical presentations that are quite different from those that present with known primary sites. Although identification of treatable subsets in CUP has improved the outcome of patients, the overall prognosis remains poor. Attempting to identify patients who may respond to treatment and initiating the appropriate therapy is of paramount importance. A therapeutic trial of chemotherapy should be started in most other patients and is the only means to determine whether their tumors are responsive. As therapies, imaging, and molecular biology advance, so too should the treatment of CUP.

HP

REFERENCES

- van de Wouw AJ, Janssen-Heijnen ML, Coebergh JW, Hillen HF. Epidemiology of unknown primary tumours; incidence and population-based survival of 1285 patients in Southeast Netherlands, 1984–1992. *Eur J Cancer* 2002;38:409–13.
- Lembersky BC, Thomas LC. Metastases of unknown primary site. *Med Clin North Am* 1996;80:153–71.
- Silverberg E, Lubera J. Cancer statistics, 1987. *CA Cancer J Clin* 1987;37:2–19.
- Muir C. Cancer of unknown primary site. *Cancer* 1995;75(1 Suppl):353–6.
- Holmes FF, Fouts TL. Metastatic cancer of unknown primary site. *Cancer* 1970;26:816–20.
- Jordan WE 3rd, Shildt RA. Adenocarcinoma of unknown primary site. The Brooke Army Medical Center experience. *Cancer* 1985;55:857–60.
- Califano J, Westra WH, Koch W, et al. Unknown primary head and neck squamous cell carcinoma: molecular identification of the site of origin. *J Natl Cancer Inst* 1999;91:599–604.
- Naresh KN. Do metastatic tumours from an unknown primary reflect angiogenic incompetence of the tumour at the primary site?—a hypothesis. *Med Hypotheses* 2002;59:357–60.
- Greco FA, Hainsworth JD. Cancer of unknown primary site. In: DeVita TV, Hellman S, Rosenberg SA, editors. *Cancer, principles and practice of oncology*. 4th ed. Philadelphia: Lippincott Co.; 1997:2423–43.
- Briasoulis E, Tsokos M, Fountzilias G, et al. Bcl2 and p53 protein expression in metastatic cancer of unknown primary origin: biological and clinical implications. A Hellenic Co-operative Oncology Group study. *Anticancer Res* 1998;18:1907–14.
- Bell CW, Pathak S, Frost P. Unknown primary tumors: establishment of cell lines, identification of chromosomal abnormalities, and implications for a second type of tumor progression. *Cancer Res* 1989;49:4311–5.
- Briasoulis E, Pavlidis N. Cancer of unknown primary origin. *Oncologist* 1997;2:142–52.
- Nystrom JS, Weiner JM, Heffelfinger-Juttner J, et al. Metastatic and histologic presentations in unknown primary cancer. *Semin Oncol* 1977;4:53–8.
- Frost P, Raber MN, Abbruzzese JL. Unknown primary tumors as a unique clinical entity and biologic entity: a hypothesis. *Cancer Bull* 1989;41:139–41.
- Abbruzzese JL, Abbruzzese MC, Hess KR, et al. Unknown primary carcinoma: natural history and prognostic factors in 657 consecutive patients. *J Clin Oncol* 1994;12:1272–80.
- van de Wouw AJ, Jansen RL, Griffioen AW, Hillen HF. Clinical and immunohistochemical analysis of patients with unknown primary tumour. A search for prognostic factors in UPT. *Anticancer Res* 2004;24:297–301.
- Pavlidis N, Briasoulis E, Hainsworth J, Greco FA. Diagnostic and therapeutic management of cancer of an unknown primary. *Eur J Cancer* 2003;39:1990–2005.
- Abbruzzese JL, Abbruzzese MC, Lenzi R, et al. Analysis of a diagnostic strategy for patients with suspected tumors of unknown origin. *J Clin Oncol* 1995;13:2094–103.
- Mackey B, Ordonez NG. Pathological evaluation of neoplasms with unknown primary tumor site. *Semin Oncol* 1993;20:206–28.
- Allhoff EP, Proppe KH, Chapman CM, et al. Evaluation of prostate specific acid phosphatase and prostate specific antigen in identification of prostatic cancer. *J Urol* 1983;129:315–8.
- Horning SJ, Carrier EK, Rouse RV, et al. Lymphomas presenting as histologically unclassified neoplasms: characteristics and response to treatment. *J Clin Oncol* 1989;7:1281–7.
- Warnke RA, Gatter KC, Falini B, et al. Diagnosis of human lymphoma with monoclonal antileukocyte antibodies. *N Engl J Med* 1983;309:1275–81.
- Tot T. Cytokeratins 20 and 7 as biomarkers: usefulness in discriminating primary from metastatic adenocarcinoma. *Eur J Cancer* 2002;38:758–63.
- Casciato DA, Tabbarah HJ. Metastases of unknown origin. In: Haskell CM, editor. *Cancer treatment*. 3rd ed. Philadelphia: Saunders; 1990:798–814.
- Pavlidis N, Kalef-Ezra J, Briassoulis E, et al. Evaluation of six tumor markers in patients with carcinoma of unknown primary. *Med Pediatr Oncol* 1994;22:162–7.
- Shahanigan S, Fritsche HA. Serum tumor markers as diagnostic aids in patients with unknown primary tumors. *Cancer Bull* 1989;41:152.
- Ruddon RW, Norton SE. Use of biological markers in the diagnosis of cancers of unknown primary tumor. *Semin Oncol* 1993;20:251–60.
- Panza N, Lombardi G, De Rosa M, et al. High serum thyroglobulin levels. Diagnostic indicators in patients with metastases from unknown primary sites. *Cancer* 1987;60:2233–6.
- Nystrom S, Weiner JM, Wolf RM, et al. Identifying the primary site in metastatic cancer of unknown origin. Inadequacy of roentgenographic procedures. *JAMA* 1979;241:381–3.

30. Karsell PR, Sheedy PF 2nd, O'Connell MJ. Computed tomography in search of cancer of unknown origin. *JAMA* 1982;248:340–3.
31. Chang KJ, Katz KD, Durbin TE, et al. Endoscopic ultrasound-guided fine-needle aspiration. *Gastrointest Endosc* 1994;40:694–9.
32. Harewood GC, Wiersema MJ. Endosonography-guided fine needle aspiration biopsy in the evaluation of pancreatic masses. *Am J Gastroenterol* 2002;97:1386–91.
33. Varadarajulu S, Wallace MB. Applications of endoscopic ultrasonography in pancreatic cancer. *Cancer Control* 2004;11:15–22.
34. Orel SG, Weinstein SP, Schnall MD, et al. Breast MR imaging in patients with axillary node metastases and unknown primary malignancy. *Radiology* 1999;212:543–9.
35. Rigo P, Paulus P, Kaschten BJ, et al. Oncological applications of positron emission tomography with fluorine-18 fluorodeoxyglucose. *Eur J Nucl Med* 1996;23:1641–74.
36. Alberni JL, Belhocine T, Hustinx R, et al. Whole-body positron emission tomography using fluorodeoxyglucose in patients with metastases of unknown primary tumours (CUP syndrome). *Nucl Med Commun* 2003;24:1081–6.
37. Regelink G, Brouwer J, de Bree R, et al. Detection of unknown primary tumours and distant metastases in patients with cervical metastases: value of FDG-PET versus conventional modalities. *Eur J Nucl Med Mol Imaging* 2002;29:1024–30.
38. Jadeja J, Legha S, Burgess M, et al. Combination chemotherapy with 5-fluorouracil, adriamycin, cyclophosphamide, and cis-platinum in the treatment of adenocarcinoma of unknown primary and undifferentiated carcinomas [abstract]. *Proc Am Soc Clin Oncol* 1983;926.
39. Falkson CI, Cohen GL. Mitomycin C, epirubicin and cisplatin versus mitomycin C alone as therapy for carcinoma of unknown primary origin. *Oncology* 1998;55:116–21.
40. van der Gaast A, Verweij J, Henzen-Logmans SC, et al. Carcinoma of unknown primary: identification of a treatable subset? *Ann Oncol* 1990;1:119–22.
41. Ransom DT, Patel SR, Keeney GL, et al. Papillary serous carcinoma of the peritoneum. A review of 33 cases treated with platin-based chemotherapy. *Cancer* 1990;66:1091–4.
42. Olson JA, Morris EA, Van Zee KJ, et al. Magnetic resonance imaging facilitates breast conservation for occult breast cancer. *Ann Surg Oncol* 2000;7:411–5.
43. Morris EA, Schwartz LH, Dershaw DD, et al. MR imaging of the breast in patients with occult primary breast carcinoma. *Radiology* 1997;205:437–40.
44. Jackson B, Scott-Conner C, Moulder J. Axillary metastasis from occult breast carcinoma: diagnosis and management. *Am Surg* 1995;61:431–4.
45. Ashikari R, Rosen PP, Urban JA, Senoo T. Breast cancer presenting as an axillary mass. *Ann Surg* 1976;183:415–7.
46. Patel J, Nemoto T, Rosner D, et al. Axillary lymph node metastasis from an occult breast cancer. *Cancer* 1981;47:2923–7.
47. Mendenhall WM, Mancuso AA, Parsons JT, et al. Diagnostic evaluation of squamous cell carcinoma metastatic to cervical lymph nodes from an unknown head and neck primary site. *Head Neck* 1998;20:739–44.
48. Nieder C, Ang KK. Cervical lymph node metastases from occult squamous cell carcinoma. *Curr Treat Options Oncol* 2002;3:33–40.
49. Nieder C, Gregoire V, Ang KK. Cervical lymph node metastases from occult squamous cell carcinoma: cut down a tree to get apple? *Int J Radiat Oncol Biol Phys* 2001;50:727–33.
50. McQuone SJ, Eisele DW, Lee DJ, et al. Occult tonsillar carcinoma in the unknown primary. *Laryngoscope* 1998;108(11 Pt 1):1605–10.
51. Grau C, Johansen LV, Jakobsen J, et al. Cervical lymph node metastases from unknown primary tumors. Results from a national survey by the Danish Society for Head and Neck Oncology. *Radiother Oncol* 2000;55:121–9.
52. Guarischi A, Keane TJ, Elhakim T. Metastatic inguinal nodes from an unknown primary neoplasm. A review of 56 cases. *Cancer* 1987;59:572–7.
53. Hainsworth JD, Johnson DH, Greco FA. Poorly differentiated neuroendocrine carcinoma of unknown primary site. A newly recognized clinicopathologic entity. *Ann Intern Med* 1988;109:364–71.
54. Moertel CG, Kvols LK, O'Connell MJ, Rubin J. Treatment of neuroendocrine carcinomas with combined etoposide and cisplatin. Evidence of major therapeutic activity in the anaplastic variants of these neoplasms. *Cancer* 1991;68:227–32.
55. Gentile PS, Carloss HW, Huang TY, et al. Disseminated prostate carcinoma simulating primary lung cancer. Indications for immunodiagnostic studies. *Cancer* 1988;62:711–5.
56. Tell DT, Khoury JM, Taylor HG, Veasey SP. Atypical metastasis from prostate cancer. Clinical utility of the immunoperoxidase technique for prostate-specific antigen. *JAMA* 1985;253:3574–5.
57. Hainsworth JD, Greco FA. Treatment of patients with cancer of an unknown primary site. *N Engl J Med* 1993;329:257–63.
58. Greco FA, Erland JB, Morrissey LH, et al. Carcinoma of unknown primary site: phase II trials with docetaxel plus cisplatin or carboplatin. *Ann Oncol* 2000;11:211–5.
59. Greco FA, Burris HA 3rd, Litchy S, et al. Gemcitabine, carboplatin, and paclitaxel for patients with carcinoma of unknown primary site: a Minnie Pearl Cancer Research Network study. *J Clin Oncol* 2002;20:1651–6.
60. Briasoulis E, Kalofonos H, Bafaloukos D, et al. Carboplatin plus paclitaxel in unknown primary carcinoma: a phase II Hellenic Cooperative Oncology Group Study. *J Clin Oncol* 2000;18:3101–7.